

# Actinomycosis: A Cause of Chronic Conjunctivitis Often Overlooked

Rita Aggarwal<sup>1</sup>, Yamini Sahu<sup>1</sup>, Ritika Aggarwal<sup>1</sup>, Pooja Gupta<sup>1</sup>, Rajni Gaiind<sup>3</sup>, Dabet Rynga<sup>2</sup>, Anupam Kumar Anveshi<sup>2</sup>

<sup>1</sup>Department of Ophthalmology, Vardhman Mahavir Medical College and Safdarjung Hospital, New Delhi, India

<sup>2</sup>Department of Microbiology, Vardhman Mahavir Medical College and Safdarjung Hospital, New Delhi, India

## Summary

Chronic conjunctivitis is a common ocular disease routinely responding to antibiotic therapy. In patients presenting with chronic conjunctivitis who do not respond to treatment, Actinomycosis should be kept in mind. We are reporting two cases who presented to us with chronic conjunctivitis that did not respond to various topical antibiotic drops for a long time. One of them had associated canaliculitis while the other presented with small concretions in lower fornix. Both of them were positive for Actinomycosis and responded to topical cefazoline eye drops.

This highlights the importance of Actinomyces infection in patients of chronic conjunctivitis not responding to routine antibiotic therapy.

Delhi J Ophthalmol 2019;29;89-91; Doi <http://dx.doi.org/10.7869/djo.431>

**Keywords:** Actinomycosis, Chronicconjunctivitis, Canaliculitis, Concretions

Chronic canaliculitis is an inflammation of the lacrimal canaliculus. Inflammation of lacrimal canaliculus can occur secondary to dacryocystitis, but the most common cause is infection.<sup>1</sup> Bacteria, fungi and viruses can cause infection. The most common presenting symptom of canaliculitis is chronic conjunctivitis. Actinomyces species is classically cited as the most common organism causing canaliculitis.<sup>2-4</sup> Concretions in the lower palpebral conjunctiva/fornix with conjunctivitis can also be the presenting symptom of Actinomyces infection.<sup>5</sup> We hereby report two cases of chronic conjunctivitis, one with canaliculitis and the other with palpebral concretions, both were positive for Actinomyces and responded to topical 5% cefazoline eyedrops.

## Case Report - 1

A 50 year old male presented to us with complaints of chronic irritation, watering and occasional redness of the right eye since past 8 months. He was prescribed various topical antibiotic drops but he did not respond to any of them. On examination, his vision was 6/6 in both eyes. Examination of the right eye revealed a tender swelling in the medial one third of the right lower lid with congestion of adjacent lower palpebral conjunctiva and pouting lower punctum (Figure

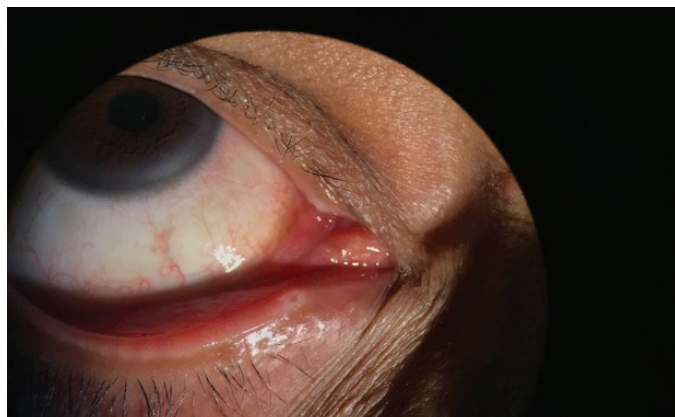

Figure 1: Right eye lacrimal canalculitis with punctal pouting and inflamed canalculis

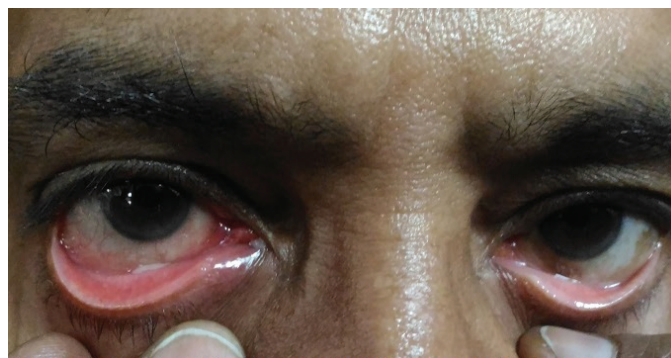

Figure 2: The right eye showing purulent discharge in the lower fornix with inflamed punctum

1 and 2). Mucoïd discharge could be expressed by pressing over the swelling. No swelling or tenderness was noted in the lacrimal sac area. The left eye was asymptomatic. Syringing was patent in both the eyes. Rest of the anterior segment examination and fundus of both the eyes were normal.

Canaliculotomy of right lower canaliculus was done under local anaesthesia with all aseptic precautions. Purulent material along with concretions were expressed from the canaliculus. The discharge was collected and sent for microbiological examination. All direct microscopic examinations were suggestive of Actinomyces species appearing as long gram positive, nonsporing bacilli which on anaerobic culture yielded flat, irregular, grey, nonhaemolytic colonies. The patient was prescribed topical cefazoline eye drops for two weeks. On follow up, symptoms had improved and there was no congestion in the right eye.

## Case Report - 2

A 25 year old female presented to the ophthalmology OPD with chronic redness and irritation of both the eyes for past 2 years. On examination, congestion of lower palpebral conjunctiva with small concretions was seen in both the eyes (Figure 3). Rest of the anterior segment examination was normal. The patient was on various topical antibiotics and anti-inflammatory eyedrops but did not respond to

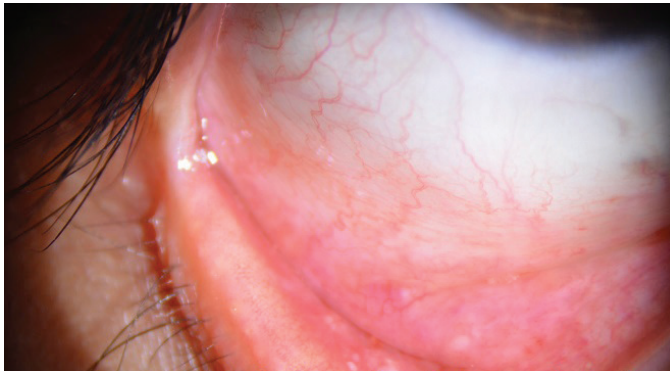


Figure 3: Concretions in lower palpebral conjunctiva

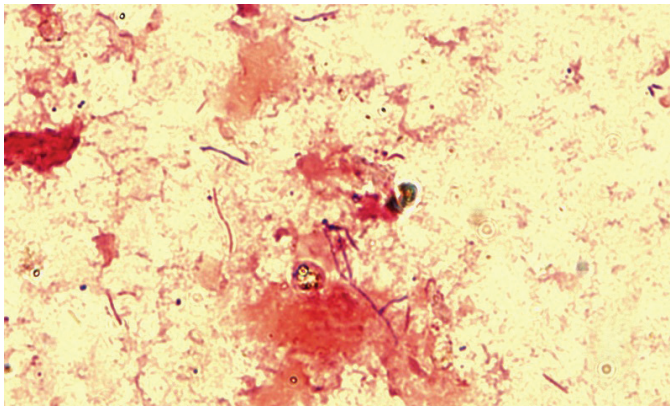


Figure 4: Gram stained smear showing gram positive Actinomyces

any of them. The scraping of the concretions were sent for microbiological examination. It was positive for Actinomyces (Figure 4). The patient was started on topical cefazoline eyedrops and she responded to treatment.

### Discussion

This case report highlights the importance of considering the possibility of Actinomyces infection in a patient of chronic ocular irritation and conjunctivitis not responding to routine antibiotic therapy. Several cases of canaliculitis are reported in the literature with an average delay in diagnosis of 3 years.<sup>6</sup> Lacrimal canaliculitis is commonly misdiagnosed as mucocoeles, dacryocystitis, blepharitis or meibomian cysts<sup>7</sup> and missed by even experienced ophthalmologists. Lacrimal canaliculitis is generally a unilateral condition.<sup>8</sup> It results from infection of canaliculus, most commonly by Actinomyces species, an anaerobic gram positive bacillus. It usually presents as chronic watering, redness and discharge from the eye, conjunctivitis, eyelid matting and punctum pouting. Actinomyces infection is characterized by production of yellow concretions known as sulphur granules. Actinomyces is a slow growing anaerobe, so the culture can be difficult and microbiological identification may be complicated by superadded infections.

A case of chronic conjunctivitis not responding to topical antibiotics along with signs and symptoms should arouse a high level of suspicion of lacrimal canaliculitis due to Actinomyces infection. Failure of resolution with antibiotic therapy occurs from poor penetrance of antibiotics in concretions and thick secretions. This causes recurrence until definitive treatment with canaliculotomy and curettage is performed. As an adjunctive therapy, topical or oral penicillin or ampicillin can be used based on antibiotic sensitivity.

Although canaliculitis is the usual presentation of Actinomyces in the eye, the presence of concretions in the palpebral conjunctiva<sup>5</sup> can also be a presenting feature of the infection. In routine practice, these concretions are scraped only to recur again and cause chronic distress to the patient. This case report highlights the importance of strong suspicion of Actinomyces in patients of palpebral concretions. Proper diagnosis and treatment of the condition can help cure the chronic distressing symptom.

### Conclusion

This case report shows the importance of considering Actinomyces infection in any patient of chronic conjunctivitis. The difficulty of obtaining a positive anaerobic culture of Actinomyces also leads to improper and delayed management of this disease. Greater vigilance regarding this condition may prevent misdiagnosis and help in early intervention which would help in complete eradication of infection and prevent recurrence.

### References

1. Baldursdottir E, Sigurdsson H, Jonasson L, Gottfredsson M. Actinomycotic canaliculitis: resolution following surgery and short topical antibiotic treatment. *Acta Ophthalmol* 2010; 88:367-370.
2. Hussain I, Bonshek RE, Loudon K, Armstrong M, Tullo AB. Canalicular infection caused by Actinomyces. *Eye (Lond)* 1993; 7:542-4.
3. Fulmer NL, Neal JG, Bussard GM, Edlich RF. Lacrimal canaliculitis. *Am J Emerg Med* 1999; 17:385-6.
4. Sullivan TJ, Hakin KN, Sathananthan N, Rose GE, Moseley IF. Chronic canaliculitis. *Aust NZ J Ophthalmol* 1993; 21:273-4.
5. Mehrotra N, Baidya A, Brijwal M, Aggarwal R, Chaudhry R. Actinomycosis of eye: Forgotten but not uncommon. *Anaerobe*. 2015; 35(Pt B):1-2.
6. Briscoe D, Edelstein E, Zacharopoulos I, Keness Y, Kilman A, Zur F, Assia EI. Actinomyces canaliculitis: diagnosis of a masquerading disease. *Graefes Arch Clin Exp Ophthalmol* 2004; 42:682-6.
7. Anand S, Hollingworth K, Kumar V, Sandramouli S. Canaliculitis: this incidence of long-term epiphora following canaliculotomy. *Orbit* 2004; 23:19-26.
8. Kaliki S, Ali MJ, Honavar SG, Chandrasekhar G, Naik MN. Primary canaliculitis: clinical features, microbiological profile, and management outcome. *Ophthalm Plast Reconstr Surg* 2012; 28:355-60.

**Cite This Article as:** Aggarwal R, Sahu Y, Aggarwal R, Gupta P, Gaiind R, Rynga D, Anveshi AK. Actinomycosis: A Cause of Chronic Conjunctivitis Often Overlooked.

**Acknowledgments:** Nil

**Conflict of interest:** None declared

**Source of Funding:** None

**Date of Submission:** 17 October 2018


**Date of Acceptance:** 13 November 2018

### Address for correspondence

**Rita Aggarwal** ms

Department of Ophthalmology  
Vardhman Mahavir Medical College and  
Safdarjung Hospital, New Delhi-110029,  
India

Email id: rita.ophtal@gmail.com



Quick Response Code