

Sentinel Lymph Node Biopsy in Eyelid Malignancy – A Brief Update

Neelam Pushker¹, Gautam Lokdarshi²

¹Dr. Rajendra Prasad Centre for Ophthalmic Sciences, All India Institute of Medical Sciences, New Delhi, India

²All India Institute of Medical Sciences, Patna, Bihar, India

Abstract

Sentinel lymph node biopsy detects metastasis in the initial stages before the regional spread becomes clinically detectable and aids in the staging of the tumor. It helps to promptly manage the patient thereby improving the overall survival and quality of life. Further, it prevents unnecessary radical lymph node dissection and its associated morbidity in advanced malignancy with negative regional spread. Usefulness of sentinel lymph node biopsy in the periocular region is still evolving.

Delhi J Ophthalmol 2020;30;11-15; Doi <http://dx.doi.org/10.7869/djo.538>

Keywords: Sentinel lymph node, eyelid, periocular, malignancy, staging.

Sentinel lymph node biopsy (SLNB) helps in determining microscopic regional lymph node metastasis. This investigative modality has been widely applied for cutaneous melanomas and breast carcinomas. The common malignancies of eyelid in India are sebaceous cell carcinoma, squamous cell carcinoma, basal cell carcinoma and melanoma (Caucasians have mostly melanomas and BCC). Except basal cell carcinoma, there can be regional lymphatic spread in rest of the eyelid malignancies, most commonly seen in melanomas ~ 30%.¹

Definition: Sentinel lymph node(s) is the first draining lymph node of a lymph node basin which can be more than one in number. **Lymph node basin** is a group of lymph nodes into which lymph channels drain from a particular region of the body.

Lymphatic drainage of eyelids and periocular area:

The eyelids, lacrimal drainage system and the conjunctiva have a rich network of lymphatic channels. Traditional descriptions of lymphatic eyelid drainage state that if we draw an imaginary line as shown in Figure 1, majority of the upper eyelid and a small part of lower eyelid should drain to the preauricular nodes and parotid lymph basins, while the medial portions of the eyelids and majority of the lower

eyelids should drain to the submandibular nodes and other neck nodes. With the advent of newer methods for the better understanding of the lymphatic drainage pattern and studies done on SLNB, it has been found that irrespective of the site, most of the lymphatic drainage of eyelids and conjunctiva is into the preauricular and parotid group of lymph nodes.²⁻⁴

Usefulness of Sentinel lymph node(s) biopsy:

In eyelid malignancy, a regional lymph node is often the first site of malignant tumor spread before dissemination to more distant sites. All such patients should undergo regional and systemic metastatic work up as a baseline investigation. Evaluation of the status of regional lymph nodes should be done clinically by palpation as well as on ultrasound/Computed Tomography/Magnetic Resonance Imaging, simpler and quicker and cheaper would be ultrasound. The preauricular, parotid, submandibular and other neck lymph nodes should be evaluated. It is important to stage the eyelid tumor as per 8th AJCC tumor-node-metastasis (TNM) staging system for better treatment and prognostication.⁵ Earlier, radical neck dissection was routinely performed in patients with advance malignancy which led to unnecessary morbidity related to the surgery.

SLNB is done in patients with no clinical or on imaging evidence of lymph node spread. The main concept behind sentinel lymph node(s) biopsy is that it is assumed that there is orderly and predictable draining network of lymph channels of a particular area. Further, the sentinel lymph node being the first lymph node would harbor the malignant cells in the initial stages of metastasis. The biopsy of SLN if found positive, i.e., before the spread becomes clinically detectable, will help to promptly manage the patient thereby improving the overall survival and quality of life. The treatment of positive lymph node is radical lymph node dissection followed by radiotherapy to the involved lymph basin. Subclinical or detection at the stage of micro-metastasis would improve overall survival by timely intervention. Further, it prevents unnecessary radical lymph node dissection and its associated morbidity in patients with negative SLNB.

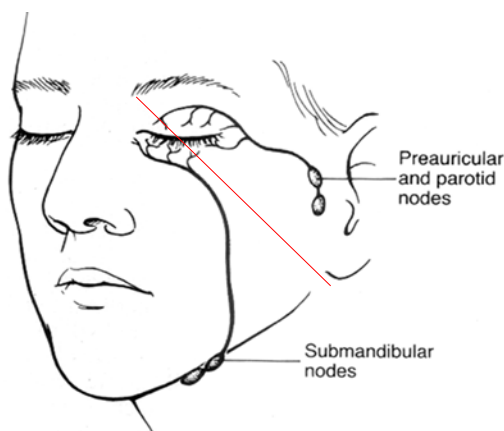


Figure 1: Lymphatic drainage of the eyelids

Indications of SLNB

Any lymph node greater than 1 cm in maximum dimension, and/ or presence of matted nodes strongly suggests upfront biopsy of the involved node(s). Suspicious or metastatic nodes may have thickening or eccentric lobulation of the hypoechoic cortical rim, compression or displacement of the fatty hyperechoic hilum, or complete replacement of the hilar fat by hypoechoic tissue on ultrasonography.⁶ SLNB is indicated in patients where the lymph nodes are neither clinically palpable nor suspicious on imaging i.e., at the subclinical stage. Most of the published work on role of SLNB in eyelid malignancy have been on melanomas, mainly from a single center (University of Texas MD Anderson Cancer Center). The researchers have made the following recommendations for SLNB for ocular adnexal melanoma: for eyelid skin melanoma, Breslow thickness greater than 1 mm, Clark's level IV or higher or indeterminable thickness, more than 1 mitotic figures per high power field and/or those with histologic ulceration; for conjunctival melanoma, Breslow thickness greater than 1mm, indeterminable thickness or large areas of diffuse conjunctival pigmentation, histologic ulceration and non-limbal location.^{3,7} So it's preferable to excise the melanoma completely before performing SLNB to determine the histological criteria for SLNB.⁸ Indications for SLNB in patients with sebaceous cell carcinoma and squamous cell carcinoma have not been studied widely.^{4,9,10} SLNB has been recommended for patients with sebaceous cell carcinoma tumor at stage > 2b (as per the 7th edition of AJCC)and tumor size more than 10 mm in diameter.⁹ In patients with squamous cell carcinoma, SLNB has been indicated in tumors that are > 2 cm in diameter, recurrent or have perineural invasion.¹⁰

Methods of SLN detection:

Depending on the nature of the tumor, SLNB can be performed before the excision of the primary tumor or even after excising the tumor. There are two main methods for detection of sentinel lymph node(s).

1. Blue Dye Technique – The vital dye used is isosulfan blue or methylene blue. The former is preferred because of lesser allergic reaction. The dye is injected perilesional, at 3 to 4 spots. It is injected intradermally for cutaneous eyelid lesions or subconjunctivally for conjunctival lesions. The dye travels down to the lymph nodes in few minutes. The incision is made and blue lymph nodes are removed. The blue lymphatic channels are identified, which are then followed to locate the stained lymph node(s) (Figure 2). The reported side effects are bluish discoloration of injected area and urine which may last for 24-48 hours and allergic reaction or rarely anaphylaxis. Use of only this technique for sentinel lymph node biopsy is associated with lower SLN identification.¹¹
2. Radiotracer Technique–The dye used is radioactive technetium 99 (99mTc-sulfur colloid, t1/2 6 hours). It is injected peri-lesionally (intradermal/ subconjunctival, depending on the location of the tumor). Few minutes after the injection, radioactive (hot) SLN(s) can be detected by hybrid SPECT/CT (Figure 3) or lymphoscintigraphy,

preoperatively and/or by hand-held gamma probe attached to a portable scintillation counter machine to measure the radioactivity counts, intra-operatively. These two methods complement each other, so both can be planned on the day of surgery. SPECT/CT helps in exact localization of hot lymph node, in relation to adjacent anatomic structures, because the machine has dual scanner i.e. CT and SPECT. Therefore it aids in planning incision and intraoperative identification of SLN(s). The use of gamma probe in operation theatre helps in detection of hot nodes, both in-vivo and ex-vivo (Figure 4). A small incision is given directly over the area with highest radioactivity. All lymph nodes with counts greater than 10% of the excised ex-vivo hottest node counts are taken out. On an average, 2-3 lymph nodes are removed and sent for histopathology.^{3,4} The problems associated with radiotracer method are licensing issues, high cost of set-up and risk of radiation exposure for both patients and medical staff.

3. Dual-dye Technique – Dual-dye technique is a combination of radiotracer and blue dye techniques. It is the recommended technique for the preoperative localization and intraoperative visualization of SLN(s). Studies have shown 100% identification rates of SLN with dual-dye technique.^{3,4}
4. Other techniques – Because of issues related to usage of radioactive isotope, cost of the procedure and other logistic issues with the radiotracer technique, alternative methods to localize the SLN have been studied in patients with other carcinomas. Use of superparamagnetic iron oxide (SPIO), fluorescence techniques using indocyanine green (ICG) or fluorescein dye, computed tomography lymphography, and contrast-enhanced ultrasound scan (CEUS) using sulphur hexafluoride microbubbles for the localization of SLN, have shown variable SLN detection rates.¹²⁻¹⁴

Studies on SLNB in eyelid and conjunctival malignancies:

SLNB is a part of treatment plan for staging of cancers in the region of breast, skin melanoma, prostate etc. The reports on usefulness of SLNB in eyelid malignancy are from limited centers in the world and are mostly on melanomas. Most of the studies are from The University of Texas MD Anderson Cancer Center. Pfeiffer et al have published the largest series of 51 patients in 2017, which was a compilation of all the previous published cases with ocular adnexal melanoma who underwent SLNB from 2008-2015. The study comprised of 31 patients of conjunctival and 20 of eyelid melanomas. The median age of patients was 62 years (range, 24-83). They used radiotracer technique for identification of SLNs; preoperatively lymphoscintigraphy and intraoperative gamma probe. The median numbers of SLNs biopsied were 2 (range, 1-5). The nodal basins of SLNs were intra-parotid (27 patients) and level II neck nodes (14 patients). Ten patients (20%) had positive SLN: 6 with eyelid melanoma and 4 with conjunctival melanoma. On comparing the features of positive versus negative SLNB patients, it was found that patients with positive SLNB had significantly greater median tumor thickness (3.5mm versus 2.2mm,

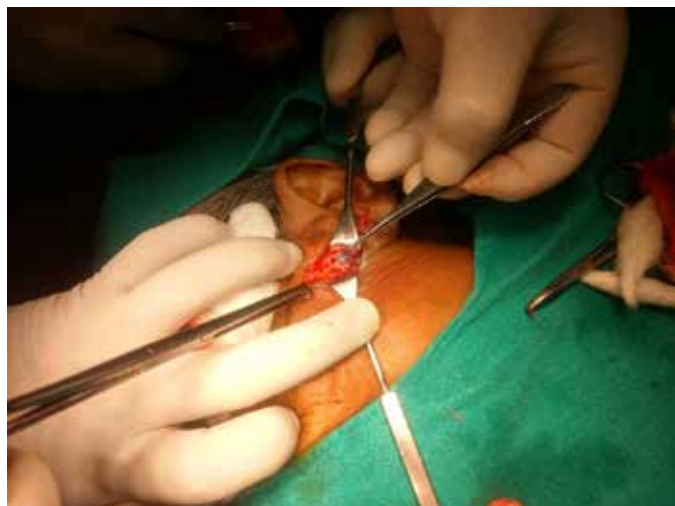

Figure 2: Blue stained SLN in preauricular region

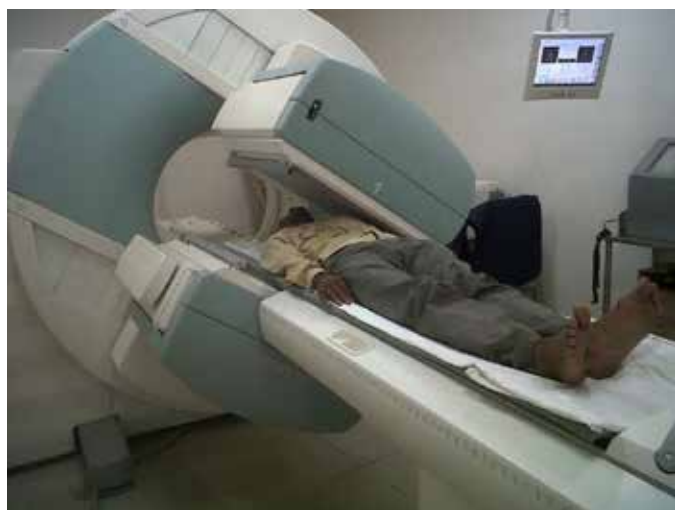

Figure 3: SPECT/CT

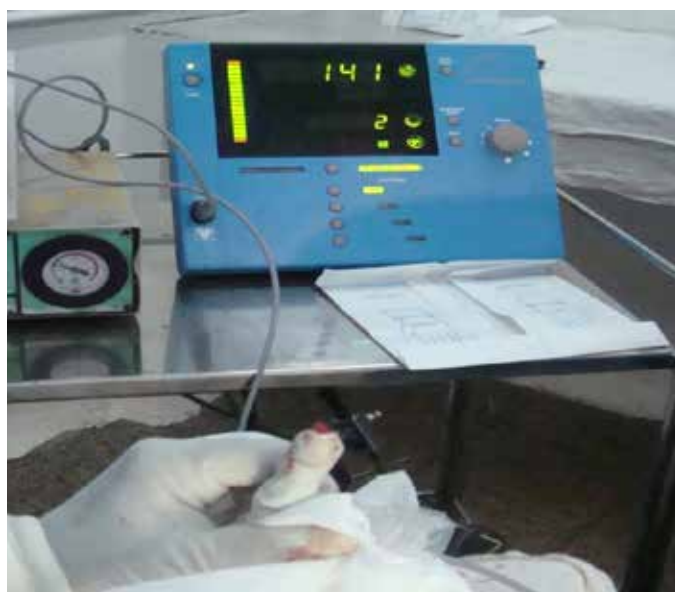

Figure 4: Gamma counter displaying radioactive counts from SLN (ex-vivo) placed on the Gamma probe

$p = 0.04$), greater median number of mitotic figures and greater incidence of ulceration. There were 3 false negative events. Three patients had temporary marginal mandibular weakness which resolved spontaneously. The median follow up time after SLNB was 6 months (range, 4 – 170 months). The 5-year survival rate after diagnosis of melanoma was 79%. So authors concluded that SLNB is safe and identifies nodal micrometastasis in approximately 20% cases.³

In a retrospective study on use of indocyanine green dye in combination with radiotracer technique in 5 patients with periocular melanoma (4 conjunctival, 1 eyelid), authors reported that indocyanine green dye aided in visualization of SLN in all the patients. None of the patients had positive SNLs. No complications were reported because of the indocyanine green dye.¹⁴

Studies published from Dr. Rajendra Prasad Centre for Ophthalmic Sciences:

The study was started in January 2010 at Dr. R. P. Centre in collaboration with Department of Surgical Disciplines, Nuclear Medicine and Pathology, All India Institute of Medical Sciences, New Delhi. Two studies have been published on SLNB in eyelid malignancy from our centre, which is the only work published from India.^{4,15} Patients with biopsy proven malignant eyelid tumor involving more than 1/3rd of the eyelid with/without orbital involvement were enrolled. SLN biopsy was performed using dual-dye technique (a combination of radiotracer and vital blue dye) after performing preoperative localization of SLN by SPECT/CT (Single photon emission computed tomography/computed tomography). SPECT/CT was done in the department of Nuclear Medicine. The SLNB procedure was done in the department of surgery by the surgeon with expertise in performing SLNB using dual dye technique. Preoperative localization of SLN was performed using SPECT/CT after giving perilesional injection (intra-dermal/subconjunctival, depending on the location of the tumor) of ^{99m}Tc-sulfur colloid radiotracer. Intra-operatively, the hot node was detected with the help of gamma probe. The area of highest radioactivity count as compared to the background (opposite shoulder) was marked on the skin. Isosulfan blue dye 1% (1 ml) was then injected, perilesionally (intra-dermal/subconjunctival). A curvilinear skin incision was made after 5 minutes, directly over the area of highest radioactive count. Any lymph node that was blue, radioactive or both was considered SLN and removed. Including the first published data, we studied a total of 37 patients with eyelid malignancy (squamous cell carcinoma, 13; sebaceous cell carcinoma, 17; melanoma, 7). SPECT-CT could localize the SLN in 27 of the 30 patients (90%). Using dual-dye technique, SLN(s) could be successfully identified hot node in 32 of 34 patients (94% detection rate). The reasons for inability to identify the SLN in 2 patients were that one patient had previous surgery which could have led to the transaction of lymphatic channels, hence not allowed the dye to reach the lymph nodes; in other patient, there was no history of previous surgery and the reason of failure could have been a faulty injection technique. The commonest site of SLN was preauricular (84%) followed by submandibular (16%).

Average number of SLN(s) harvested per patient was 2 (range 0-4). SLN identification rates for dual-dye, radiotracer, and blue dye techniques were 94% (32/34 patients), 83% (29/35 patients), and 84% (31/37 patients), respectively. Out of 37 patients, 2 cases had positive SLN, 1 each of sebaceous cell carcinoma and squamous cell carcinoma. Both the patients had advanced disease with orbital extension for which exenteration was done. One patient of conjunctival melanoma had false negative SLN (1/37 patients; 2.70%) report who developed cervical lymph node metastasis at 1 month follow-up. On review of the pathology slides, singly lined melanoma cells were found which was missed. The patient died of systemic metastasis at 16 months follow up. Another death occurred in a patient with conjunctival melanoma who died at 6 months follow up because of systemic metastasis. On review of histopathology slides of the latter patient no micrometastasis in SLN was detected. Thus in our study, death rate as well as the systemic metastasis rate in conjunctival melanoma was 28.57% (2/7 patients) over 2 years follow up. This figure is similar to that has been reported in literature.^{2,6} The two SLN positive patients (2/37 patients; 5.40%) were alive and free of disease till their last follow up (19.5 months, 51 months). Both the patients underwent radical lymph node dissection followed by radiotherapy and are free of disease till their last follow-up (19.5 months, 51 months). Over median follow up duration of 28 months (range, 2-55 months) no local or regional recurrence was detected except in the one patient with false negative lymph node. All patients had bluish discoloration of skin and urine for first 24 – 48 hrs, ipsilateral facial edema which subsided in 4-5 days, and 1 patient in whom parotidectomy was also done had dryness of mouth for 3 – 4 weeks. We concluded that SLNB accurately predicts regional nodal status in eyelid malignancy and should be considered in patients with clinically advance tumor.³

Conclusion

Regional lymph nodes work-up, clinically and on imaging should be done at regular intervals in patients with eyelid and conjunctival malignancies. SLNB is a feasible and safe procedure with positive and false-negative rates similar to the other sites. Usefulness of SLNB in the periocular region is still evolving. It aids in staging and reduces surgical morbidity related to unnecessary radical lymph node dissections in advanced malignancies. It is a part of management protocol in some institutions especially for melanomas. Further, multicenter, large sample size studies are needed to identify the indications of SLNB in patients with eyelid and conjunctival malignancies. The main limitation seems that it requires a multidisciplinary approach and expertise of oncology surgeon in the field of SLNB. Further, multi-institutional controlled trials using uniform techniques are needed to validate the published literature on periocular malignancies.

References

1. Esmaeli B. Melanocytic lesions of the eyelid and ocular adnexa. Chapter 254 In: Albert & Jakobiec's Principles and Practice of Ophthalmology. Albert DM, Miller JW (Eds.), Elsevier Inc. 2008, 3367-3378.
2. Nijhawan N, Marriott C, Harvey JT. Lymphatic drainage patterns of the human eyelid: assessed by lymphoscintigraphy. *Ophthalmic Plast Reconstr Surg*, 2010; 26(4):281-5.
3. Pfeiffer ML, Ozgur OK, Myers JN, Peng A, Ning J, Zafereo ME, Thakar S, Thuro B, Prieto VG, Ross MI, Esmaeli B. Sentinel lymph node biopsy for ocular adnexal melanoma. *Acta Ophthalmol*, 2017; 95(4):e323-e328.
4. Lokdarshi G, Vuthaluru S, Pushker N, Kumar R, Kashyap S, Mathur S. Sentinel Lymph Node Biopsy in Malignant Eyelid Tumor: Hybrid Single Photon Emission Computed Tomography/Computed Tomography and Dual Dye Technique. *Am J Ophthalmol*, 2016; 162:199-200.
5. Amin M, Edge S, Greene F, Esmaeli B, Dutton J, Graue G. Chapter 64 - eyelid carcinoma. In: Amin M, Edge S, Greene F, eds. *AJCC cancer staging manual*. 8 edn. Switzerland: Springer International Publishing, 2017; 779-85
6. Benito MA, Vahamonde EF, et al. Pretreatment axillary ultrasonography and core biopsy in patients with suspected breast cancer: Diagnostic accuracy and impact on management. *Eur J Radiol*, 2011; 79:64-72.
7. Tuomaala S, Kivelä T. Metastatic pattern and survival in disseminated conjunctiva melanoma: implications for sentinel lymph node biopsy. *Ophthalmology*, 2004; 111(4):816-21.
8. Mendoza PR, Grossniklaus HE. Sentinel lymph node biopsy for eyelid and conjunctival tumors: what is the evidence? *Int Ophthalmol Clin*, 2015 Winter; 55(1):123-36.
9. Esmaeli B, Nasser QJ, Cruz H, Fellman M, Warneke CL, Ivan D. American Joint Committee on Cancer T category for eyelid sebaceous carcinoma correlates with nodal metastasis and survival. *Ophthalmology*, 2012; 119(5):1078-82.
10. Faustina M, Diba R, Ahmadi MA, Esmaeli B. Patterns of regional and distant metastasis in patients with eyelid and periocular squamous cell carcinoma. *Ophthalmology*, 2004; 111(10):1930-2.
11. Ho VH, Ross MI, Prieto VG, Khaleeq A, Kim S, Esmaeli B. Sentinel lymph node biopsy for sebaceous cell carcinoma and melanoma of the ocular adnexa. *Arch Otolaryngol Head Neck Surg*, 2007; 133(8):820-6.
12. Dellaportas D, Koureas A, Contis J, Lykoudis PM, Vraika I, Psychogios D, Kondi-Pafiti A, Voros DK. Contrast-Enhanced Color Doppler Ultrasonography for Preoperative Evaluation of Sentinel Lymph Node in Breast Cancer Patients. *Breast Care (Basel)*, 2015; 10(5):331-5.
13. Winter A, Kowald T, Paulo TS, Goos P, Engels S, Gerullis H, Schiffmann J, Chavan A, Wawroschek F. Magnetic resonance sentinel lymph node imaging and magnetometer-guided intraoperative detection in prostate cancer using superparamagnetic iron oxide nanoparticles. *Int J Nanomedicine*, 2018; 13:6689-6698.
14. Rubinstein TJ, Perry JD, Korn JM, Costin BR, Gastman BR, Singh AD. Indocyanine green-guided sentinel lymph node biopsy for periocular tumors. *Ophthalmic Plast Reconstr Surg*, 2014; 30(4):301-4.
15. Vuthaluru S, Pushker N, Lokdarshi G, Kumar R, Bajaj MS, Kashyap S, Mathur S, Chawla B, Khurana S, Ghose S. Sentinel lymph node biopsy in malignant eyelid tumor: hybrid single photon emission computed tomography/computed tomography and dual dye technique. *Am J Ophthalmol*, 2013; 156(1):43-49.

Cite This Article as: Pushker N, Lokdarshi G. Sentinel Lymph Node Biopsy in Eyelid Malignancy – A brief Update.

Acknowledgments: Nil

Conflict of interest: None declared

Source of Funding: None

Date of Submission: 31 October 2019

Date of Acceptance: 31 January 2020

Address for correspondence

Neelam Pushker MD

Oculoplastic, Pediatric Ophthalmology & Oncology Services,
Dr. Rajendra Prasad Centre for Ophthalmic Sciences, All India Institute of Medical Sciences, New Delhi –110 029, India
Email id: pushkern@hotmail.com



Quick Response Code