

# Patterns of Ocular Trauma Presenting to the Tertiary Eye Care Centre in the Islands of Andaman and Nicobar

Sujit Das<sup>1</sup>, Manika Rana<sup>2</sup>

<sup>1</sup>Department of Ophthalmology, JNU Medical College & Research Centre, Jaipur, Rajasthan, India

<sup>2</sup>ANIIMS, Port Blair, Andaman & Nicobar Islands, India

**Objective:** The purpose of this study is to identify the patterns of ocular trauma, determine the groups at risk, types of injuries, visual and post traumatic anatomical outcomes in patients presenting to our hospital – ANIIMS, Port Blair, Andaman & Nicobar Islands

**Method:** It is a prospective hospital based observational study done over a period of two years on ocular trauma cases presenting to the emergency or referred to the ophthalmology department from June 2016 to June 2018. A questionnaire was made and data was collected on the patient's age, gender, affected eye, aetiology, location of trauma, visual acuity, intra-ocular pressure (IOP) and subsequent gonioscopy, hospital admission, maximum stay in the hospital and primary and secondary surgical intervention done.

## Abstract

**Results:** The study included 77 eyes of 70 patients. Males were affected in 84% of cases. The highest incidence of trauma was seen in the age group of 21-30 years (34%). Children below 10 years were found in 14% cases. Blunt ocular trauma was found in 38 patients (25.7%) whereas penetrating injuries were found in six eyes (8.6%). Road traffic accident was found as the most common cause of trauma (25.7%). Hospitalization was done in 30 patients (42.85%) and the maximum stay in the hospital was three days. Primary surgical interventions were required in 25 patients (35.71%).

**Conclusions:** Road traffic accident is one of the major cases related to blunt ocular trauma and early intervention can prevent ocular morbidity. Children are at a higher risk for accidental ocular injuries especially with sharp objects. Safety is the key in preventing ocular injuries and thereby can reduce the burden on the individual as well as on the socioeconomic and health resources of any nation.

Delhi J Ophthalmol 2020;30;20-26; Doi <http://dx.doi.org/10.7869/djo.540>

**Keywords:** Blunt trauma, eye injuries, ocular trauma, penetrating eye injuries, hyphema.

## Introduction

The Andaman and Nicobar Islands, one of the seven union territories of India, are a group of islands at the juncture of the Bay of Bengal and Andaman Sea. The total land area of these islands is approximately 8,249 km<sup>2</sup> (3,185 sq mi). As of 2011 Census of India, the population of the Union Territory of Andaman and Nicobar Islands was 380,581. The only emergency connection to mainland is via aeroplane. So considering the geographical location it is very difficult in managing the emergencies sometimes, especially when cases has to be managed by senior resident joining just after passing post graduate degree.

It is a well known fact that ocular injuries are the most common cause of monocular blindness. Over 2.4 million eye injuries occur each year and 90% of all eye injuries are preventable. Early detection and management holds the key to trauma management and prevention of further complications.<sup>1</sup> The World Health Organization (WHO) estimated that 55 million eye injuries occur yearly, of which 750000 people require hospitalization. Ocular injuries may also be associated with other injuries including facial fractures, in which severe visual impairment may occur. The impact of ocular trauma is a major cause for concern due to its devastating effects on the individual as well as the burden it places on the socioeconomic and health resources of any nation.<sup>2</sup> The National Society for the prevention of blindness estimates that up to 90% of all eye injuries are preventable,

especially in the paediatric age group. Epidemiological studies in our environment are necessary to determine the causes of ocular trauma so that strategies to prevent or reduce their occurrence are implemented.<sup>3</sup> This study is conducted to identify the aetiology and nature of ocular trauma affecting our population, including the groups at risk, visual outcome and the need for hospitalization or surgery in our setting.

## Methods and Materials

This is a prospective hospital based observational study of 70 patients during a period of two years was included from June 2016 to June 2018. Consecutive subject who were referred to the eye unit with eye injury or directly attended the eye OPD or attended in the emergency department were included in the study once written consent was obtained. Data were collected on patient's age, gender, affected eye, aetiology of trauma, place of trauma, socio-economic status, associated periocular injuries, visual acuity, fundus examination, intraocular pressure (IOP) at presentation, imaging studies done, primary or secondary surgical intervention and hospital admission. Any substance abuse was also included. Those who were presented with periocular chemosis only was treated with oral analgesic and anti-inflammatory drugs. Those who had corneal and conjunctival foreign body were treated with removal under local anaesthetic agent. Chemical injury cases were first managed with normal

saline irrigation followed by topical antibiotic, cycloplegic, steroid drops and antibiotic ointment patching for 24 hour. All of them were continued topical cycloplegic, antibiotic and steroid drops for 7 days. Those were presented with blunt trauma hyphaema was treated with topical high potency steroid, cycloplegic and anti-glaucoma drop with systemic tranexamic acid (500mg) 1 tab thrice daily for 7 days. Corneal and conjunctival lacerations were treated with suturing in the OT after being admitted. Corneal abrasions were treated with antibiotic patching for 24 hour followed by topical antibiotic and lubricating drops for 7 days. Those who presented with vitreous haemorrhage, choroidal rupture and sub-hyaloid haemorrhage were treated with systemic steroid along with topical steroid and cycloplegic drops followed by retina specialist consultation. The traumatic optic neuritis cases were treated with intravenous methyl-prednisolone 30mg bolus followed by 5.4mg/kg/body wt for 48 hour as per ONTT guideline followed by referral to the higher centre for surgical management. All corneal perforation, globe injury and lid laceration cases were admitted followed by surgical repair. Those who had severe penetrating eye injury, globe rupture and had no vision (PL negative) were underwent enucleation under general anaesthesia. Those who had traumatic anterior dislocation of lens and had cataract were underwent small incision cataract surgery under peribulbar anaesthesia followed by PMMA lens insertion. Those I left surgical aphakic were treated with secondary anterior chamber IOL with peripheral iridectomy under peribulbar anaesthesia. All of them were followed after 7 days, 1 month, 3 months, after 6 months, after 1 year and after 2 years. Best corrected visual acuity (BCVA), Goldman applanation tonometry for intraocular pressure, gonioscopy and fundus examination were done in the follow up. Cases of primary intervention also were included in the follow up. The only case I referred to mainland was traumatic optic neuritis with optic canal fracture with bony chip inside the canal. In our study, ocular trauma was defined as any injury to the eye and adnexa which led to an emergency ophthalmology referral or ophthalmology attention.

**Inclusion Criteria**

Patients presenting to the ophthalmology outpatient department or referred to our department or attended in the emergency department, ANIIMS, Port Blair India, with history and signs of ocular trauma were included in the study.

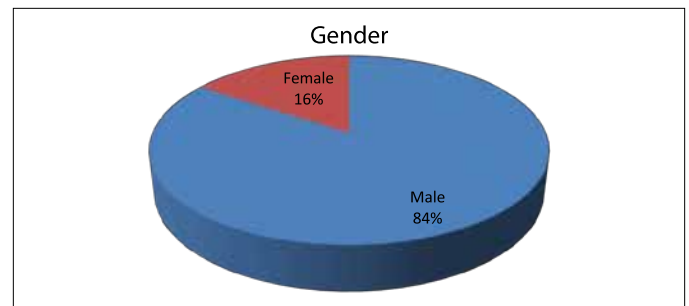
**Exclusion Criteria**

1. Patient in whom assessment was difficult due to severe head injury with reduced level of consciousness and cooperation.
2. History of any past ocular pathology, which impairs best-corrected visual acuity (BCVA).

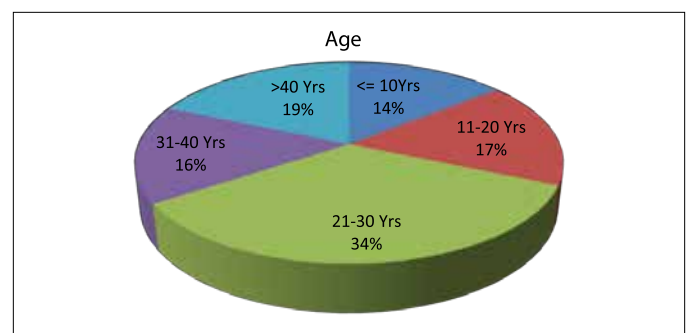
**Results**

This hospital based prospective observational study was conducted over a period of two years from June 2016 to June 2018. There were 77 eyes of 70 patients, of which male was predominant 84%. [Graph-1] The highest incidence of

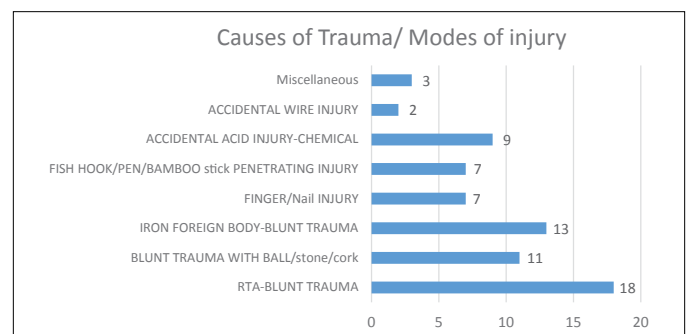
trauma was seen in the 21-30 year age group (34%). [Graph-2] Commonest type of injury was blunt trauma. [Graph-3] Blunt trauma due to road traffic accident (RTA) was 25.7% and trauma with other agents were 15.7%. Penetrating injury was noted in 8.6% of cases. Most commonly affected eye was right 74% and most of the patients were socio-economically stable. Various agents that had causes ocular trauma are mentioned in the [Table-1]. Corneal epithelial defects were mostly encountered lesion in my study 32.9% [Figure 1(a)] followed by corneal perforation 11.4% [Figure 2(a,b,c,e)] and lid laceration 7.1% [Figure 3]. [Table-2] Traumatic anterior dislocation of lens [Figure 1(e)] were found in 2.9% of cases, whereas traumatic cataract was found in 5.7% of cases [Figure 1(d)] and in few cases there were iridodiolysis [Figure 4(b)]. Traumatic uveitis [Figure 4(c,d,f)] and traumatic mydriasis [Figure 4(a)] were found in 7.1% of cases. Conjunctival injuries like sub-conjunctival haemorrhages were seen in 4.3% and conjunctival laceration [Figure 5(e)] in 2.9% of cases. Traumatic hyphaema [Figure 2(d,f)] were found in 5.7% of cases. Globe rupture [Figure 5(a,b,c,f)] was there in 4.3% of cases. In one case there was retinal sub-hyaloid



Graph 1



Graph 2



Graph 3

Table 1

TRAUMATIC AGENT & TYPE OF INJURY	Frequency	Percent
Chemical injury cement-1	2	2.9
Chemical injury battery acid-2	2	2.9
Chemical injury bleaching powder-3	2	2.9
Chemical injury agarwati-4	1	1.4
Chemical injury cracker-5	2	2.9
Finger nail injury-6	7	10
Penetrating injury-7	6	8.6
Blunt trauma RTA-8	19	27.1
Blunt trauma cricket ball-9	7	10
Blunt trauma with stone-10	2	2.9
Blunt trauma with badminton cock-11	2	2.9
Iron foreign body-12	13	18.6
Accidental wire injury-13	2	2.9
Cow tailinjury-14	1	1.4
Accidental warm water injury-15	1	1.4
ACCIDENTAL PENCIL INJURY-16	1	1.4
Total	70	100

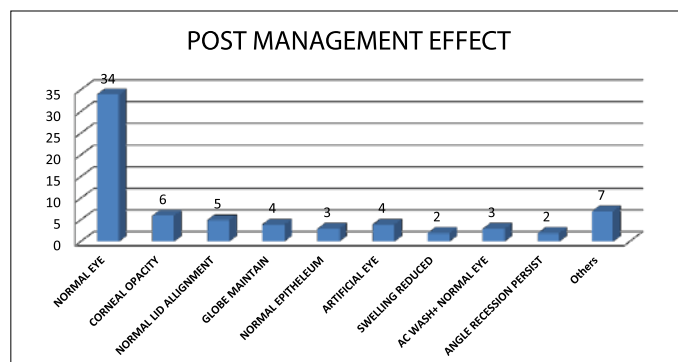
Table 2

TYPE OF LESION, LOCATION of injury & eye involvement	Frequency	Percent
Corneal epithelial defect both eyes-1	4	5.7
Corneal epithelial defect unilateral eye-2	23	32.9
Sub conjunctival haemorrhage-3	3	4.3
Conjunctival laceration-4	2	2.9
Corneal perforation & iris prolapse-5	8	11.4
Lid laceration-6	5	7.1
Globe rupture-7	3	4.3
Lidchymosis-8	2	2.9
Hypaema-9	4	5.7
Traumatic mydriasis & uveitis-10	5	7.1
Traumatic cataract-12	4	5.7
Anterior dislocation of lens-13	2	2.9
Traumatic optic neuropathy-14	1	1.4
Traumatic ptosis-15	1	1.4
Sub hyaloids haemorrhage-16	1	1.4
Choroidal tear-17	1	1.4
Traumatic fungalulcer-18	1	1.4
Total	70	100

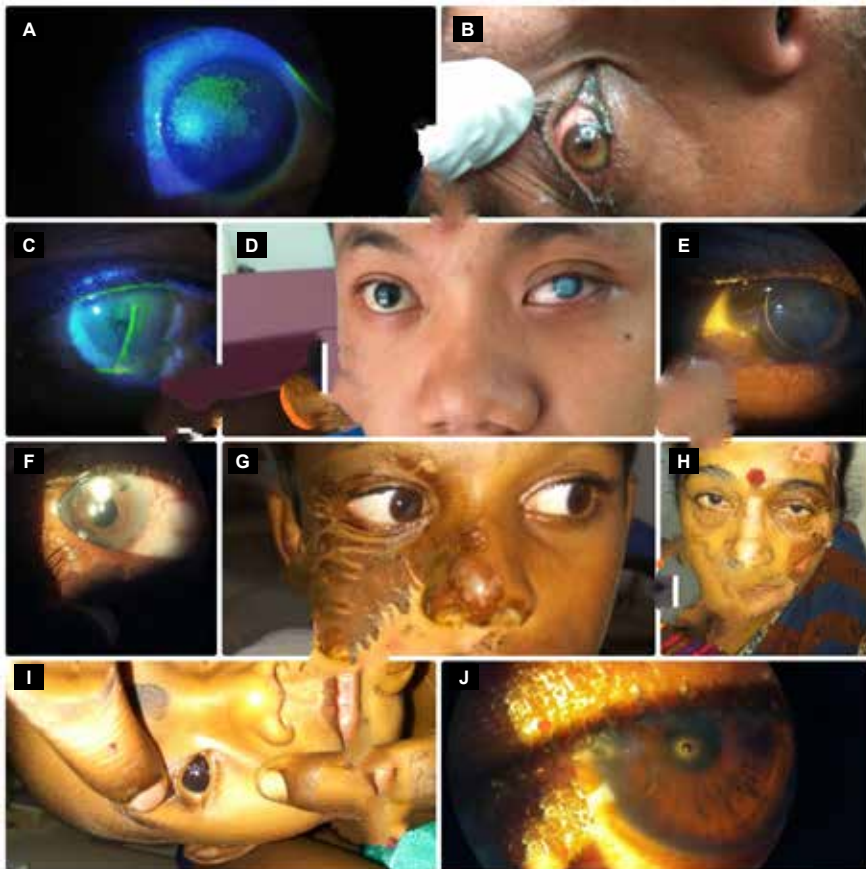
haemorrhage [Figure 6(a)]. Choroidal rupture due to blunt trauma was seen in 1.4% of cases [Figure 6(b)]. Retinal detachment [Figure 6(c)] and traumatic macular hole [Figure 6(d)] was found in one case each. There was only one case of traumatic optic neuritis with optic canal fracture with a bony chip found inside the optic canal [Figure 6(e)]. He was underwent surgical decompression surgery in the mainland and later on developed optic atrophy [Figure 6(f)]. Chemical injuries were found in nine (9) cases [Figure 1(a,b,g)]. Intraocular pressure at the time of presentation was normal in maximum patients except in two [eight ball hypaema] cases, which came to normal after treatment. The rate of hospitalization was 42.85% [30 patients] and maximum stay in the hospital was three (03) days. Only 8.6% cases were developed corneal opacity, [Graph-4] 2.9% cases developed angle recession glaucoma [Figure 4(e)] and 5.7% population needed artificial eye following enucleation [Figure legend-5(g)]. [Table-2] Corneal injuries in the children bellow 10 years of age [Figure 1(i)] were found in 14% of cases. Corneal and conjunctival foreign bodies [Figure 1(j)] were found in 13 cases (18.6%). There was only one case who presented with traumatic ptosis, one case had traumatic third nerve palsy and one case presented with traumatic seven nerve palsy which later on needed permanent tarsorrhaphy. The best outcome of primary intervention were maintaining normal lid anatomy in all lid laceration patients. [Figure 3] Surgical intervention was required in 35.71% (25/70) of eye injuries whereas rest were managed conservatively. Imaging studies were required in 27cases (38.57%). X-ray imaging were in (15.5%) of cases, USG-B-scan in 26 cases (37.1%) and computed tomography (CT) scan in 3.6% of cases. MRI brain and orbit was done only in traumatic optic neuritis case. The best corrected visual acuity after trauma was 6/6 in maximum patients with p-value <0.001.

Discussion

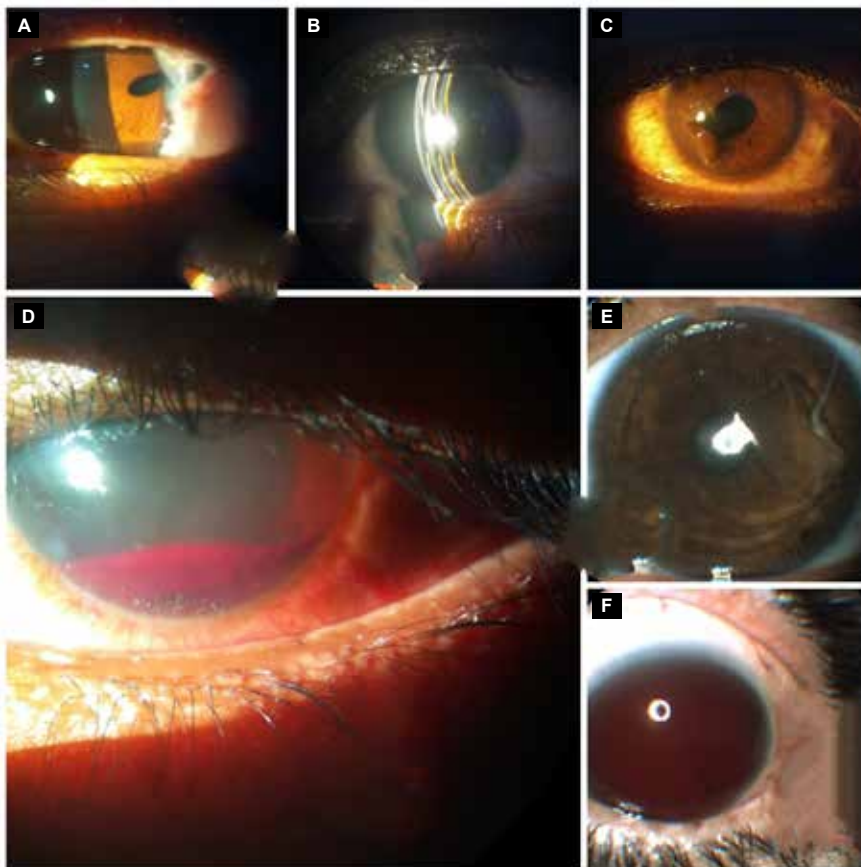
Ocular trauma has been investigated in many population based studies in the USA and Canada as well as the United Kingdom and Australia. There is a geographical variation in the cause of ocular injury which is age and gender specific.<sup>4</sup> Studies from different regions such as the Caribbean<sup>5</sup> Singapore<sup>6</sup> and India<sup>7</sup> demonstrate variations in the characteristics, incidence and prevalence of ocular trauma. The variations emphasize the influence of different methods of data collection, socioeconomic factors and industrialization of a population on the epidemiology of eye trauma.<sup>8</sup> In this study, we utilized patient interviews similar to the method described in one study by Khattry et al.<sup>9</sup> Such methods tend to be more accurate than data from emergency departments which tend to be biased toward much more severe injuries. The present study demonstrates that males were more susceptible to eye injury than females, irrespective of their age which was similar to earlier studies.<sup>10</sup> The highest incidence of ocular trauma occurred in the 21–30 year age group.<sup>10</sup> This is similar with other studies but some authors also describe a bimodal pattern where an increased incidence is observed in the 25–30 year age group (first peak), and the second peak incidence is seen after 70 years.<sup>10</sup> Blunt injuries were the most frequent type of injury occurred



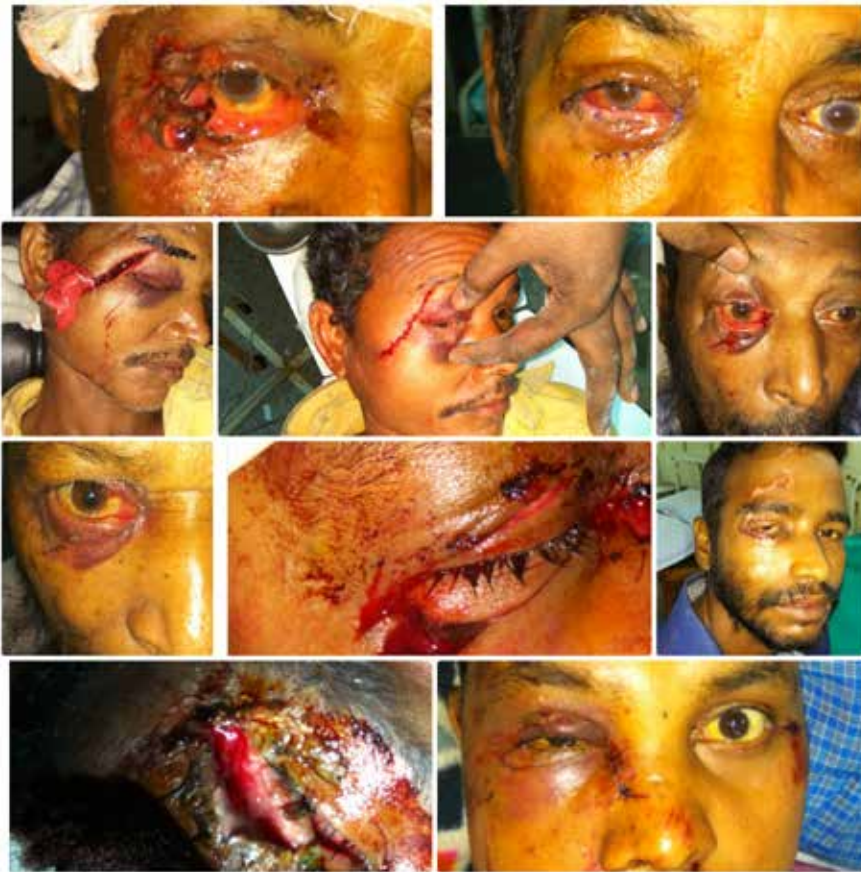Graph 4



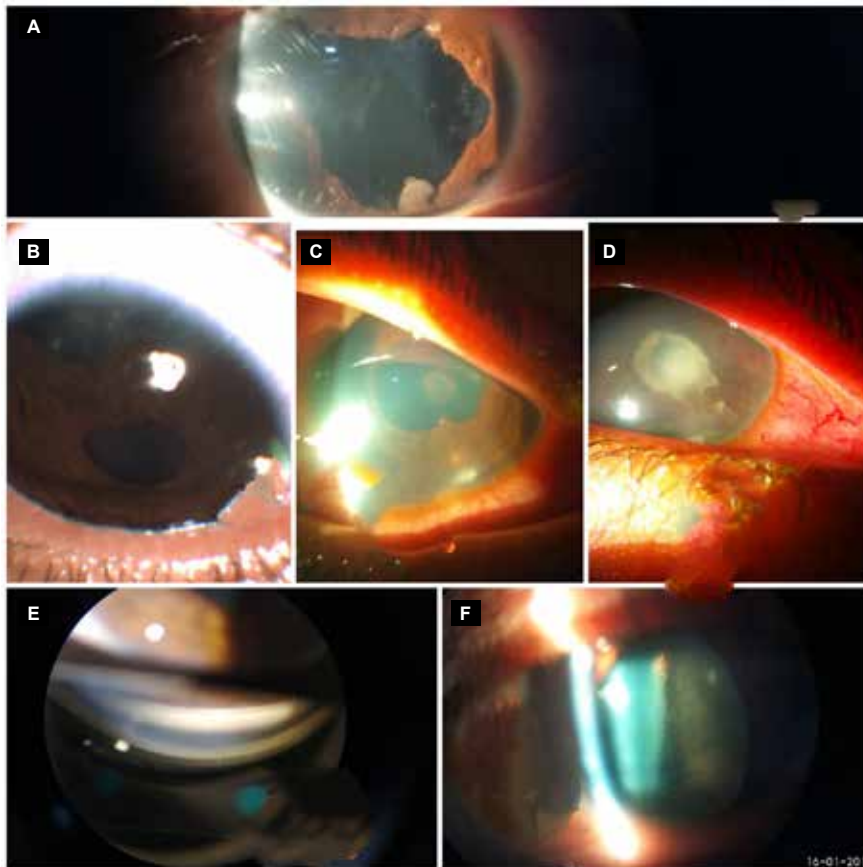
**Figure 1:**  
 (a) corneal epithelial defect;  
 (b) Cement injury;  
 (c) Corneal wire injury;  
 (d) Traumatic cataract;  
 (e) Anterior dislocation of lens;  
 (f) Anterior chamber ACIOL;  
 (g) Cracker injury;  
 (h) Warm water injury;  
 (i) Agarbati corneal injury;  
 (j) Corneal FB



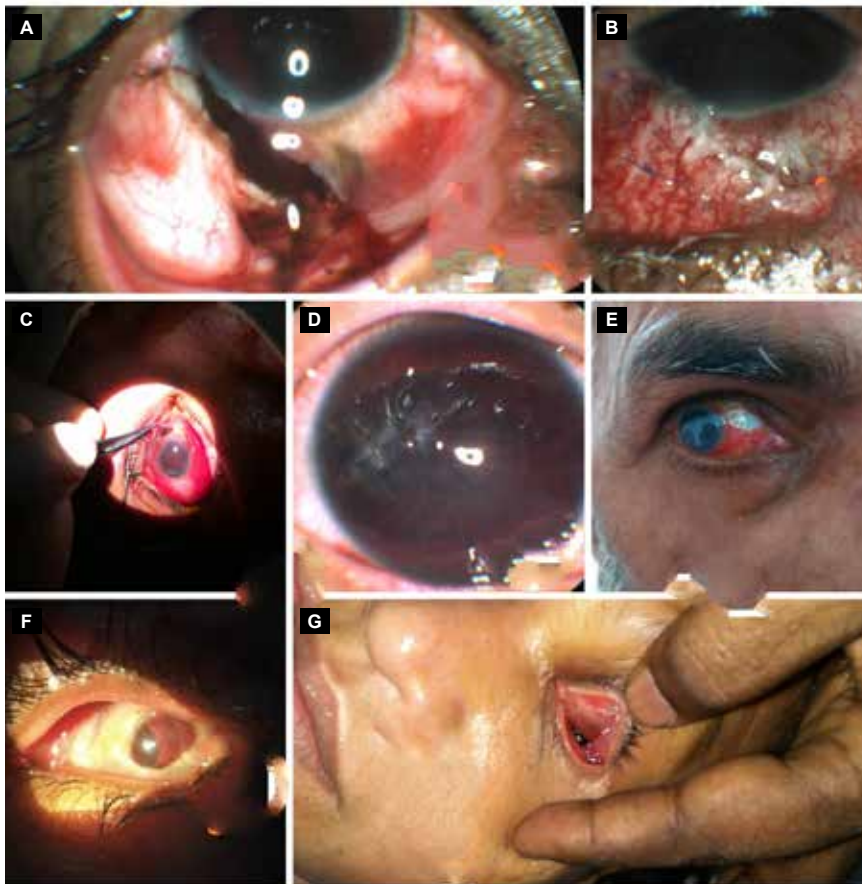
**Figure 2:**  
 (a,b,c,e) corneal perforation;  
 (d,f) Hyphaema



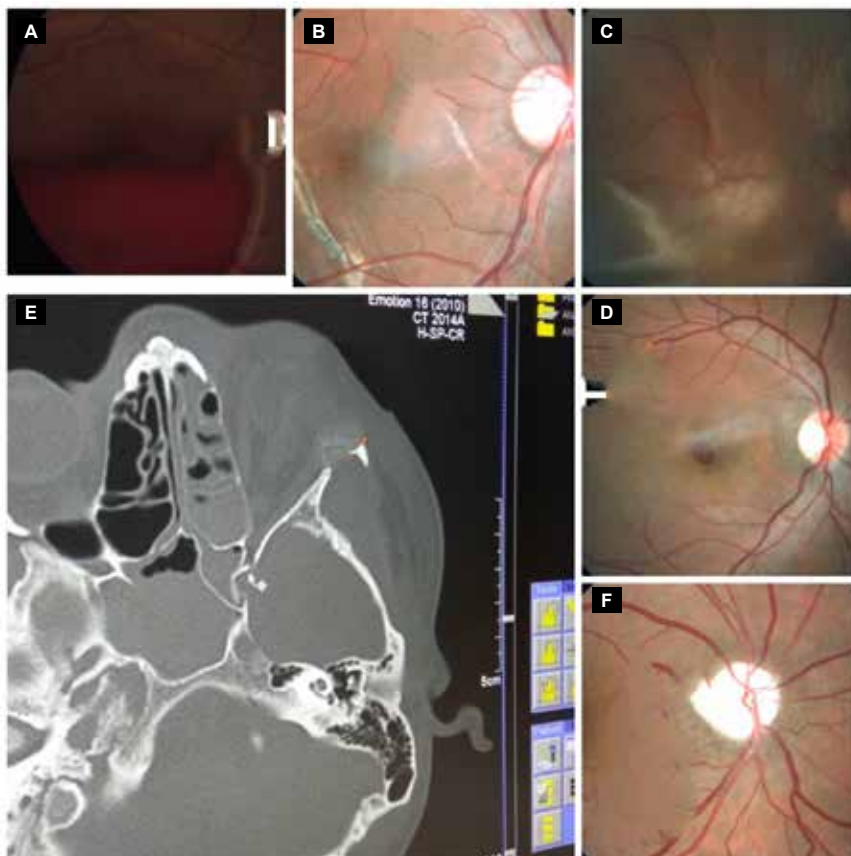
**Figure 3:**  
*Lid laceration and after repair*



**Figure 4:**  
*(a) Traumatic mydriasis;  
(b) Traumatic iridodialysis;  
(c,d,f) Traumatic uveitis;  
(e) Traumatic angle recession*



**Figure 5:**  
 (a,b,c,f) Globe rupture;  
 (d) Corneal laceration repaired;  
 (e) Conjunctival laceration;  
 (g) After enucleation



**Figure 6:**  
 (a) Retinal sub hyaloids haemorrhage;  
 (b) Choroidal rupture;  
 (c) Retinal detachment;  
 (d) Macular hole;  
 (e) Optic canal fracture;  
 (f) Optic atrophy

in my study. This was different from an earlier study where 50% of ocular injuries were open globe and 29.8% were from blunt trauma in hospitalized adults with ocular injuries.<sup>11</sup> There was a high association between blunt trauma and the need for hospitalization in our study. The highest incidence of ocular trauma in my study were occurred at road. The domestic setting produced all types of trauma, but blunt and penetrating injuries were the most frequent types of injuries occurring in the home. This correlation was also seen in studies by Desai et al and Khatry et al.<sup>9</sup> In the paediatric age group, our study reports agreed with the literature that the majority of injuries occurred at home and could be avoided with supervision. These important trends highlight the need for prevention strategies to increase public awareness and re-emphasize the use of protective eye wear within the high-risk groups in the population while engaging in common domestic activities which can likely cause eye injury.<sup>12</sup> Penetrating injuries are also a significant public health problem, frequently caused by sharp objects, metal fragments, and pieces of wood and glass fragments. In other studies, metallic and sharp objects were found more frequently the cause of eye injuries in males, while females showed a higher risk of blunt trauma.<sup>13</sup> In the present study, 8.6% of patients had penetrating injury similar with 9.2% in other studies.<sup>11,12</sup> Ocular injury, visual impairment and blindness associated with facial fractures leads to severe impact on the family, their economic status as well as on the economic status on the nation.<sup>14</sup> Awareness of the causes of ocular trauma and implementation of preventative strategies can help in the reduction of serious ocular trauma. Trauma registries have a purpose in collecting essential public health information which can be analysed and the results can be used in the planning and policy-making and thus ultimately reducing morbidity. A reduction in ocular trauma will reduce permanent visual impairment and thus will leads to a significant reduction in the burden on the health services of the island.<sup>15</sup>

### Conclusion

Ocular injury, visual impairment and blindness associated with trauma leads to severe impact on the family, their economic status as well as on the economic status of the nation. Hence safety measures are very important in preventing trauma related morbidity.

### References

1. Wong TY, Klein BE, Klein R. The prevalence and 5-year incidence of ocular trauma. The Beaver Dam Eye Study. *Ophthalmology*, 2000; 107:2196-202.
2. Négrel AD, Thylefors B. The global impact of eye injuries. *Ophthalmic Epidemiol*, 1998; 5:143-69.
3. Dandona L, Dandona R, Srinivas M, John RK, McCarty CA, Rao GN. Ocular trauma in an urban population in Southern India: The Andhra Pradesh Eye Disease Study. *Clin Exp Ophthalmol*, 2000; 28:350-6.
4. Koo L, Kapadia MK, Singh RP, Sheridan R, Hatton MP. Gender differences in etiology and outcome of open globe injuries. *J Trauma*, 2005; 59:175-8.
5. Mowatt L, McDonald A, Ferron-Boothe D. Hospitalization trends in adult ocular trauma at the University Hospital of the West Indies. *West Indian Med J*, 2012; 61:605-9.

6. Wong TY, Tielsch JM. A population-based study on the incidence of severe ocular trauma in Singapore. *Am J Ophthalmol*, 1999; 128:345-51.
7. Krishnaiah S, Nirmalan PK, Shamanna BR, Srinivas M, Rao GN, Thomas R. Ocular trauma in a rural population of southern India: the Andhra Pradesh Eye Disease Study. *Ophthalmology*, 2006; 113:1159-64.
8. Abbott J, Shah P. The epidemiology and aetiology of paediatric ocular trauma. *Surv Ophthalmol*, 2013; 58:476-85.
9. Khatry SK, Lewis AE, Schein OD, Thapa MD, Pradhan EK, Katz J. The epidemiology of ocular trauma in rural Nepal. *Br J Ophthalmol*, 2004; 88: 456-60.
10. Gordon KD. The incidence of eye injuries in Canada. *Can J Ophthalmol*, 2012; 47:351-3.
11. Dannenberg AL, Parver LM, Brechner RJ, Khoo L. Penetrating eye injuries in the work place. The National Eye Trauma System Registry. *Arch Ophthalmol*, 1992; 110:843-8.
12. Downes SM, Hambleton IR, Chuang EL, Lois N, Serjeant GR, Bird AC. Incidence and natural history of proliferative sickle cell retinopathy: observations from a cohort study. *Ophthalmology*, 2005; 112: 1869-75.
13. Nirmalan PK, Katz J, Tielsch JM, Robin AL, Thulasiraj RD, Krishnadas R, et al. Ocular trauma in a rural south Indian population: the Aravind Comprehensive Eye Survey. *Ophthalmology*, 2004; 111: 1778-81.
14. Magarakis M, Mundinger GS, Kelamis JA, Dorafshar AH, Bojovic B, Rodriguez ED. Ocular injury, visual impairment, and blindness associated with facial fractures: a systematic literature review. *Plast Reconstr Surg*, 2012; 129:227-33.
15. Nwomeh BC, Lowell W, Kable R, Haley K, Ameh E A. History and development of trauma registry: lessons from developed to developing countries. *World J Emerg Surg*, 2006; 110: 843-8.

**Cite This Article as:** Das S, Rana M. Patterns of Ocular Trauma Presenting to the Tertiary Eye Care Centre in the Islands of Andaman and Nicobar.

**Acknowledgments:** Nil

**Conflict of interest:** None declared

**Source of Funding:** None

**Date of Submission:** 25 February 2019

**Date of Acceptance:** 4 December 2019

### Address for correspondence

**Sujit Das MS**

Department of Ophthalmology,  
JNU Medical College & Research Centre,  
Jaipur, Rajasthan-302017  
India

Email id: imdrsujitdas@gmail.com



Quick Response Code