

# Visual Outcome In Patients of Indirect Traumatic Optic Neuropathy Treated with Steroids

Menezes Valerie<sup>1</sup>, Usgaonkar Ugam<sup>1</sup>, Menezes Ramona<sup>2</sup>

<sup>1</sup>Department of Ophthalmology, Goa Medical College, Goa, India

<sup>2</sup>Department of Radiology, Goa Medical College, Goa, India

**Background:** Indirect Traumatic Optic Neuropathy (TON) is an important cause of visual morbidity which may be reversible.

**Aims:** To assess the Visual Outcome in patients with Indirect TON Treated With Steroids.

**Settings and Design:** Prospective Non Randomised Study.

**Methods and Material:** 34 patients, having mild Traumatic Brain Injury (TBI) with unilateral indirect TON were included. All patients received treatment with Methyl prednisolone 1 gm IV/day for 3 days followed by oral prednisolone 1 mg/kg for 11 days. Patients were divided into 2 groups. Group 1 included 17 patients who received steroids within 72 hours of injury. Group 2 included 17 patients who received steroids after 72 hours of injury.

## Abstract

**Statistical analysis used:** The Wilcoxon Signed Rank Test was used as the statistical test for visual acuity improvement for each of the groups. Fischer's exact test was used to assess statistical significance of visual acuity improvement between the 2 groups.

**Results:** At 1 month follow up, 14 of 17 patients in Group 1 (82.4%) and 12 of 17 patients in Group 2 (70.6%) showed improvement in Visual Acuity which was statistically significant. The difference in visual acuity improvement between the two groups was not statistically significant.

**Conclusions:** In patients of indirect TON having mild TBI, high dose steroids optimized the visual acuity, without any adverse effects, both in patients who presented within 72 hours and beyond 72 hours of injury.

Delhi J Ophthalmol 2020;30;27-31; Doi <http://dx.doi.org/10.7869/djo.541>

**Keywords:** Traumatic Optic Neuropathy, Steroids.

## Introduction

Traumatic optic neuropathy (TON) refers to any insult to the optic nerve secondary to trauma. The incidence following blunt or penetrating trauma is 0.7 to 2.5%.<sup>1,2</sup> Studies have shown that approximately 40-60% of patients present with severe visual loss of light perception or worse.<sup>3</sup>

TON can be classified according to the mode of injury as direct or indirect. Direct TON results from a significant anatomical disruption of the nerve. Indirect TON is caused by the transmission of forces to the optic nerve from a distant site, without any overt damage to the surrounding tissue structures. The deformative stress transmitted to the skull from blunt trauma is concentrated in the region of the optic canal. The intracanalicular segment of the optic nerve is particularly susceptible to this form of injury.<sup>4</sup>

Direct TON results in severe, irreversible visual loss and no intervention is of proven benefit. In indirect TON, following trauma there is an immediate shearing of a proportion of the Retinal Ganglion Cells (RGC) axons, an irreversible process, with subsequent RGC degeneration. There is then optic nerve swelling, within the limited confines of the optic canal, secondary to mechanical trauma or vascular ischemia. This impairs the already compromised blood supply to the surviving RGC. This forms the rationale for optic nerve decompression by medical or surgical means, in order to break the cycle and preserve the RGC that survived the initial insult.<sup>5,6</sup>

The main treatment options for TON are: systemic steroids, surgical decompression of the optic canal, combination of steroids and surgery and observation (conservative management) alone.<sup>6</sup>

The aim of this study was to assess the visual outcome in patients with indirect TON treated with steroids.

## Subjects and Methods

This was a prospective non randomized study including 34 patients with unilateral indirect TON attending a tertiary care centre from April 2017 to December 2017. Approval from the Ethics Committee was obtained prior to the study. Informed consent was obtained from all patients.

A diagnosis of TON was made on the basis of decreased visual acuity after history of head trauma, a relative afferent pupillary defect, defective colour vision and/or visual field defects.

Only patients with mild traumatic brain injury (TBI) were included. Mild TBI was defined as brain injury resulting in loss of consciousness for less than 30 minutes and Glasgow Coma Scale (GCS) of 13-15.

## Exclusion criteria:

1. Moderate TBI (defined as brain injury resulting in loss of consciousness from 30 minutes to 6 hrs and GCS of 9-12) and Severe TBI (defined as brain injury resulting in loss of consciousness for > 6hrs and GCS 3-8)

2. Eyes with penetrating trauma
3. Direct TON ( cases of optic nerve avulsion, optic nerve transection, optic nerve sheath haemorrhage)
4. Cases of TON with CT scan showing evidence of impingement of optic nerve by fracture fragment
5. Cases of post-traumatic visual loss not related to optic nerve dysfunction (traumatic cataract, retinal detachment, choroidal rupture, vitreous haemorrhage)

History regarding the time and nature of trauma, level of consciousness after trauma, onset and duration of symptoms and time of presentation to hospital was obtained.

Patients underwent ophthalmological evaluation including Visual acuity-Best Corrected Visual Acuity applied according to refraction, colour vision (by Ishihara’s pseudoisochromatic plates), assessment of pupillary reactions and fundus examination.

Plain CT Head and orbit was done for all cases. Baseline Electrocardiogram, Blood pressure and blood sugar levels were obtained for all patients.

All patients enrolled received treatment with Methylprednisolone 1 gm IV /day in 100ml of normal saline (for 3 days) followed by oral prednisolone (1 mg/kg) for 11 days. Patients were followed up at 3 days, 11days and 1 month and visual function monitored.

For assessment of visual outcome, patients were categorized into 2 groups

- 1) Group 1: included 17 patients who received steroids within 72 hours of injury, having presented early with diagnosis of TON within 72 hours of injury.
- 2) Group 2: included 17 patients who received steroids after 72 hours of injury. These included patients who presented after 72 hours of injury and patients in whom there was a delay in the diagnosis of TON.

The patients vision was considered to be improved if there was an increase of 2 or more lines on the Snellen’s chart or if vision improved from no perception of light to perception of light, from perception of light to hand movements or from hand motions to finger counting.

The data was analyzed using the SSPS software and the Wilcoxon Signed Rank Test was used as the statistical test for the visual acuity improvement for each of the groups. Fischer’s exact test was used to assess statistical significance of visual acuity improvement between the 2 groups.

### Results

This prospective non randomised study included 34 patients of mild TBI with a unilateral indirect TON. There were 28 male and 6 female patients. The mean patient age was 30.82 years (SD 13.167). The major causes of trauma were motor vehicular accidents (91%) followed by falls (6%) and assaults (3%) (Figure 1).

The right eye was affected in 16 patients and the left eye was affected in 18 patients. A relative afferent pupillary defect was detected in all 34 patients.

In 13 patients, CT scan was normal. The associated fractures seen in the remaining patients are detailed in Figure 2.

None of the patients had evidence of optic nerve compression or optic canal fracture on CT scan.

Periorbital haematomas and subconjunctival haemorrhage were present in all 34 patients.

All patients enrolled received treatment with Methyl prednisolone 1 gm IV /day (for 3 days) followed by oral prednisolone (1 mg/kg/day) for 11 days.

At 1 month follow up, improvement in visual acuity was as follows

Group 1: 14 out of 17 patients improved (82.4%)

Group 2: 12 out of 17 patients improved (70.6%)

By the Wilcoxon Signed Ranks test, in Group 1 the Z value for visual acuity improvement was -3.238 with a p value of 0.001. In Group 2, the Z value was -3.025 with a p value of 0.002.

The difference in visual acuity improvement between Group 1 and 2 was not statistically significant by Fischer’s exact test (p=0.688).

Fundus examination at 1 month follow –up was normal in 21 patients and revealed temporal disc pallor in 13 patients. Figure 3 shows the number of patients with improvement in Visual acuity in Group 1 and 2. Figure 4 and 5 shows the visual acuity pre treatment and post–treatment with steroids for group 1 and 2 respectively.

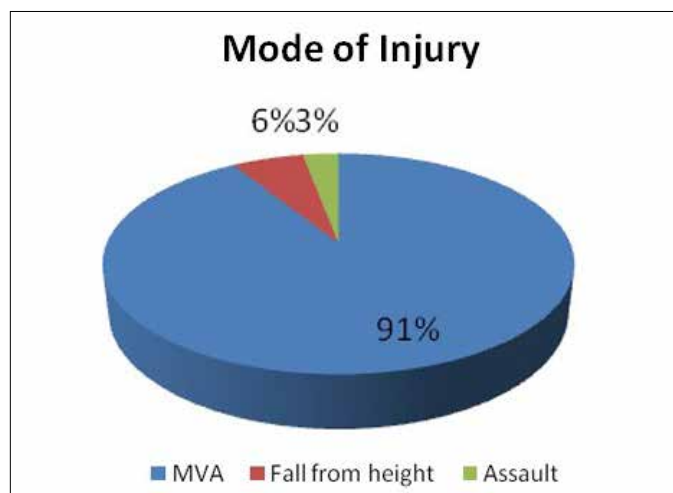


Figure 1: Showing the mode of injury of patients of TON

Findings on CT scan	Number of patients
<b>(A) Orbital wall fracture</b>	
Lateral wall	10
Medial wall	4
Roof	4
Floor	1
<b>(B) Skull fracture</b>	
Frontal bone	9
Parietal bone	0
Temporal bone	6
Occipital bone	0

Figure 2: Showing orbital and skull fractures

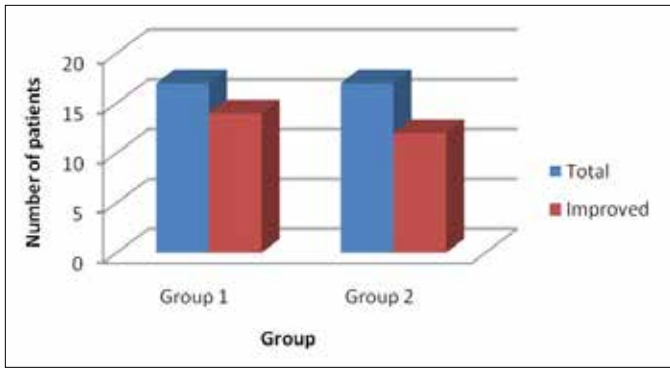


Figure 3: Number of patients with improvement in Visual acuity in Group 1 and 2

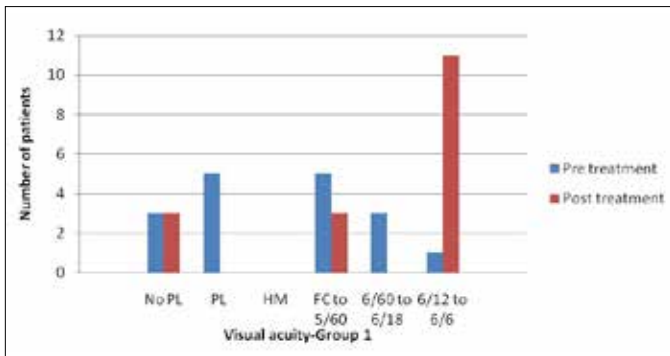


Figure 4: Visual acuity pre treatment and post-treatment with steroids for group 1 (PL-Perception of Light, HM-Hand Movements, FC-Finger Counting)

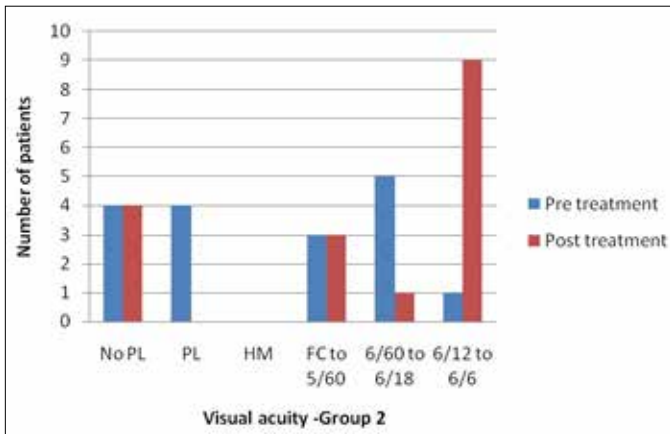


Figure 5: Visual acuity pre treatment and post-treatment with steroids for group 2. (PL-Perception of Light, HM-Hand Movements, FC-Finger Counting)

**Discussion**

The main treatment options for indirect TON are: systemic steroids, surgical decompression of the optic canal, combination of steroids and surgery and observation alone. There is as yet no optimum management protocol for its management.

The controversy in therapy of TON stems from two facts. Firstly, literature lacks a well executed randomized controlled clinical trial, due to both the relative difficulty in recruitment of adequate numbers and the highly heterogeneous presentation. The second reason is the unpredictable yet frequent incidence of spontaneous recovery of TON.<sup>7</sup>

In this study, 82.4% patients in Group 1 and 70.6% patients in Group 2 showed improvement in Visual acuity with steroids which was sustained at 1 month follow up. By the Wilcoxon Signed Ranks test, the improvement in Visual acuity in both the groups 1 and 2 following treatment with steroids was statistically significant (p=0.001 for Group 1 and p=0.002 for Group 2). As per the results of this study, the visual outcome was better in patients who received treatment within the first 72 hours of injury (82.4% improvement in Group 1). However even in patients who presented after 72 hours of injury, treatment with systemic steroids improved the visual outcome (70.6% improvement in Group 2). Moreover, the difference in the final visual acuity between the 2 groups was not statistically significant (p=0.688). 9 patients (52.94%) in Group 2 had a final visual acuity between 6/12 to 6/6. In group 2 the mean interval between the trauma and the administration of steroids was 10 days. Reasons for the delay in administration of steroids could be delay in diagnosis of TON for example in patients presenting with head injury and loss of consciousness (due to which there is difficulty in assessing vision).

In Group 2, nine patients presented 4 days after injury, two patients presented 5 days after injury, one patient presented 7 days after injury, two patients came 10 days after injury, two patients presented 3 weeks later and one patient presented 4 months after the initial trauma. The maximum time between the injury and steroid administration was 4 months and an improvement of vision was noted in this patient.

The results indicate that a trial of systemic corticosteroids can be considered in all patients of indirect TON with mild TBI in order to optimise the visual outcome.

Prognostic factors for improvement in visual acuity with steroids were the visual acuity at presentation and the time period between the injury and the administration of steroids. In our study, prognosis was uniformly poor, for patients presenting with a visual acuity of no light perception (i.e. 3 patients in Group 1 and 4 patients in Group 2), and the final visual acuity in all 7 patients remained no light perception despite a full course of corticosteroids. This was in agreement with other studies.<sup>6</sup> In our study, in Group 1, all patients presenting early and receiving steroids within 72 hours of injury showed improvement in vision (with the exception of the three patients in Group 1 presenting with no light perception).

Four variables are related to a poor outcome in TON: blood in the posterior ethmoid cells, loss of consciousness, age over 40, and absence of improvement after two days of steroid treatment.<sup>8</sup>

The International Optic Nerve Trauma Study<sup>9</sup>, was designed to compare the visual outcome of TON patients treated with corticosteroids, optic canal decompression, or observed without treatment. No clear benefit was found for either treatment modality and it was concluded that the decision to treat or not to treat should be made on an individual case basis.

Steroids exert a neuroprotective effect following trauma, the postulated mechanism being their antioxidant properties and the inhibition of free radical- induced lipid peroxidation.<sup>10</sup> This was also confirmed by the National Acute Spinal Cord

Injury Study.<sup>11</sup> The application of steroids in TON relies on the extrapolation from this study. In TON, steroids probably reduce the intraneural or extraneural edema and relieve the compression of the nerve fibres.<sup>12</sup> By reducing vasospasm, steroids may also limit contusion necrosis of the nerve.<sup>13</sup>

Steroid regimes can be classified as high dose (500-1999 mg), very high dose (2000-5399 mg) and megadose (>5400 mg) based on the initial daily dose of methylprednisolone used.<sup>14</sup>

The findings of the Corticosteroid Randomisation after Significant Head Injury (CRASH) study have to be considered in patients of TON with significant Head injury. It investigated the effectiveness and safety of megadose steroids in these patients and concluded that megadose steroids should no longer be routinely used.<sup>15</sup> In particular, megadose steroids should be considered possibly harmful.<sup>16</sup> Another study showed a significant increase in complication rates with very high dose steroids.<sup>17</sup> Therefore, high dose steroids i.e. a maximum daily dose of 1 gm methylprednisolone has been advocated in TON to minimise the risk of neurotoxicity.<sup>5</sup>

In our study, only patients with Mild TBI were included. Owing to the higher complication rate noted with megadose and very high dose steroids, the regimen of high dose steroids was chosen in this study. The regimen of high dose steroids was as per that used in the Optic Neuritis Treatment Trial<sup>18</sup> i.e. 1 gm of intravenous methylprednisolone per day for 3 days, followed by 1 mg/kg/day of oral prednisolone for 11 days. All cases of Mild TBI diagnosed with a TON were administered high dose steroids only after full recovery. No adverse effects were observed with this regimen of steroids. Several studies<sup>19,20,21</sup> have shown that treatment of TON (either with corticosteroids or extracranial decompression or both) results in better improvement in visual acuity than conservative management alone. In a study on indirect TON<sup>22</sup>, it was found that in those patients whose vision did improve, the improvement started earlier when steroids were used.

A study<sup>23</sup> suggests that combined therapy of methylprednisolone injections and endoscopic optic nerve decompression should be offered to patients of TON who present within 72 hours of injury. Optic nerve decompression is beneficial only if performed, when there is radiological evidence of optic canal fracture (and impingement of the optic nerve by the fracture fragment) or optic nerve sheath haematoma.<sup>24</sup> Limitations of this study were small sample size and lack of control group.

### Conclusion

In this study, in patients of indirect TON having mild TBI, high dose steroids optimized the visual acuity, without any adverse effects, both in patients who presented within 72 hours and beyond 72 hours of injury

### References

1. Al-Qurainy IA, Dutton GN, Stassen LF, Moos KF, El-Attar A. The characteristics of midfacial fractures and the association with ocular injury: a prospective study. *British journal of oral and maxillofacial surgery*. 1991; 29(5):291-301.
2. Nau HE, Gerhard L, Foerster M, Nahser HC, Reinhardt V, Joka T. Optic nerve trauma: clinical, electrophysiological and histological remarks. *Acta neurochirurgica*. 1987; 89(1):16-27.
3. Lee V, Ford RL, Xing W, Bunce C, Foot B. Surveillance of traumatic optic neuropathy in the UK. *Eye*. 2010; 24(2):240-50.
4. Yu-Wai-Man P. Traumatic optic neuropathy—Clinical features and management issues. *Taiwan journal of ophthalmology*. 2015; 5(1):3-8.
5. Steinsapir KD, Goldberg RA. Traumatic optic neuropathy: a critical update. *Compr Ophthalmol Update*. 2005; 6(1):11-21.
6. Yu-Wai-Man P, Griffiths PG. Steroids for traumatic optic neuropathy. *The Cochrane Library*. 2013.
7. Saxena R, Singh D, Menon V. Controversies in neuro-ophthalmology: Steroid therapy for traumatic optic neuropathy. *Indian journal of ophthalmology*. 2014; 62(10):1028.
8. Carta A, Ferrigno L, Salvo M, Bianchi-Marzoli S, Boschi A, Carta F. Visual prognosis after indirect traumatic optic neuropathy. *J Neurol Neurosurg Psychiatry*. 2003; 74(2):246-8.
9. Levin LA, Beck RW, Joseph MP, Seiff S, Kraker R, International Optic Nerve Trauma Study Group. The treatment of traumatic optic neuropathy: the International Optic Nerve Trauma Study. *Ophthalmology*. 1999; 106(7):1268-77.
10. Hall ED. The neuroprotective pharmacology of methylprednisolone. *Journal of neurosurgery*. 1992; 76(1):13-22.
11. Bracken MB, Shepard MJ, Holford TR, Leo-Summers L, Aldrich EF, Fazl M, Fehlings M, Herr DL, Hitchon PW, Marshall LF, Nockels RP. Administration of methylprednisolone for 24 or 48 hours or tirilazad mesylate for 48 hours in the treatment of acute spinal cord injury: results of the Third National Acute Spinal Cord Injury Randomized Controlled Trial. *Jama*. 1997; 277(20):1597-604.
12. Spoor TC, Lensink DB, Wilkinson MJ, Hartel WC. Treatment of traumatic optic neuropathy with corticosteroids. *American Journal Of Ophthalmology*. 1990; 110(6):665-9.
13. Miller NR. The management of traumatic optic neuropathy. *Archives of Ophthalmology*. 1990; 108(8):1086-7.
14. Steinsapir KD, Goldberg RA. Traumatic optic neuropathy: a critical update. *Compr Ophthalmol Update*. 2005; 6(1):11-21.
15. CRASH Trial Collaborators. Final results of MRC CRASH, a randomised placebo-controlled trial of intravenous corticosteroid in adults with head injury—outcomes at 6 months. *The Lancet*. 2005; 365(9475):1957-9.
16. Steinsapir KD. Treatment of traumatic optic neuropathy with high-dose corticosteroid. *Journal of neuro-ophthalmology*. 2006; 26(1):65-7.
17. Sauerland S, Nagelschmidt M, Mallmann P, Neugebauer EA. Risks and benefits of preoperative high dose methylprednisolone in surgical patients. *Drug Safety*. 2000; 23(5):449-61.
18. Beck RW, Cleary PA, Anderson Jr MM, Keltner JL, Shults WT, Kaufman DI, Buckley EG, Corbett JJ, Kupersmith MJ, Miller NR, Savino PJ. A randomized, controlled trial of corticosteroids in the treatment of acute optic neuritis. *New England Journal of Medicine*. 1992; 326(9):581-8.
19. Chou PI, Sadun AA, Chen YC, Su WY, Lin SZ, Lee CC. Clinical experiences in the management of traumatic optic neuropathy. *Neuro-ophthalmology*. 1996; 16(6):325-36.
20. Cook MW, Levin LA, Joseph MP, Pinczower EF. Traumatic optic neuropathy: a meta-analysis. *Archives of Otolaryngology-Head & Neck Surgery*. 1996; 122(4):389-92.
21. Lee KF, Nor NI, Yaakub A, Hitam WH. Traumatic optic neuropathy: a review of 24 patients. *International Journal Of Ophthalmology*. 2010; 3(2):175.
22. Seiff SR. High dose corticosteroids for treatment of vision loss due to indirect injury to the optic nerve. *Ophthalmic Surgery, Lasers and Imaging Retina*. 1990; 21(6):389-95.
23. Rajiniganth MG, Gupta AK, Gupta A, Bapuraj JR. Traumatic optic neuropathy: visual outcome following combined therapy protocol. *Archives of Otolaryngology-Head & Neck Surgery*. 2003; 129(11):1203-6.
24. Kumaran AM, Sundar G, Chye LT. Traumatic optic neuropathy: a review. *Craniofacial Trauma and Reconstruction*. 2015; 8(01):031-41.

**Cite This Article as:** Valerie M, Ugam U, Ramona M. Visual Outcome In Patients of Indirect Traumatic Optic Neuropathy Treated with Steroids.

**Acknowledgments:** Nil

**Conflict of interest:** None declared

**Source of Funding:** None

**Date of Submission:** 22 April 2019

**Date of Acceptance:** 11 December 2019

### Address for correspondence


**Menezes Valerie MS**

Siddarth Apartments - 2/S-2,

Tonca, P.O Caranzalem - 403002, Goa

India

Email id: vlm1142@gmail.com



Quick Response Code