

Optic Nerve Head Parameters and Macular Thickness Analysis by Optical Coherence Tomography in Presenile Patients After Cataract Surgery

Nasima Sultana¹, Sultana Jesmin Ahmed², Kamal Hasan³, Mir Alam Siddique³, Sheema Baqtiyar⁴, Md Yamin Hassan⁵

¹Department of Physiology, Gauhati Medical College, Guwahati, Assam, India

²Department of Community Medicine, Assam Medical College, Dibrugarh, Assam, India

³Regional Institute of Ophthalmology, Gauhati Medical College, Guwahati, Assam, India

⁴Shadan College of Pharmacy, Peerancheru, Hyderabad, Telangana, India

⁵Assam Down Town University, Panikhaiti, Guwahati, Assam, India

Purpose: This study aimed to investigate whether cataract surgery has got any effect on measurements of optic nerve head (ONH) parameters and central macular thickness (CMT) using optical coherence tomography (OCT) in presenile patients.

Methods: This study consisted of 18 women and 14 men aged 40-55 years having immature cataract with no previous history of ocular surgery, trauma, eye diseases, and ocular laser procedures. All patients underwent phacoemulsification surgery. Macular thickness and ONH analysis was performed by means of six radial scans centred on the optic disc (fast optic disc acquisition protocol). ONH parameters included rim area, cup area, disc area, cup/disc area ratio, and disc diameter. OCT measurements of operated eyes were done preoperatively, on postoperative day one, day 14, 6 weeks and 24 weeks after surgery using FMT and ONH protocol of OCT. SPSS v 15 (SPSS Inc, Chicago, IL, USA) software was used for the statistical analysis. FMT and ONH parameters were compared with the help of paired sample *t* – test.

Abstract

Results: The macular thickness after phacoemulsification (PHACO) was highest at 6 weeks with a mean value of $221.06 \pm 24.36 \mu\text{m}$. This resolved to near normal value at 24 weeks with mean thickness of $195.73 \pm 21.62 \mu\text{m}$. While analyzing ONH parameters, rim area was $1.50 \pm 0.38 \text{ mm}^2$ preoperatively which increased significantly in 2nd week (1.67 ± 0.42 , $p < 0.05$), 6th week (1.60 ± 0.44 , $p < 0.005$) and 24th week (1.57 ± 0.43 , $p < 0.005$). Cup area decreased significantly during the 2nd postoperative week ($1.17 \pm 0.44 \text{ mm}^2$, $p < 0.005$), 6th week ($1.32 \pm 0.45 \text{ mm}^2$, $p < 0.005$) and 24th week ($1.31 \pm 0.45 \text{ mm}^2$, $p < 0.005$) in comparison to preoperative value ($1.53 \pm 0.60 \text{ mm}^2$, $p < 0.005$). There was significant reduction of cup/disc area ratio after the cataract surgery during the 2nd week (0.40 ± 0.14 , $p < 0.005$), 6th week (0.46 ± 0.15 , $p < 0.005$) and 24th week (0.47 ± 0.15 , $p < 0.005$) in comparison to the cup/disc area ratio prior to surgery (0.49 ± 0.14). There was no statistically significant change in the disc diameter and disc area.

Conclusions: Phacoemulsification surgery in presenile cataract causes progressive increase in macular thickness till 6th week which get resolved towards 24 weeks. It causes significant ONH changes with increase in the rim area, reduction in cup area and cup disc area ratio.

Delhi J Ophthalmol 2020;30:48-51; Doi <http://dx.doi.org/10.7869/djo.545>

Keywords: Senile cataract, optic nerve head, optical coherence tomography, macular thickness.

Introduction

Cataract means clouding of the human crystalline lens of the eye which prevents clear vision. Generally most cases of cataract are related to the ageing process. A cataract may also develop due to eye injuries, inflammation and some other eye diseases. It may be congenital as well.

Cataract is the major cause of avoidable blindness worldwide.^{1,2,3} An estimated 45 million people worldwide are suffering from cataract related blindness. Approximately 135 million people are visually disabled and about 80% of blindness is avoidable. Nine out of ten people with blindness live in a developing country.⁴ Cataract was found to be the leading cause of blindness (39%) followed by retinal diseases (24%) according to the Malaysian National Eye Survey in the year of 1996.⁵

Surgery is the only treatment of cataract. Frequent procedures for cataract surgery are manual small incision cataract surgery (SICS) and phacoemulsification (PHACO). After the procedure of cataract surgery there might be changes in the macular thickness and optic nerve head thickness, which may have deleterious effect on visual outcome. Cystoid macular edema (CME) is an important problem after cataract surgery.⁶ Published reports show that CME occurs in about 2% of healthy population after uneventful cataract surgery.⁷ Cystoid macular edema can be diagnosed easily by using optical coherence tomography (OCT). It is an instrument which uses the principles of low-coherence interferometry to obtain high resolution, cross-sectional images of the human retina and ONH. The light source of the OCT is a short coherence length super luminescent diode in a near-infrared

wavelength (840 nm).

Optical coherence tomography is useful in establishing the diagnosis and monitoring response to therapy in various retinal diseases. OCT is a noncontact, non-invasive, easily reproducible method which uses only light.

OCT is capable of scanning the peripapillary retina, ONH and macular region. The peripapillary scan is a continuous circular scan centred on the ONH with a default diameter of 3.4 mm. Macular and ONH scans are composed of six radial scans in a spoke-like pattern centred on the ONH or the fovea at 30° intervals. Interpolation is used to fill the gaps between the scans. For macular scans, the vitreoretinal interface and the retinal pigment epithelium are utilised to define the inner and outer retinal boundaries, respectively. For ONH scans, the disc margin is defined as the end of the retinal pigment epithelium and choriocapillaries layer. Structures below this line are defined as the disc cup and over this line as the neuroretinal rim.

Effect of cataract surgery on ONH and macular thickness causing their alteration has been shown in a few published reports. But all of these studies have their limitations because all these studies analyzed only senile immature cataracts or nuclear sclerotic cataracts. None of these studies included presenile cataract as these forms of cataracts are rarely found in developed countries.

However, presenile cataracts are not uncommon in third world countries and more prevalent in India.

This study investigates the effect of cataract surgery on macular and ONH thickness in presenile patients of age group 40-55 years. To the best of our knowledge this is the first study on presenile cataract to analyze ONH parameters.

Materials and Methods

It was a hospital based study approved by Ethics Committee of Gauhati Medical College Hospital, Guwahati, and complied with the tenets of the Declaration of Helsinki. Before being included in the study a written informed consent was obtained from all participants. This randomized control study was conducted in Regional Institute of Ophthalmology, Gauhati Medical College and Hospital, Guwahati and OCT findings were obtained from 32 adults of 45-55 years age group with age related cataract presented to our hospital with complaint of poor vision.

Patients having any systemic disease, other ocular diseases, ocular trauma, history of previous ocular surgery, ocular laser procedures and patients with age below 40 years and above 55 years were excluded from the study.

Few studies have been reported in this field in senile cataract. However, there is no literature on ONH parameter analysis following cataract surgery in presenile cataract. This type of cataract is rarely observed in western world. That is why, we have taken this research work exclusively in presenile cataract which is very much prevalent in India.

All selected patients were planned for cataract surgery with hydrophobic foldable IOL implantation (AcrySof® IQ Monofocal IOL, Alcon) and were recruited to participate in the study. All cases of this study underwent phacoemulsification procedure. Tapering dose of steroid drops were used post operatively for six weeks and nepafenac eye drop for three

months.

Macular OCT was performed for measuring the central macular thickness (CMT) on all subjects using Stratus OCT (Carl Zeiss Meditec) prior to surgery and postoperatively on day one, day 14, 6 weeks and 24 week after surgery. The macular thickness, ONH parameters including rim area, cup area, disc area, cup/disc ratio, and disc diameter were recorded for all patients. Measurements were repeated until a good quality scan with high signal strength was obtained. All scans were acquired by the same examiner. The OCT scans of signal strength below five were excluded from the study. Scan with good signal strength were selected from the three scan of each eye.

SPSS version 15 (SPSS Inc, Chicago, IL, USA) software was used for the statistical analysis. CMT and ONH parameters were compared with the help of paired sample t-test.

Results

The study group consisted of 32 eyes (22 right eyes; 10 left eyes) of 32 patients (14 males; 18 females) whose average age was 49.31±4.81 years. The CMT increased after cataract surgery and was found to be highest at 6 weeks, with a mean average value of 221.6±24.36µm which is significant (p=0.005) when compared with the preoperative value (199.6±27.22 µm). It resolved to near normal at 24 weeks with an average thickness of 195.73±21.62µm (Figure 1).

While analyzing ONH parameters, rim area was found to be increased significantly during the postoperative weeks with a maximum at 2nd week (1.67±0.42mm²) in comparison to the preoperative value (1.50 ± 0.38 mm²) (Figure 2) (Table 1). The optic disc cup area decreased significantly during the postoperative period with a maximum reduction at 2nd week (1.17±0.44 mm²) in comparison to preoperative value (Figure 2) (Table 1).

There was significant reduction of cup/disc area ratio after the cataract surgery with a maximum decrease at 2nd week (0.40±0.14) in comparison to the cup/disc area ratio prior to surgery (0.49±0.14) (Figure 2) (Table 1).

There was also alteration in the disc diameter and disc area post-operatively, but it was not statistically significant (Figure 2) (Table 1).

Table 1: Showing ONH parameters on preoperative day, 1st post-operative day, 2nd week, 6 weeks, 12 weeks and 24 weeks after surgery.

Scanned area	Preoperative value	First postoperative day	2nd week	6th week	24th week
Rim area (mm ²)	1.50±0.38	1.50±0.39*	1.67±0.42*	1.60±0.44*	1.57±0.43*
Cup area (mm ²)	1.53±0.60	1.47±0.57**	1.17±0.44*	1.32±0.45*	1.31±0.45*
Disc area (mm ²)	2.98±0.49	2.96±0.48 [†]	2.96±0.60 [†]	2.86±0.41 [†]	2.75±0.37 [†]
Cup disc area ratio	0.49±0.14	0.48±0.15*	0.40±0.14*	0.46±0.15*	0.47±0.15*
Disc diameter (mm)	2.06±0.46	2.08±0.47 [†]	2.06±0.44 [†]	2.02±0.41 [†]	2.02±0.46 [†]

*p<0.005; **p<0.001 [†]Not significant

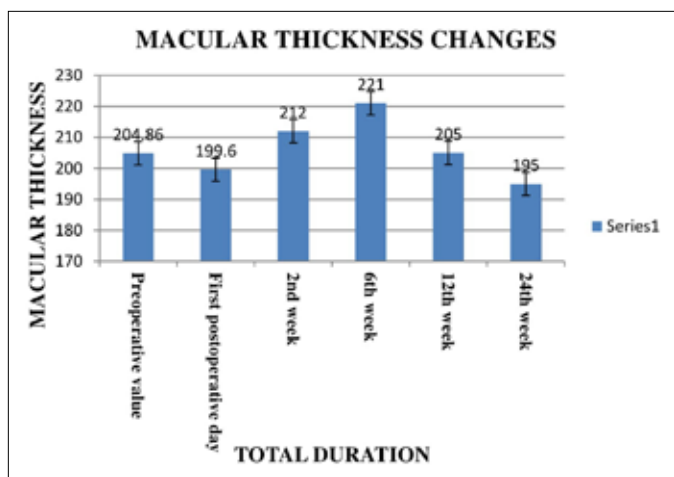


Figure 1: Changes of macular thickness on preoperative day, 1st post-operative day, 2nd week, 6 weeks, 12 weeks and 24 weeks after phacoemulsification surgery.

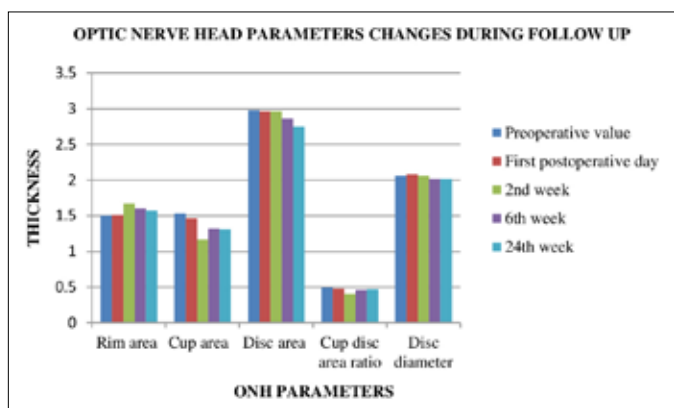


Figure 2: Changes of ONH parameters on preoperative day, 1st post-operative day, 2nd week, 6 weeks, 12 weeks and 24 weeks after surgery.

Discussion

Cystoid macular oedema (CMO) is one of the major causes of poor vision post cataract surgery. Although there are numerous studies evaluating the risk CMO in senile cataract, there is paucity of literature regarding the same in cases of pre-senile cataract undergoing cataract surgery. In developed countries presenile cataract is a rare entity, but this form of cataract is very commonly found in third world countries. In India, it is not uncommon in patients of age group 40-55years. In this study, we intended to evaluate the CMT and ONH changes in cases with presenile cataract undergoing phacoemulsification. It is well known that OCT plays an important role for diagnosing alterations in macular thickness and ONH parameters as this procedure is precise, accurate, reproducible and repeatable.^{9,10,11,12,13}

We found a significant increase in the rim area after phacoemulsification procedure. There was a significant decrease in the cup area and cup-disc ratio postoperatively. Our study results correspond to the results obtained by Lee KS et al in cases of senile cataract.⁸ There is no literature to explain these changes. Nevertheless, it may be due to factors related to the alteration in the signal strength during the OCT procedure in the two different situations (cataract

versus pseudophakia). The presence of cataract causes light scattering on OCT acquisition, which produces distortion that affect the OCT quality and measurements. We did not compare different signal strengths in this study. Our study was limited to comparison of ONH and CMT parameters of post cataract surgery presenile patients with progression of time, taking the preoperative ONH and CMT parameters as control.

Ghosh S et al. studied on 224 patients with senile cataract and found an increase in retinal central subfield mean thickness following cataract surgery.¹⁴ Jha B et al. found that there is a significant increase in the disc area ($P = 0.004$) and rim area ($P = 0.004$) but no significant change in vertical cup-disc ratio ($P = 0.45$) or average cup-disc ratio ($P = 0.075$).¹⁵ Our study reports show similar results except that the decrease in the cup disc ratio was significant in our study, whereas it was insignificant in the study by Jha B et al. There may be various reasons for this difference. One of those is that, their study was in senile cataract, whereas our study was in presenile cataract. The OCT signal strength may be different in presenile cataract, which is usually softer in comparison to the relatively harder nucleus of senile cataract. Our study did not compare the postoperative parameters between presenile and senile cataract. It was focused on the postoperative effects in presenile patients.

Biro Z et al. found no significant increases in retinal or foveal thickness on the day after surgery. However, 30 days after the procedure there was increase in foveal thickness which was found to be significant.¹⁶

In this study, we observed that the macular thickness and ONH parameters get altered postoperatively. Though these resultant alterations are trivial, it may have tremendous impact on the cataract management protocol. Our research work on evaluation of macular thickness and ONH parameters following cataract surgery in presenile patients has given new insight in this area.

There are a few limitations in this study including a small sample size. Also, we did not study the relationship of different stages of cataract and its severity to the changes in macular thickness and ONH parameters.

Conclusions

This research work reveals that surgery on cataract of presenile patients affects the ONH parameters and macular thickness postoperatively. Macular thickness increases during the early postoperative period reaching its peak at 6th post operative week which resolve gradually reaching near normal at 24th week. As per the ONH changes, the rim area get increased, cup area gets decreased and cup-disc area ratio gets decreased though the disc diameter does not alter significantly.

A further study taking higher number of patients, with study of the optic nerve head parameters and macular thickness to evaluate its relationship to different stages of cataract and its severity in presenile patients will be more informative. Invention of an advanced imaging technology which can give equal result in both opaque and transparent media will be helpful in such studies for precise comments.

References

1. Neena J, Rachel J, Praveen V, Murthy GV. Rapid Assessment of Avoidable Blindness India Study Group. Rapid Assessment of Avoidable Blindness in India. *PLoSOne*, 2008; 3:e2867.
2. Casson RJ, Newland HS, Muecke J, et al. Prevalence and causes of visual impairment in rural Myanmar: The Meiktila Eye Study. *Ophthalmology*, 2007; 114:2302-8.
3. Sapkota YD, Sunuwar M, Naito T, Akura J, Adhikari HK. The prevalence of blindness and cataract surgery in Rautahat district, Nepal. *Ophthalmic Epidemiol*, 2010; 17:82-9.
4. Bjorn T. The global initiative for the elimination of avoidable blindness. *Community Eye Health Journal*, 1998; 11:1-3.
5. Zainal M, Ismail SM, Ropilah AR et al. Prevalence of blindness and low vision in Malaysian population. Results from National Eye Survey 1996. *Br J Ophthalmol*, 2002; 86:951-6.
6. Ray S, D'Amico DJ. Pseudophacic cystoid macular edema. *Semin Ophthalmol*, 2002; 17:167-180.
7. Von Jagow B, Ohrloff C, Kohnen T. Macular thickness after uneventful cataract surgery determined by optical coherence tomography. *Graefes Arch Clin Exp Ophthalmol*, 2007; 245:1765-1771.
8. Lee KS, Kim YM, Kim JH, et al. Changes in optic nerve parameter measurements on spectral-domain optical coherence tomography, after cataract surgery. *J Korean Ophthalmol Soc*, 2013; 54:1573-80.
9. MassinP, VicautE, Haouchine B, Erginay A et al. Reproducibility of retinal mapping using optical coherence tomography. *Arch Ophthalmol*, 2001; 119:1135-42.
10. Schuman J, Pedut-Kloizman T, HertzmarkE, et al. Reproducibility of nerve fiber layer thickness measurement using optical coherence tomography. *Ophthalmology*, 1996; 103:1889-98.
11. Muscat S, Parks S, Kemp E, Keating D. Repeatability and reproducibility of macular thickness measurements with Humphrey OCT system. *Invest Ophthalmol Vis Sci*, 2002; 43:490-95.
12. Koozekanani D, Roberts C, Katz SE, Herderick EE. Intersession repeatability of macular thickness measurements with the Humphrey 2000 OCT. *Invest Ophthalmol Vis Sci*, 2000; 41:1486-91.
13. Hee MR, Puliafito CA, Wong C, et al. Quantitative assessment of macular edema with optical coherence tomography. *Arch Ophthalmol*, 1995; 113:1019-29.
14. Ghosh S, Roy I, Biswas PN, et al. Prospective randomized comparative study of macular thickness following phacoemulsification and manual small incision cataract surgery. *Acta Ophthalmol*, 2010; 88(4): 102-6.
15. Jha B, Sharma R, Vanathi M, et al. Effect of phacoemulsification on measurement of retinal nerve fiber layer and optic nerve head parameters using spectral-domain-optical coherence tomography. *Oman J Ophthalmol*, 2017; 102: 91-95.
16. Biro Z, Balla Z, Kovacs B. Change of foveal and perifoveal thickness measured by OCT after phacoemulsification and IOL implantation. *Eye*, 2008; 22:8-12.

Cite This Article as: Sultana N, Ahmed SJ, Hasan K, Siddique MA, Baqiyar S, Hassan MY. Optic Nerve Head Parameters and Macular Thickness Analysis by Optical Coherence Tomography in Presenile Patients After Cataract Surgery.

Acknowledgments: Nil

Conflict of interest: None declared

Source of Funding: None

Date of Submission: 29 October 2019

Date of Acceptance: 9 December 2019

Address for correspondence

Mir Alam Siddique MBBS, MS, Ph.D
Department of Ophthalmology,
Gauhati Medical College,
Guwahati, Assam, India
Email id: mir.siddiqui@gmail.com



Quick Response Code