

Retrospective Analysis of Risk factors in Aggressive Posterior Retinopathy of Prematurity (APROP)

Srijita Mitra,¹ Sahil Sarpal,¹ Abhijit Chattopadhyay,² Subhankarsri Paul,² Jonaki Ghosh Roy²

¹ Sarpal Eye Hospital, Amritsar, Punjab, India

²Department of Retina and Uvea Services, Priyamvada Birla Aravind Eye Hospital, West Bengal, India

Abstract

This is a retrospective, observational study to analyse the risk factors contributing in the pathogenesis of Aggressive Posterior retinopathy of prematurity (AP-ROP). Case record of 30 babies were analysed. All these babies had received supplemental oxygen for 2 days or longer after birth and had several other systemic co-morbidities. The mean gestational age was 30.3+/-3.03 weeks and mean birth weight was 1.27+/- 0.283 kgs. Examination revealed 35 eyes (61.4%) had zone II posterior AP-ROP and 22 eyes (38.5%) had zone I APROP.

Delhi J Ophthalmol 2020;31;23-25; Doi <http://dx.doi.org/10.7869/djo.562>

Keywords: APROP, Risk Factors, Eastern India Population, Low Birth Weight, Prematurity.

Introduction

Aggressive Posterior Retinopathy of Prematurity (APROP) is characterised by¹ increased dilation and tortuosity of the posterior pole vessels (prominence of plus disease) in all quadrants, flat network of shunts within retina or at the junction between vascular and avascular retina in Zone I or Zone II Posterior. It is an uncommon form of ROP usually seen in the smallest, most premature babies.²

Objective

This is a retrospective, observational analysis reporting the spectrum of risk factors for APROP in Eastern India subset of population referred to our tertiary eye care centre. We have included all newly diagnosed consecutive cases of APROP and excluded any treated cases of APROP from elsewhere or cases of suspected APROP.

Material & Methods

APROP was diagnosed in accordance to ETROP. Records of 30 babies and 57 eyes (3 babies had milder, resolving ROP in the other eye) were taken from January 2015- June 2016 with a follow up period till 2 years of age for each baby. Findings of 57 eyes were taken into account. Tabulated parameters included birth weight, gestational age, post conceptual age, associated illness and duration of oxygen supplementation.

Results

In our analysis, we found that 6 babies were under 1000g of birth weight, 19 babies between 1000-1500g and 5 babies over 1500g, accounting for a mean birth weight of 1270g, sd=283.23 (Figure 1). There were 3 babies with gestational age of less than 28 weeks, 14 babies between 28- 30 weeks and 13 babies between 31 to 36 weeks of gestation; resulting mean GA of 30.3 weeks, sd=3.032.

Post menstrual age (time of presentation) of 9 babies was at less than 34 weeks and 21 babies presented at over 34 weeks of PMA. Corroborating with treatment history, we found that all babies had received supplemental oxygen for

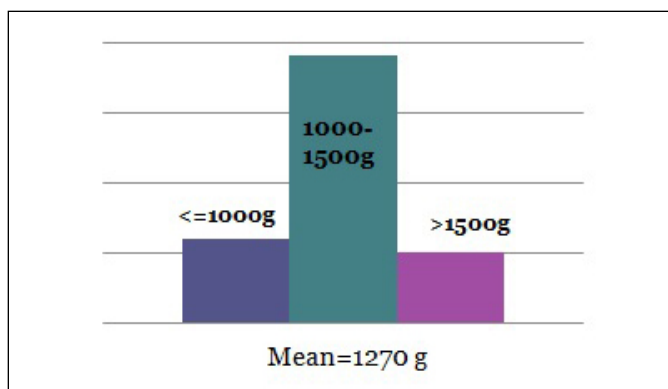


Figure 1: Distribution of Birth weight

duration ranging 2 to 15 days. Ventilatory support received by 15 babies for duration between 3 to 22 days; phototherapy was received by 11 babies.

Taking co-morbidities into account, Sepsis was found in 8 babies (26.6%), neonatal jaundice in 11 (36.6%), Respiratory distress syndrome in 18 (60%), patent ductus arteriosus in 1 baby (0.03%), Twin delivery in 8 babies (26.6%) and necrotising enterocolitis in 3 babies (0.1%). (Table 1)

According to the location of APROP, 35 eyes had Zone II APROP (61.4%) and 22 eyes had Zone I APROP (38.5%) (Figure 2). Out of 30 babies, 22 received treatment (8 babies were lost to follow up); 5 babies received intravitreal Bevacizumab and laser therapy, 5 received laser therapy alone and 12 received intravitreal Bevacizumab monotherapy. Rationale for treatment being Zone I APROP suitable for intravitreal Anti- VEGF and Zone II APROP suitable for laser treatment. After the initial treatment, if the plus disease/ vessel tortuosity decreased, haemorrhages spontaneously resolved and further vascularisation of the retina occurred, within a span of 7-10 days, then baby was followed up or else treatment was augmented. In babies who received intravitreal injection and signs improved,

Table 1: Systemic co-morbidities

Systemic co-morbidities	No. Babies (n=30)	Percentage (%)
Sepsis	8	26.6
Neonatal Jaundice	11	36.6
Respiratory distress Syndrome	18	60
Patent ductus arteriosus	1	0.03
Twin delivery	8	26.6
Necrotising enterocolitis	3	0.1

supplemental laser was given. One baby had to undergo surgery after having developed tractional retinal detachment despite combination therapy. Almost 60% of the treated eyes developed high myopia as sequelae as observed during the follow up period.

Discussion

Lower gestational age (GA) and birth weight (BW) have been shown as the main risk factors for the development of APROP. In our study, very low birth weight babies (1000g-1500g) and gestational age ranging 28 to 36 weeks (Mean- 30.2+/- 1.98 weeks) showed the highest incidence of APROP. This is in contrast to various studies from outside India which describe APROP in infants <30 weeks of gestational age and <1000g birth weight.³ However, recent studies from India report APROP in older and heavier infants.^{4,5} 61.4% cases presented with Zone II P APROP which is comparable to the study by Sanghi et al.⁶

Respiratory distress syndrome accounted for 60% of co-morbidities followed by neonatal jaundice (36.6%) and sepsis (26.6%). Hungi et al.⁷ Identified RDS, sepsis, neonatal jaundice and oxygen therapy as risk factors for the development of severe ROP in greater preterms. Presence of several other co morbidities in preterm neonates including, Patent Ductus Arteriosus (1 case), Necrotising Enterocolitis (3 cases),

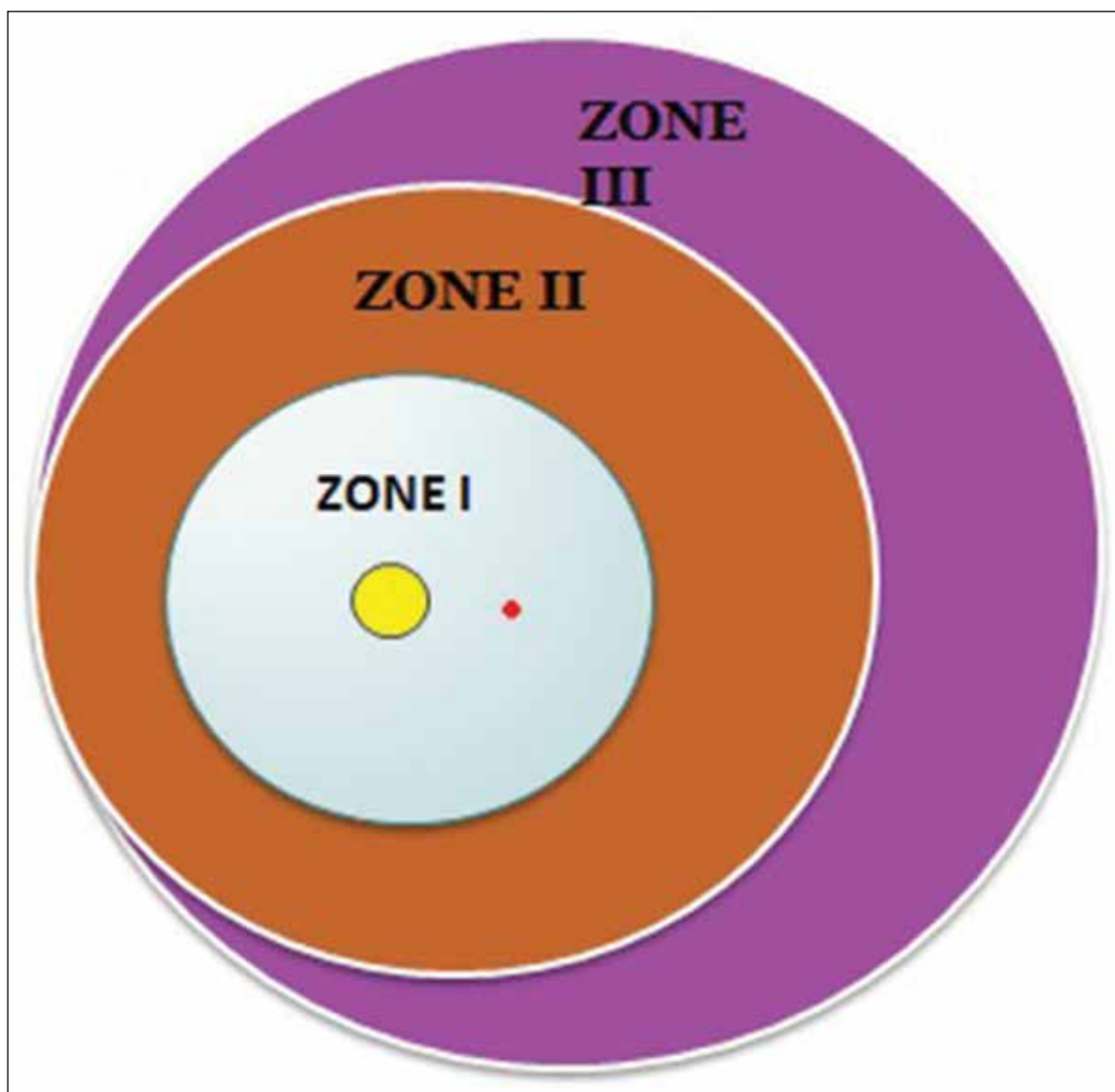


Figure 2: Distribution of zones

Ventilator dependence (50% cases), prolonged unblended oxygen supplementation (76.6%) twin delivery (26.6%) are comparable to studies by Yang et al.⁸ Thrombocytopenia, anemia, necrotizing enterocolitis, bronchopulmonary dysplasia (BPD) and intraventricular hemorrhage (IVH) are also known to contribute to development of severe ROP.⁹ Strength of this analysis is that it is one of the few studies on specifically APROP and the fact that no pretreated eyes were included in the analysis. Pitfalls being the retrospective nature of the analysis. Further light needs to be shed on this subject from a prospective viewpoint; hence, apart from the ones discussed, other unknown risk factors are yet to be evaluated.

Conclusion

As per our study, very low birth weight babies (1000-1500g), mean gestational age of 32 weeks and respiratory distress syndrome account for the highest incidence of APROP in our region. The ophthalmological care of the ROP infant should be undertaken in the wider context of neonatal care and general wellbeing of the infant with the ophthalmologist, neonatologist and epidemiologist all having an active role to play.

References

1. International Committee for Classification of Retinopathy of Prematurity.
2. Azad R, Trese MT. Textbook of Retinopathy of Prematurity, 2011; 47-48.
3. Drenser KA, Trese MT, Capone A., Jr Aggressive posterior retinopathy of prematurity. *Retina*, 2010; 30:S37-40.
4. Shah PK, Narendran V, Kalpana N. Aggressive posterior retinopathy of prematurity in large preterm babies in South India. *Arch Dis Child Fetal Neonatal Ed*, 2012; 97:F371-5.
5. Jalali S, Kesarwani S, Hussain A. Outcomes of a protocol-based management for zone 1 retinopathy of prematurity: The Indian Twin Cities ROP screening program report number. *Am J Ophthalmol*, 2011; 151:719-24.
6. Sanghi G, Dogra MR, Katoch D, Gupta A. Aggressive posterior retinopathy of prematurity in infants ≥ 1500 g birth weight. *Indian J Ophthalmology*, 2014; 62(2):254-257.
7. Hungi B, Vinekar A, Datti N, Kariyappa P, Braganza S, Chinnaiiah S, et al. Retinopathy of Prematurity in a rural Neonatal Intensive Care Unit in South India—a prospective study. *Indian J Pediatrics*, 2012.
8. Yang CY, Lien R, Yang PH, Chu SM, Hsu JF, Fu RH, et al. Analysis of incidence and risk factors of retinopathy of prematurity among very-low-birth-weight infants in North Taiwan. *Pediatr Neonatol*, 2011.
9. Jensen AK, Ying GS, Huang J, Karp K, Quinn GE, Binenbaum G. Thrombocytopenia and retinopathy of prematurity. *J AAPOS*, 2011; 15(1):e3-e4.

Cite This Article as: Mitra S, Sarpal S, Chattopadhyay A, Paul S, Roy JG. Retrospective Analysis of Risk factors in Aggressive Posterior Retinopathy of Prematurity (APROP). *Delhi J Ophthalmology* 2020, 31(1): 23-25.

Acknowledgments: Nil

Conflict of interest: None declared

Source of Funding: None


Date of Submission: 30 Aug 2019

Date of Acceptance: 26 Dec 2019

Address for correspondence

Srijita Mitra ms

Dr. Sarpal Eye Hospital,
1-A, Hukam Singh Road,
Gali No.5, Amritsar, Punjab, India
Email id: srijita.mitra01@gmail.com



Quick Response Code