

## Case Report

# Intraocular Gnathostomiasis: A rare Case Report of a Live Intravitreal Worm

Anuja Mohanty, Santosh Kumar Mahapatra

J.P.M. Rotary Eye Hospital and Research Institute, Cuttack, Odisha, India,

## Abstract

We report a rare case of intraocular gnathostomiasis from eastern India. A 32 year old male from Cuttack, Odisha presented to us with decreased vision in his left eye of counting fingers(CF) at 2 metres since 1 week without any pain, lid edema or periorbital swelling. Anterior segment was normal. Indirect ophthalmoscopy revealed a live motile worm in posterior vitreous cavity near macula. The worm was removed via pars plana vitrectomy. The removal was first attempted using flute needle but in vain and was finally done with end-grasping forceps. Microscopy revealed *Gnathostoma spinigerum*. The patient was treated with oral albendazole and steroids. The case is reported because of its rarity.

Delhi J Ophthalmol 2020;31;65-68; Doi <http://dx.doi.org/10.7869/djo.572>

**Keywords:** Intraocular gnathostomiasis, intravitreal, live worm, vitrectomy

## Introduction

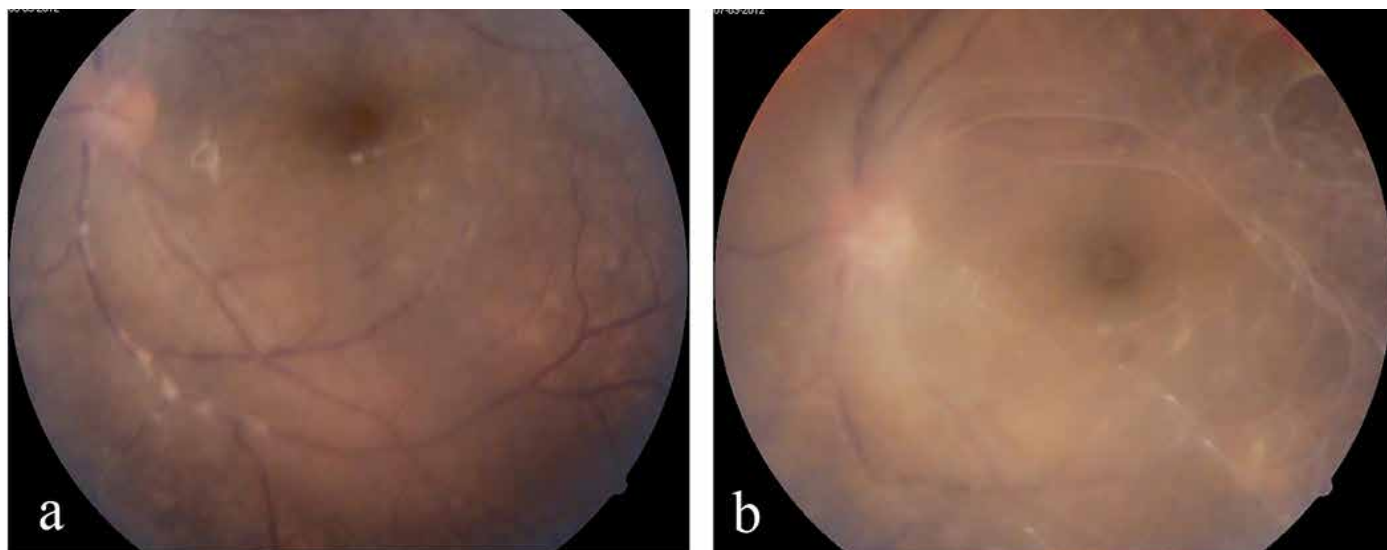
Intraocular gnathostomiasis is a rare parasitic infection caused by the third-stage larvae of spiruoid nematode *Gnathostoma* spp. seen mostly in tropical and subtropical regions. It is a food-borne zoonosis caused by ingestion of raw or undercooked freshwater fish, amphibians, reptiles, birds, and mammals. It involves the eyelids, conjunctiva, cornea, anterior chamber, uvea and vitreous cavity.<sup>1</sup> The first case of ocular gnathostomiasis was reported from India in 1945 by Sen et al.<sup>2</sup> We present one such case of intraocular gnathostomiasis in a 32 year-old male who presented with an actively motile worm in the vitreous cavity which was removed live and intact with vitreous forceps and studied microscopically for identification of the species.

Although *Baylisascaris procyonis*, *Gnathostoma spinigerum*, *Toxocara cati*, *T. canis*, *Acylostoma caninum*, *Strongyloides stercoralis*, *Ascaris lumbricoides*, and *T. solium* cysticerci can cause ocular larva migrans; *G. spinigerum* is more often associated with a unique unilateral form of ocular larva migrans, where an actively motile parasite can be seen more

often in the anterior and less frequently in the posterior segment of the eye. High endemicity has been reported in Thailand, Japan, and Mexico, where people have a custom of consuming raw fish dishes. Consumption of smoked and marinated fishes and crabs is also seen in eastern and northeastern parts of India, therefore most of the Indian cases have been reported from this region.<sup>3</sup>

## Case Report

A 32 year old male presented to our hospital with a complaint of gross diminution of vision since 1 week in his left eye. His vision was 6/9 and CF 2 meters in right eye and left eye respectively. Anterior segment was normal in both eyes. However, funduscopy of left eye revealed a live intravitreal worm near the optic disc along with surrounding fibrous proliferation and fine epimacular membrane. The worm was motile, however its motility was restricted due to surrounding fibrinous proliferation (Figure 1a,1b). There was no retinchoroidal or vitreous haemorrhage. The peripheral blood smear revealed mild eosinophilia and lymphocytosis



**Figure 1:** (1a) Left eye fundus showing live intravitreal worm near the optic disc with surrounding fibrinous proliferation and fine epimacular membrane. (1b) increased fibrinous reaction on the day of surgery restricting worm motility.

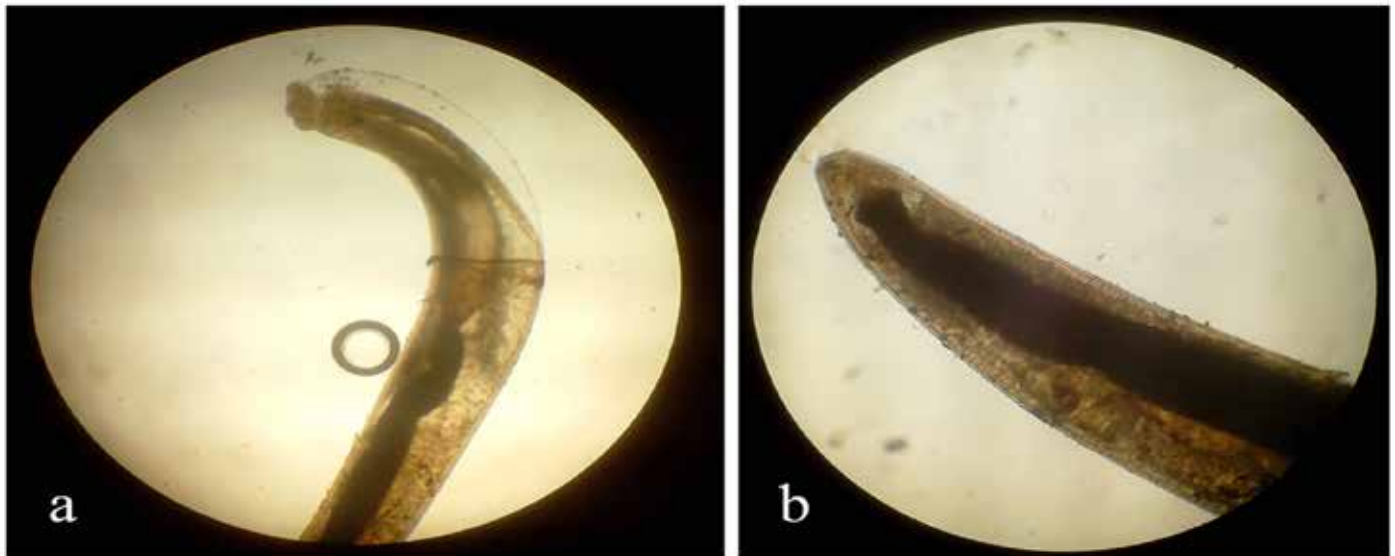
without any microfilaria. Stool and urine microscopic examination showed no abnormality, and no detectable microfilaria. Systemic examination showed no abnormality. No cutaneous lesion was detected. MRI of brain and orbits did not show any evidence of other parasitic infestation.

Oral steroids were started pre-operatively. Pars plana vitrectomy was planned to remove the worm intact and live to reduce the chance of ocular inflammation and aid identification of the worm. 20G vitrectomy was performed for easy removal of the worm. Core vitrectomy was done, PVD (posterior vitreous detachment) induced and vitreous around the worm was removed before approaching the worm with flute needle but the worm did not come to the port of the flute needle and was actively curling on itself. So some more vitrectomy was done before approaching the worm with flute needle which was again futile. Hence we decided to irritate the worm by applying laser around the

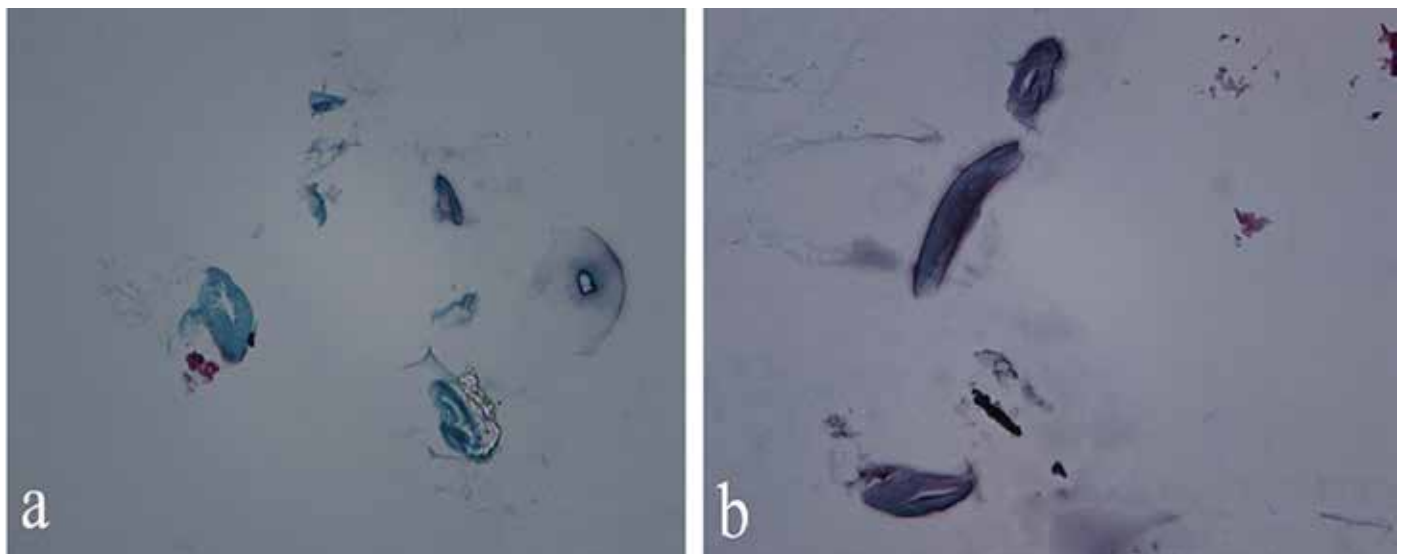
worm and again tried to suck the worm through the tip of the flute needle which was also not successful. Hence, finally we decided to pick the worm with end-grasping forceps though there was a chance of injuring the worm. The worm was grasped with utmost care not to damage it and finally we were successful to remove the worm live and intact with forceps.

The worm, measuring about 4.5 mm in length and 0.5 mm in diameter was alive and actively motile upon removal from the eye. On light microscopy, it was identified as a third stage larva of *Gnathostoma spinigerum* (Figure 2a,2b).

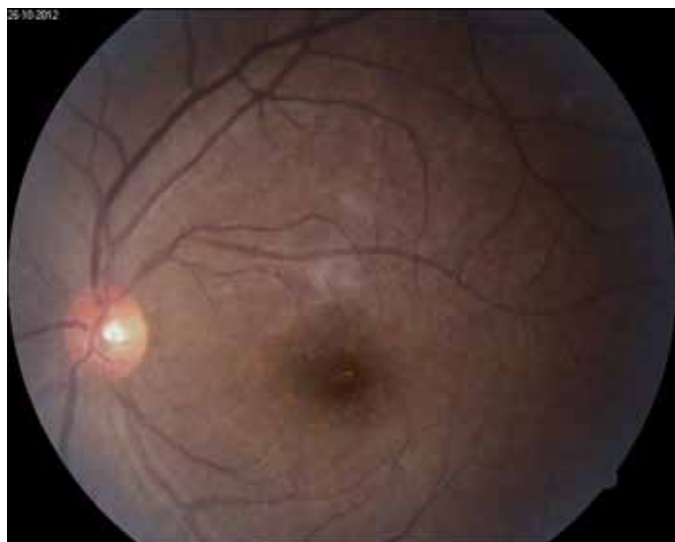
It was sent for histopathological study and the microscopic examination revealed cephalic bulb and presence of spines and hooklets on body surface typical of *Gnathostoma spinigerum* (Figure 3a,3b).



**Figure 2:** (a),(b): Light Microscopy showing 3rd Stage Larva of *Gnathostoma spinigerum*



**Figure 3:** (a,b) Histopathology examination showing cephalic bulb and presence of spines and hooklets typical of *G. spinigerum*. (Severed body parts due to tissue sections)



**Figure 4:** Left eye fundus at one month follow up

After removal of the worm by pars plana vitrectomy, the patient was treated with a course of oral parasitocidal (albendazole 400mg + ivermectin 6mg) twice daily for 3 weeks and systemic steroids. The posterior segment inflammation gradually subsided and his visual acuity improved to 6/18 two weeks following surgery. He had a good visual recovery and a clear fundus at one month follow-up with visual acuity of 6/9 in his left eye (Figure 4).

### Discussion

Of the 12 known species within the genus *Gnathostoma*, only 4 species infect humans: *G. nipponicum*, *G. hispidum*, *G. doloresi* and *G. spinigerum*. *G. spinigerum* is found in cats and dogs in south-east Asia, Japan, China and India.<sup>4</sup> Man gets infected with the third stage larva by consuming raw or undercooked meat of intermediate hosts like chickens, pigs, ducks, etc and becomes an accidental host. Third stage larvae cannot mature in humans, but they may remain alive up to 10 years. Humans can also become the second intermediate host through consumption of water contaminated with second-stage larvae. Another alternative route of infection is by penetration of the skin of food handlers by the third-stage larvae from infected meat.<sup>5</sup>

Cutaneous lesions like migratory panniculitis or serpiginous eruptions caused by the migration of the third-stage larvae are the most common manifestation of this infection.<sup>6</sup> Migration to other sites leads to visceral involvement of the lungs, gastrointestinal tract, genitourinary tract, ear, central nervous system, and eye; among which central nervous system infestation causes fatal eosinophilic myeloencephalitis,<sup>7</sup> whereas ocular involvement is rare.

The most common manifestation of intraocular gnathostomiasis is anterior uveitis and intraocular parasite<sup>8,3</sup> because it mostly localizes itself in the anterior segment of the eye. The other common manifestations are eyelid edema, conjunctival chemosis, hyphema, retinochoroidal and vitreous hemorrhage, and rarely, central retinal artery occlusion leading to blindness.<sup>9</sup> The portal of entry into the eye may

be posterior retina, because intraocular gnathostomiasis has been associated with macular scarring, rupture of nasal branch of central retinal artery, or retinal tear with choroidal hemorrhage near the optic disc.<sup>10</sup>

Clinical symptoms of gnathostomiasis are due to the inflammatory reaction provoked by migrating larvae. Peripheral blood smear may show eosinophilia. Due to the avascularity of the anterior chamber of the eye, eosinophilia which is the hallmark of parasitic infections is mostly absent and usually mild if at all present.<sup>8</sup> Moore et al. have suggested that it could be used as a marker of treatment response in patients with eosinophilia at baseline.<sup>5</sup> In the present case, there was no cutaneous manifestation and only mild eosinophilia.

### Conclusion

The patient discussed here was unique in the sense that he presented with live intravitreal worm without any signs of anterior segment inflammation. Once the parasite is identified in the vitreous cavity, it should be removed immediately, intact and live, as it is capable of migrating to various parts of the eye and could cause structural damage and severe intraocular reaction. In this situation, pars plana vitrectomy is indicated. It is not unusual for the parasite to be cut into parts during removal. A severed parasite may cause serious intraocular inflammation.<sup>11</sup> This rare case illustrates that intraocular *Gnathostoma spinigerum* can cause posterior segment inflammation without involvement of anterior segment. Removal of the intact parasite along with systemic steroid and oral parasiticidals can ensure restoration of vision.

With the increasing reports of intraocular gnathostomiasis from India, it has become imperative that the clinicians become familiar with this rare case scenario so that diagnosis is not missed or delayed, thus avoiding potentially serious complications.

### Financial Disclosure

This is to certify that the author(s) do not have any commercial association or financial interest in the publication of this manuscript.

Conflict of Interest: This is to certify that there is no conflict of interest regarding publication of this manuscript.

### References

1. Manson-Bahr PEC, Bell DR, Manson's Tropical Diseases. 9th ed, ELBS: Bailliere Tindall;1987: Appendix II, pp 1348-50.
2. Sen K, Ghose N. Ocular Gnathostomiasis. Br J Ophthalmol 1945;29:618-26.
3. Pillai GS, Kumar A, Radhakrishnan N, Maniyelil J, Shafi T, Dinesh KR, Karim S. Intraocular gnathostomiasis: report of a case and review of literature. Am J Trop Med Hyg. Apr 1, 2012; 86(4): 620-623.
4. Herman JS, Chiodini PL. Gnathostomiasis, another emerging imported disease. Clin Microbiol Rev 2009;22:484-492.
5. Daengsvang S. Gnathostomiasis in Southeast Asia. Southeast Asian J Trop Med Public Health. 1981;12:319-332.
6. Mc Carthy J, Moore TA. Emerging helminth zoonoses. Int J Parasitol. 2000;30:1351-1360.
7. Bunnag T, Comer DS, Punyagupta S. Eosinophilic myeloencephalitis caused by *Gnathostoma spinigerum*,

- Neuropathology of nine cases. *J Neurol Sci* 1970;10:419-34.
- 8 Kannan KA, Vasantha K, Venugopal M. Intraocular gnathostomiasis. *Indian J Ophthalmol.* 1999;47:252-253.
  - 9 Nawa Y, Katchanov J, Yoshikawa M, et al. Ocular Gnathostomiasis: A Comprehensive Review. *J Trop Med Parasitol.* 2010;33:77-86.
  - 10 Basak SK, Sinha TK, Bhattacharya D, Hazra TK, Parikh S. Intravitreal live Gnathostoma spinigerum. *Indian J Ophthalmol.* 2004;52(1):57-8.
  - 11 Tudor RC, Blair E. Gnathostoma spinigerum and unusual causes of ocular nematodiasis in the Western hemisphere. *Am J Ophthalmol* 1971;72:185-90.

**Cite This Article as:** Mohanty A, Mahapatra SK. Intraocular Gnathostomiasis: A rare case report of a live intravitreal worm. *Delhi J Ophthalmol* 2020;31(1), 65-68.

**Acknowledgments:** Nil

**Conflict of interest:** None declared

**Source of Funding:** None

**Date of Submission:** 10 January 2020

**Date of Acceptance:** 13 March 2020

### Address for correspondence

**Santosh Kumar Mahapatra, MS,**  
Chief Medical Officer  
JPM Rotary Eye Hospital & Research Institute,  
Sector-6, CDA, Cuttack, Odisha, India,  
E-mail: santu\_k74@rediffmail.com



Quick Response Code