

A Rare Case of Traumatic Superior Orbital Fissure Syndrome Following an Unusual Mode of Penetrating Injury

Narendra Patidar, Prerana Phadnis, Amit Mohan, Parimal Piush
Orbit and Oculoplasty, Sadguru Netra Chikitsalaya, Jankikund, Madhya Pradesh, India

Abstract

Traumatic superior orbital fissure syndrome (SOFS) is a rare presentation with a low incidence of <1% associated with severe morbidity and mortality. We report a case following an unusual mode of orbital penetrating injury with wire to an eight-year-old male child whose clinical features and CT scan findings were suggestive of SOFS. Surgical decompression with steroid therapy under antibiotic coverage showed excellent results with complete recovery after 2 ½ months without any complications till 1 year of follow up.

Delhi J Ophthalmol 2020;31;72-75; Doi <http://dx.doi.org/10.7869/djo.574>

Keywords: Traumatic superior orbital fissure syndrome.

Introduction

Superior orbital fissure syndrome (SOFS) is a rare complication of facial trauma characterized by proptosis, ptosis and complete ophthalmoplegia along with anaesthesia of cornea due to paralysis of 3rd, 4th, 6th cranial nerves and ophthalmic division of 5th cranial nerve. Pupil dilatation may occur in these cases due to damage to the parasympathetic pathway following trauma to the 3rd cranial nerve. Oedema and haemorrhage may follow concussion of the superior and inferior ophthalmic vein causing these symptoms.¹ Hirschfeld in 1858² first demonstrated a patient with clinical signs of SOFS but this entity was later described by Rochon-Duvigneaudin in 1896.³ Incidence of SOF syndrome is less than 1%⁴ and common aetiologies include 1) haematoma and neoplasms of the retrobulbar space, 2) infections of meninges, cavernous sinus, CNS and 3) trauma causing LeFort fractures II,III, and zygomatic complex fractures¹.

We report a rare case of SOFS following an unusual mode of penetrating orbital injury due to a minor trauma without any evidence of craniomaxillofacial fracture. Permission by the patient's parents to print identifiable photographs of their child was obtained and archived. The case described in this report is compliant with the Declaration of Helsinki and Health Insurance Portability and Accountability Act regulations.

Case Report

An eight-year-old male child came to our outpatient clinic with presenting complaints of left eye pain, swelling, redness, complete drooping of eyelid and protrusion of eyeball after accidentally getting hurt by a piece of wire while walking. (Figure 1a). On examination his BCVA was 6/6 in the left eye with echymosis, complete ptosis (MRD1 -3), superotemporal conjunctival tear, chemosis and haemorrhage, 3-4 mm sluggish reacting pupil, total




Figure 1: (a) On presentation




Figure 1: (b) Diplopia charting before discharge

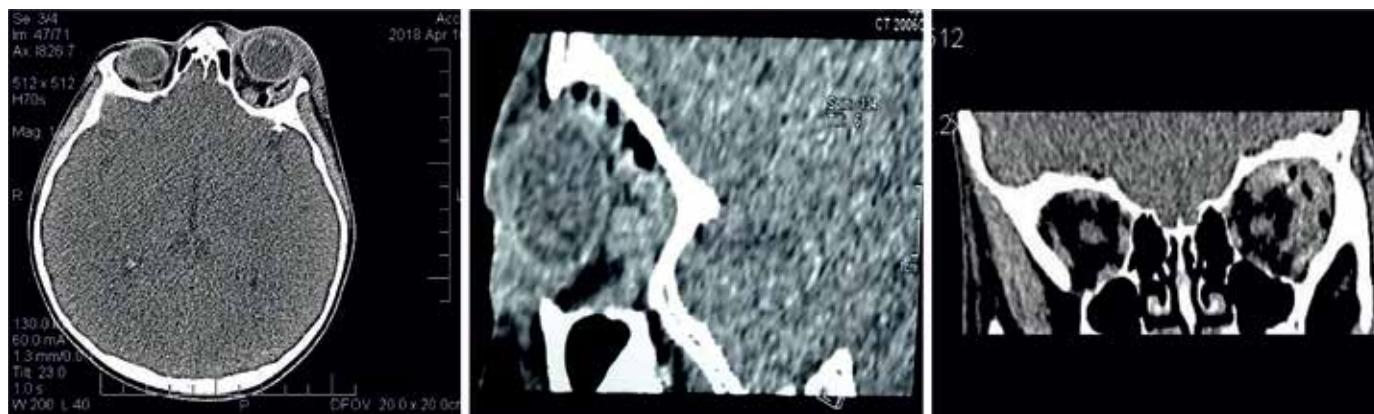

Figure 2: (a) CT scans axial, saggital, coronal views

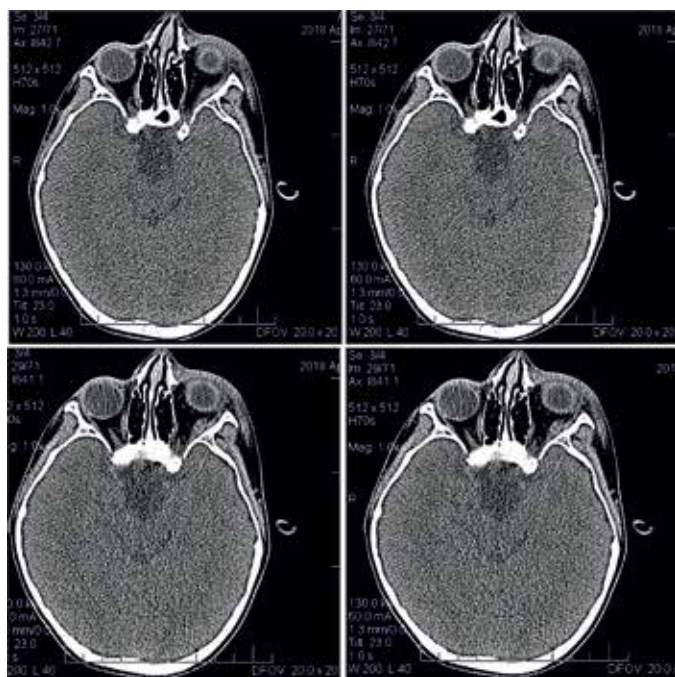


Figure 2: (b) CT scans at the level of superior orbital fissure

ophthalmoplegia with proptosis of 20 mm (OD 16 mm, base 95 by Hertel’s exophthalmometer). On elevating the eyelid, the child also complained of diplopia (Figure 1b). Corneal and ipsilateral forehead sensations were diminished. Globe was intact and rest ocular findings and IOP of both eyes were within normal limits. B-SCAN was normal with no retrobulbar haemorrhage. CT scan revealed oedema and haemorrhage with trapped air pockets in the preseptal space extending to the extraconal planes of superolateral orbit near the superior orbital fissure (Figure 2a, 2b). Diagnosis of traumatic SOFS of the left eye was made and planned for wound exploration with drainage of haemorrhage under general anaesthesia. During superior orbitotomy exploration, minimal haemorrhage (<0.5ml) was drained and conjunctival tear repair was done. Pulse IV methylprednisolone 25mg/kg OD for 3 days was started under antibiotic coverage. The patient was discharged on oral prednisolone 1 mg/kg per day after clinical improvement, tapering the dose every 7days and was followed up after 15 days, 1 month, 2.5 months and 1 year.




Figure 3: (a) follow up at 2.5months

Improvement in lid oedema and ptosis (MRD1 +1) was present on day 15 with minimal improvement in ocular movements and diplopia. Complete resolution of lid oedema, ptosis (MRD1 +3), significant improvement in ocular movements and diplopia, mild recovery of the ipsilateral forehead and corneal sensations was seen on a 1 month follow up. After 2.5 months, the patient showed full ocular movements with no diplopia, normal sensations and no ptosis (MRD1 +4) (Figure 3a,3b). No complications were noted until 1 year follow up.

Discussion

Traumatic SOFS is a rare phenomenon with a very low incidence, usually occurring after severe injuries of the face involving fractures of LeFort II, III and zygomatic-maxillary complex with impingement of the bony fragments.^{5,6} It may also occur following an increase in intraorbital pressure causing compression of the nerves against the bony margin of the superior orbital fissure due to retrobulbar haematoma, inflammation, oedema with recovery depending upon the

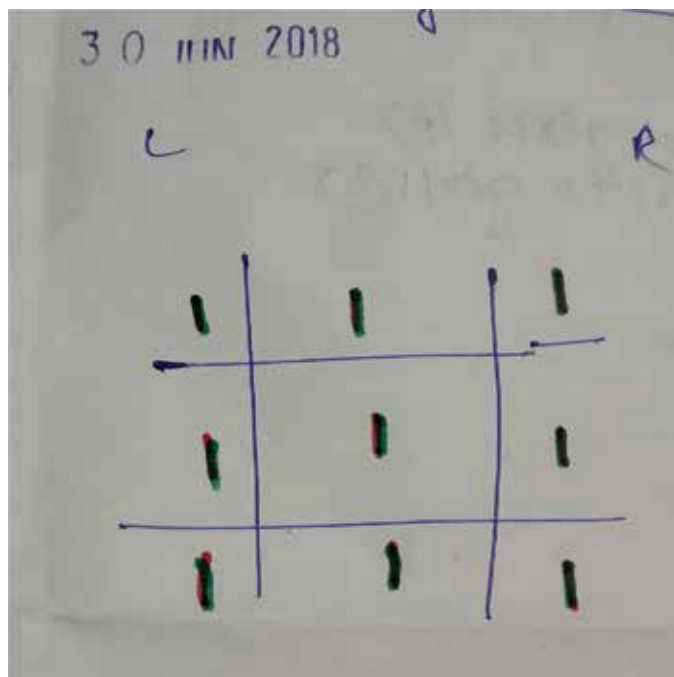


Figure 3: (b) Diplopia charting on Followup

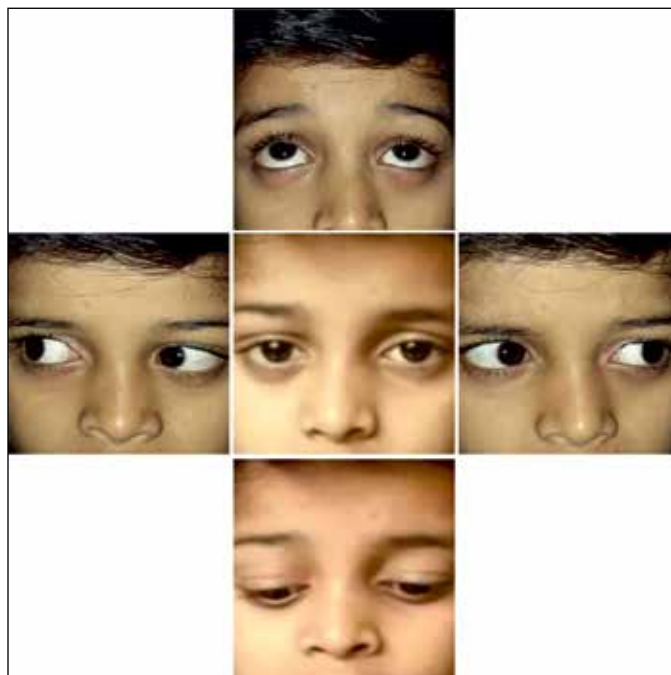


Figure 4: Followup at 1 year

speed with which the extravasated fluids are absorbed.^{5,7} Aneurysms of the internal carotid artery and/or carotid-cavernous fistula have been reported as etiology⁸ and may complicate the situation if urgent treatment has differed. The spread of associated infection directly to middle cranial fossa increases morbidity and mortality.

Our patient had an atypical history of injury by getting hit by a wire while walking, implying a low impact of trauma. The injury involved only the supero-temporal conjunctival tear with possible penetration in the deeper tissues as shown by trapped air pockets and minimal haemorrhage extending to extraconal space of superolateral orbit as visible in CT scan images. Probable causes of traumatic SOFS in our case is an indirect injury to superior orbital fissure due to haemorrhage, oedema and inflammation as described in previous studies.^{5,7} Entrapped air pocket may also be responsible for raised intraorbital pressure in this case. According to Fujiwara et al,¹⁹ a narrow superior orbital fissure of less than 1.6mm is a risk factor for SOFS. Our patient being a child, has a possibility of a small superior orbital fissure making him vulnerable to a minor injury. On superior orbitotomy exploration, the orbit was decompressed slightly with drainage of minimal haemorrhage (<0.5ml). The patient was started on pulse iv methylprednisolone therapy for 3 days and later shifted to oral prednisolone in tapering doses. The anti-inflammatory and antioxidant mechanism of steroids helps to reduce oedema and subsequent ischemia resulting in further decompression of the superior orbital fissure and enhancing restoration of the neuronal function.¹⁰ Haemorrhage may spontaneously resolve over a period of 3 weeks to 4 months but can also organize to form orbital blood cyst without endothelial lining.⁴ Hence, exploration and drainage is recommended to evacuate the blood when medical treatment is unsuccessful.¹¹ In our case we have

done early surgical intervention to avoid visual deprivation since the child was in a critical period of vision development. The symptoms often resolve over a period of 3-4 months with a good prognosis unless complicated by displaced bony fragments where the prognosis may vary.¹² Our patient showed complete recovery after 2.5 months without any complication till 1 year of follow up (Figure 4).

To conclude, minor penetrating trauma without any associated craniomaxillofacial fractures can lead to SOFS in children. Early surgical intervention is recommended if a child is in a critical period of vision development to avoid deprivation amblyopia. Early meticulous wound exploration with haematoma drainage under steroid cover gives satisfactory recovery in these cases.

References

1. Zachariades N. The superior orbital fissure syndrome. *Oral Surg Oral Med Oral Pathol* 1982;53(3):237-240.
2. Banks P. The superior orbital fissure syndrome. *Oral Surg Oral Med Oral Pathol* 1967;24(4):455-458.
3. Mortada A. Superior Orbital Fissure Syndrome of Uncertain Aetiology: Report of Ten Cases. *Br J Ophthalmol*. 1961;45(10):662-671.
4. Craniomaxillofac Trauma Reconstr. 2010 Mar; 3(1): 9-16.
5. Bowerman J. The superior orbital fissure syndrome complicating fractures of the facial skeleton. *Br J Oral Surg*. 1969;7(1):1-6.
6. Antonyshyn O, Gruss J, Kassel E. Blow-In Fractures of the Orbit. *Plast Reconstr Surg*. 1989;84(1):10-20.
7. Campiglio G, Signorini M, Candiani P. Superior Orbital Fissure Syndrome Complicating Zygomatic Fractures: Pathogenesis and Report of a Case Case Report. *Scand J Plast Reconstr Surg Hand Surg*. 1995;29(1):69-72. doi:10.3109/02844319509048427.
8. Zachariades N, Papavassiliou D. Traumatic carotid-cavernous sinus fistula. *J Craniomaxillofac Surg*. 1988;16:385-388.
9. Fujiwara T, Matsuda K, Kubo et al. Superior Orbital Fissure

- Syndrome After Repair of Maxillary and Naso-orbito-ethmoid Fractures: A Case Study. *J Plast Reconstr Aesthet Surg.* 2009;62(12):e565-e569.
10. Hall E, Braughler J. Glucocorticoid mechanisms in acute spinal cord injury: A review and therapeutic rationale. *Surg Neurol.* 1982;18(5):320-327.
 11. Mortada A. Unilateral proptosis of unexplained origin and superior orbital fissure syndrome of uncertain aetiology. *Bull Ophthalmol Soc Egypt* 1969;62:191-204.
 12. Robinson DC, Jarrett WJ. Superior orbital fissure syndrome with Bell's palsy: report of case. *J Oral Surg* 1973;31:203- 206.

Cite This Article as: Narendra Patidar , Prerana Phadnis , Amit Mohan , Parimal PiushA rare case of traumatic superior orbital fissure syndrome following an unusual mode of penetrating injury. *Delhi J Ophthalmol* 2020;31(1), 72-75.

Acknowledgments: Nil

Conflict of interest: None declared


Source of Funding: None

Date of Submission: 31 Aug 2019

Date of Acceptance: 13 Mar 2020

Address for correspondence

Prerana Phadnis MBBS, MS, FCO
Sadguru Netra Chikitsalaya, Jankikund,
Madhya Pradesh, India
Email id: preranaphadnis@gmail.com



Quick Response Code