

## Surprise Beneath The Bleb

Meena Gopinath Menon, Vijaya L. Alle

Glaucoma Services, Sankara Eye Hospitals, Bengaluru, India

### Abstract

*Bleb revision for hypotony maculopathy following trabeculectomy is an effective technique for raising intraocular pressure and limiting visual loss. Reinforcing materials such as donor sclera may play an important role if over-filtration is the cause. Meticulous revision of the bleb can lead to resolution of bleb-related complications in most cases leaving a good quality of vision.*

Delhi J Ophthalmol 2020;31:78-80; Doi <http://dx.doi.org/10.7869/djo.576>

**Keywords:** Hypotony maculopathy, bleb over filtration, postoperative, bleb revision

### Introduction

Trabeculectomy is a commonly performed surgical procedure for lowering intraocular pressure. Although many trabeculectomies achieve successful outcomes, a minority develop bleb related complications. The following are the clinical scenarios which may warrant a surgical intervention for salvage of blebs.<sup>1</sup>

#### Five chief categories which warrant action include:

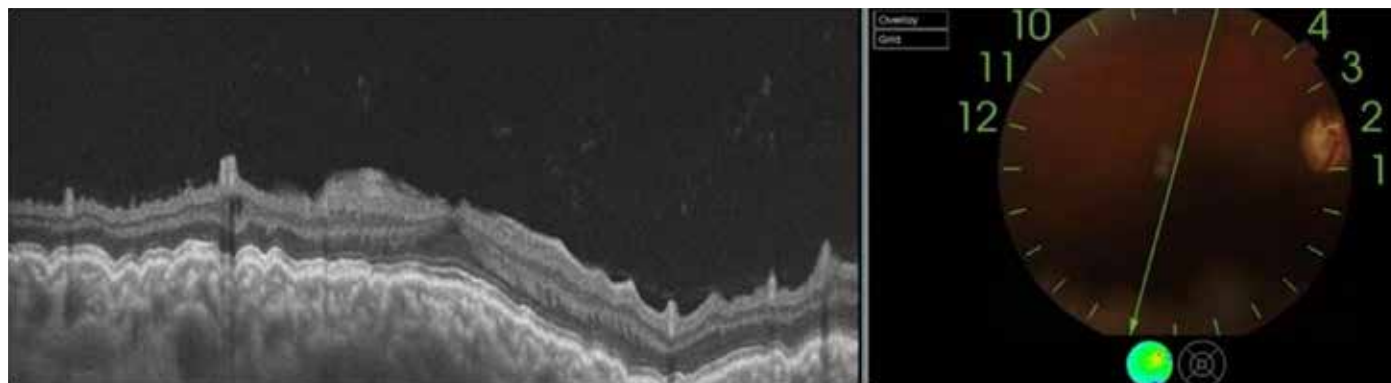
- i. Leaking bleb (postoperative or delayed)
- ii. Hypotony maculopathy with an ischemic, non-leaking bleb
- iii. Poorly functioning encapsulated bleb
- iv. Intolerable dysesthesia
- v. Flat, scarred blebs.

Hypotony maculopathy, first described by Dellaporta in 1954, occurs usually after anti-glaucomatous surgery or after perforating eye injuries.<sup>2</sup> The condition is characterized by hypotony associated with fundus abnormalities, including papilloedema, vascular tortuosity, and chorioretinal folds.<sup>2</sup> It can also be defined as IOP less than 6 mm Hg and loss of two or more lines of central vision.<sup>3</sup>

With the increased use of the antimetabolites, as an adjunct to trabeculectomy, hypotony maculopathy has become an increasingly common serious postoperative complication, with a reported incidence of 1.3% to 18%.<sup>2</sup> When comparing trabeculectomy with MMC versus 5-FU, there was no

significant difference in the incidence of hypotony (3% with MMC and 1% with 5-FU).<sup>4</sup> The cause of hypotony after trabeculectomy can be associated with over-filtration, wound leak or reduced aqueous production, which may be related to inflammation.<sup>1</sup>

We report a case of 41 year old asian Indian man who underwent trabeculectomy in both eyes elsewhere three years ago. There were no patient records with documented evidence of usage of antimetabolites. He presented to us with complaints of diminution of vision in right eye since 8 months. His best corrected visual acuity in right eye [RE] was 6/18 with correction of +5.5 D and left eye [LE] recorded hand movements. Intraocular pressure measured by applanation tonometry was 2mm of Hg in right eye and 11 mm of in his left eye Hg. Anterior segment examination revealed a 4 clock hour thin cystic bleb with no leak demonstrable on Seidel's test in RE and a cystic 2 clock hour bleb in LE. Fundus examination showed advanced glaucomatous cupping in both eyes (LE>RE) and right eye showed foveal striae. Humphrey visual analyser showed double arcuate scotoma in RE. Swept-source optical coherence tomography (SS-OCT) (DRI-OCT Triton; Topcon Medical Systems, Tokyo, Japan) showed chorio-retinal folds secondary to hypotony maculopathy in RE (Figure 1). Ultrasound biomicroscopy revealed a diffuse bleb with large ostium. We decided to take up the patient for bleb revision to give him better quality of vision.



**Figure 1:** optical coherence tomography of macula using swept-source optical coherence tomography (SS-OCT) (DRI - OCT triton; Topcon Medical systems, Tokyo, Japan ), Showing chorioretinal folds Secondary to hypotony maculopathy in R.E.

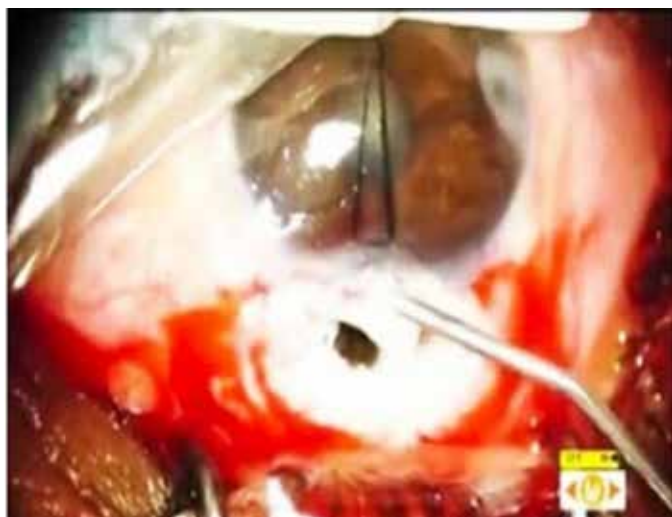

Figure 2: Large internal ostium underneath the sclera flap

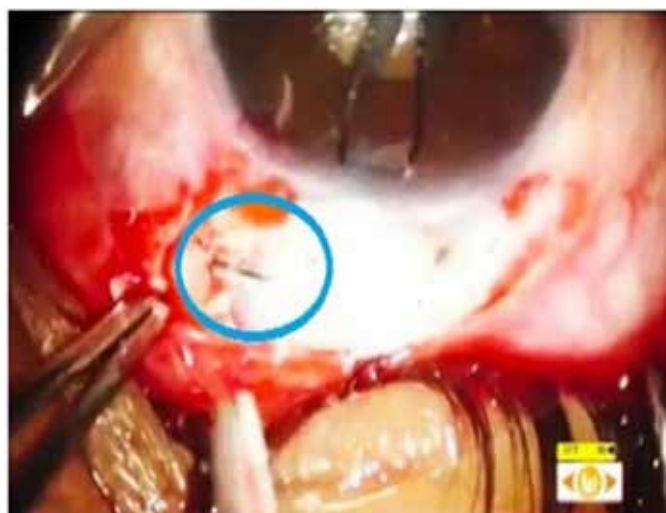

Figure 3: A Full thickness scleral defect medical to the trabeculectomy flap

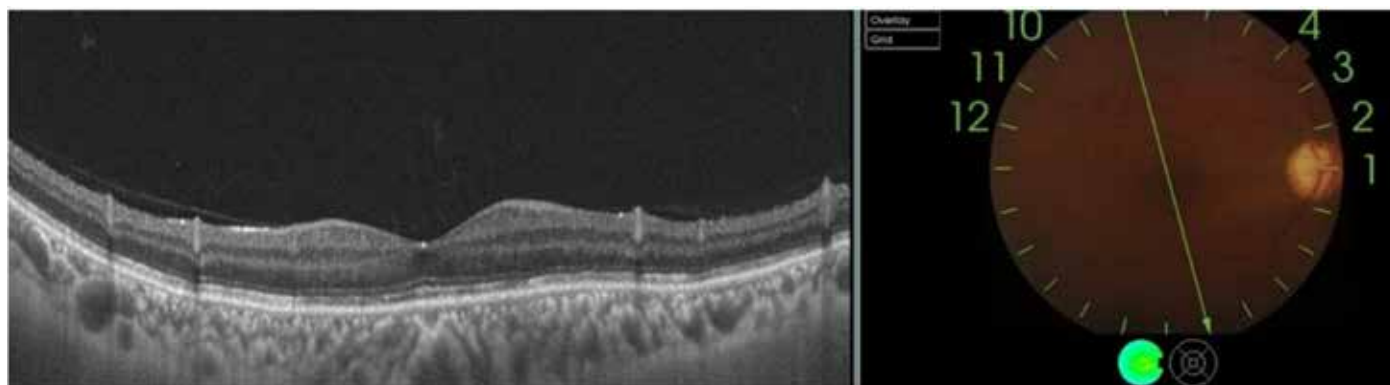


Figure 4: Optical Coherence tomography of macula using swept-Source optical Coherence tomography (SS-OCT) (DRI- OCT Triton; Medical Systems, Tokyo, Japan ) showing no chorioretinal folds ( Post Op 20 Days)

### Technique

After preparing the patient, a superior clear corneal traction suture was placed for good exposure. Bleb was explored by cutting the conjunctiva at the limbus. A temporal side port was made, on injecting the viscoelastic, the old trabeculectomy flap opened up, and a large internal ostium was noted (Figure 2). The bleb was further exposed medially and on further dissection to our surprise we noted a 2.5 mm full thickness scleral defect (Figure 3), this could be iatrogenic from the previous surgery. Meticulous and careful dissection of conjunctiva was carried out around the defect. While trying to suture the defect, uveal tissue was seen prolapsing out of: The defect and hence abandoned. Attempts to suture the trabeculectomy flap went in vain due to repeated cheese wiring. Thus a full thickness scleral patch graft was positioned over both the scleral defect as well as the flap. This was secured with multiple sutures using 9-0 nylon. Excess of sclera was trimmed out, this was then covered with conjunctiva, which was closed in a water tight manner with 10-0 nylon. Anterior chamber formation was done and a good raised bleb was observed. On the first post-operative day IOP was 8 mm of Hg

with a diffuse raised bleb. On subsequent follow up his best corrected visual acuity improved to 6/9 with an improvement in the hyperopic shift from + 5.5 D to + 1.5 D and the intraocular pressure improved to early teens with no demonstrable chorioretinal folds on OCT (Figure 4).

### Discussion

Trabeculectomy remains a mainstay in the management of glaucoma, despite problems frequently associated with it, such as hypotony. Leaving postoperative hypotony untreated can result in permanent visual damage, so it's crucial to be on the lookout for it and address it when it becomes apparent.

Hypotony generally falls into two categories: early and late. These tend to have different causes and prognoses and require different treatment. Early hypotony occurs in the first two weeks after surgery, most of the time secondary to bleb leaks resulting from poor wound closure or from over-filtration. This type of hypotony is usually mild and transient and resolves on its own. Most of the time, observation and conservative medical management are sufficient to address it.<sup>5</sup>

Hypotony that occurs more than two weeks after surgery, or late hypotony, may be secondary to an ischemic, avascular, thin bleb or over-filtration by the bleb. Late hypotony is usually more serious than early hypotony, and the prognosis for visual recovery depends on its duration. It becomes a cause for concern if it exceeds more than six months, since progression beyond that time frame may result in irreversible chorioretinal fibrosis. Although over-filtration is the most common cause of hypotony, there can be an unexpected very rare cause like iatrogenic defect other than large sclera ostium, which happened in this case.<sup>5</sup> Many different techniques have been attempted in managing the hypotony from over filtering blebs as well as for the surgical revision of over-filtrating blebs like, including bandage contact lens, Simmons shell, autologous blood injection, trichloroacetic acid, argon or neodymium: YAG laser, compression sutures and, cataract surgery. Where there are direct obvious connections from anterior chamber, visible after conjunctival removal, the filtration site can be reinforced with additional tissue. Donor sclera, donor pericardium and Tenon's connective tissue are some of the reinforcing materials which have been used.<sup>6</sup> In our case, both the scleral defect and the scleral ostium needed to be covered, so a full thickness sclera graft was used. The avascular and ischemic conjunctiva over the bleb was excised and the surrounding healthy conjunctiva was advanced and sutured.

### Conclusion

It is never too late to do something, as in this case which got revealed on table during exploration of the bleb. The successful treatment of hypotony maculopathy depends on the correct identification of its cause. Once the cause is detected, treatment should be employed as soon as possible because delayed normalization of the IOP may result in permanent macular chorioretinal changes and poor vision.

### References

1. Ichhpujani P, Pandav SS. Bleb Revision. Journal of Current Glaucoma Practice. 2010 Sep 7;4(3):155-7.
2. Mutoh T, Matsumoto Y, Chikuda M. Four cases of traumatic hypotony maculopathy treated by various methods. Clinical ophthalmology (Auckland, NZ). 2011;5:1223.
3. Bashford KP, Shafranov G, Shields MB. Bleb revision for hypotony maculopathy after trabeculectomy. Journal of glaucoma. 2004 Jun 1;13(3):256-60.
4. De Fendi LI, Arruda GV, Scott IU, Paula JS. Mitomycin C versus 5-fluorouracil as an adjunctive treatment for trabeculectomy: a meta-analysis of randomized clinical trials. Clinical & experimental ophthalmology. 2013 Nov;41(8):798-806.
5. Trubnik V, Mineola NY. Managing Hypotony after trabeculectomy. Rev Ophthalmol. 2015;22(11):124-8.
6. Sharma S, Patel D, Sharma R, Dada T. (2012). Bleb Revision using Reversed Scleral Flap and Pedicle Conjunctival Graft. Current Journal of Glaucoma Practice with DVD. 6. 10.5005/jp-journals-10008-1113.

**Cite This Article as:** Meena GM, Vijaya L Alle. Surprise Beneath the bleb- A case Report Delhi J Ophthalmology 2020;31(1) 78-80.

**Acknowledgments:** Nil

**Conflict of interest:** None declared

**Source of Funding:** None

**Date of Submission:** 21 Dec 2018


**Date of Acceptance:** 5 April 2020

### Address for correspondence

**Vijaya Alle ms**

Glaucoma services, Sankara eye hospitals,  
Bengaluru, India

Email id: vijayaalle.5@gmail.com



Quick Response Code