

A Rare Case Report of Unilateral Twin Crystalline Lenses

Suraj Kumar Chaurasiya, Maitri Paul

Department of Optometry and Vision Science, C.L. Gupta Eye Institute, Moradabad, Uttar Pradesh, India

Abstract

We report a rare case of congenital twin crystalline lenses in an eye. The longest visible iris diameter was oblique, drawn from temporal to nasal quadrant making cornea horizontally oval. The crystalline lenses were found to be situated obliquely on the horizontal axis in the upper temporal and lower nasal quadrant.

Delhi J Ophthalmol 2020;31;84-85; Doi <http://dx.doi.org/10.7869/djo.578>

Keywords: Lens duplication, abnormality of Crystalline lens

Introduction

Congenital abnormalities of the crystalline lens include defects of lenses, aphakic, and double lenses, the double crystalline lens is a rare abnormality, with only few case reports with twin crystalline lenses, that is a single eye carrying two lenses has been discussed.^{1,4}

Case report

A 3-year-old baby presented with her parents with complaints of the larger appearance of the left eye as compared to the right eye (Figure 1), photophobia and decreased vision in the left eye since birth. Any treatment or surgical intervention was nil. Birth history was not significant. In the right eye, the unaided visual acuity was 20/20 (measured with Kay picture chart) for distance and 6/6 (measured with reduced Snellen's chart) for near and other ocular examinations showed normal condition. In the left eye unaided presenting visual acuity was recorded as counting finger close to face and not improved with glasses. The cyclo-refraction with cyclopentolate 1% revealed +0.75 Dsph in the right eye and -2.00/-1.50*180 in the left eye.

Slit-lamp examination revealed left eye cornea was oval, the horizontal diameter is longer than the vertical diameter. The pupil was oval, oblique, and was reacting to light. The intraocular pressure was digitally normal in both eyes. Dilation of the pupil in the left eye showed twin crystalline lenses obliquely located on the horizontal axis in the upper temporal and lower nasal quadrants (Figure 2).

The fundus examination was normal with a cup disc ratio of 0.3:1 in both eyes. The scheinpluf image of Pentacam (Oculus Inc. Arlington, WA) revealed the distance between the twin crystalline lenses were 920 microns (Figure 3). The patient has advised combined surgery for the left eye of lens aspiration, primary posterior capsulotomy, anterior vitrectomy, and posterior chamber intraocular lens implantation, however, the parents did not give consent for the baby's surgery and were subsequently lost to follow up.

Discussion

Congenital twin lenses is a very rare condition with only a few cases reported so far.^{1,4} Thakkar et al reported a case of the congenital two lenses which were placed obliquely in a straight line with a clear space in between with the absence of zonules and capsule.¹ Richardson reported a similar

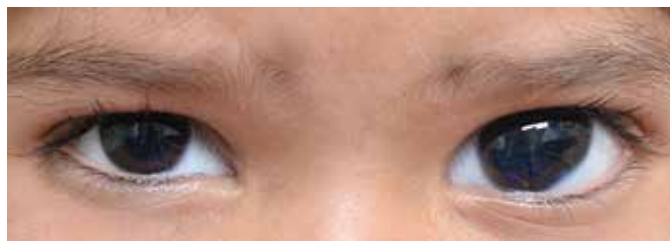

Figure 1: Showing the left globe is appearing larger than the right eye and also a horizontal axis of the left eye is obliquely placed

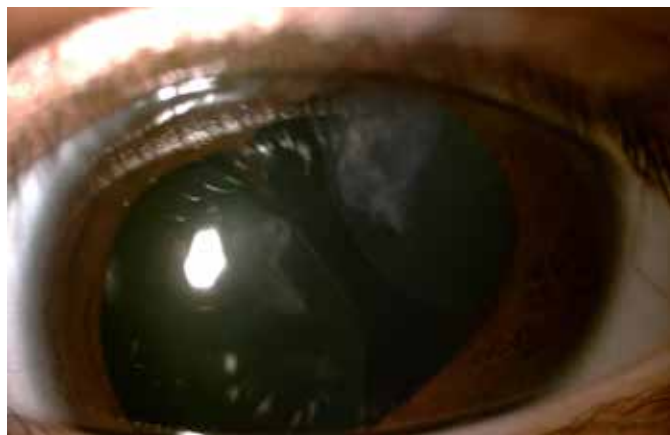

Figure 2: Showing twin crystalline lenses with oval, oblique pupil

case where there was the presence of two asymmetrical crystalline lenses in one eye, one being larger than the other and also had coloboma of iris and fundus.² Rupal Bhatt et al. reported a case with horizontally placed bi-lobular lens sharing a common capsular bag with inferior iris coloboma.³ However, in our case the cornea was oval, the horizontal diameter is longer than the vertical diameter and two crystalline lenses were placed obliquely on the horizontal axis in the upper temporal and lower nasal quadrants. The mechanism for such formation of twin crystalline lenses in the same eye is not clearly understood yet. Duke-Elder has explained the possibility of lens plate invagination at two places during the embryonic stage which may result in two lens vesicles and thus the formation of twin crystalline lenses can take place.⁵ Richardson suggested that central lens plate abnormality can also cause the formation of two lens vesicles which will lead to the formation of unilateral

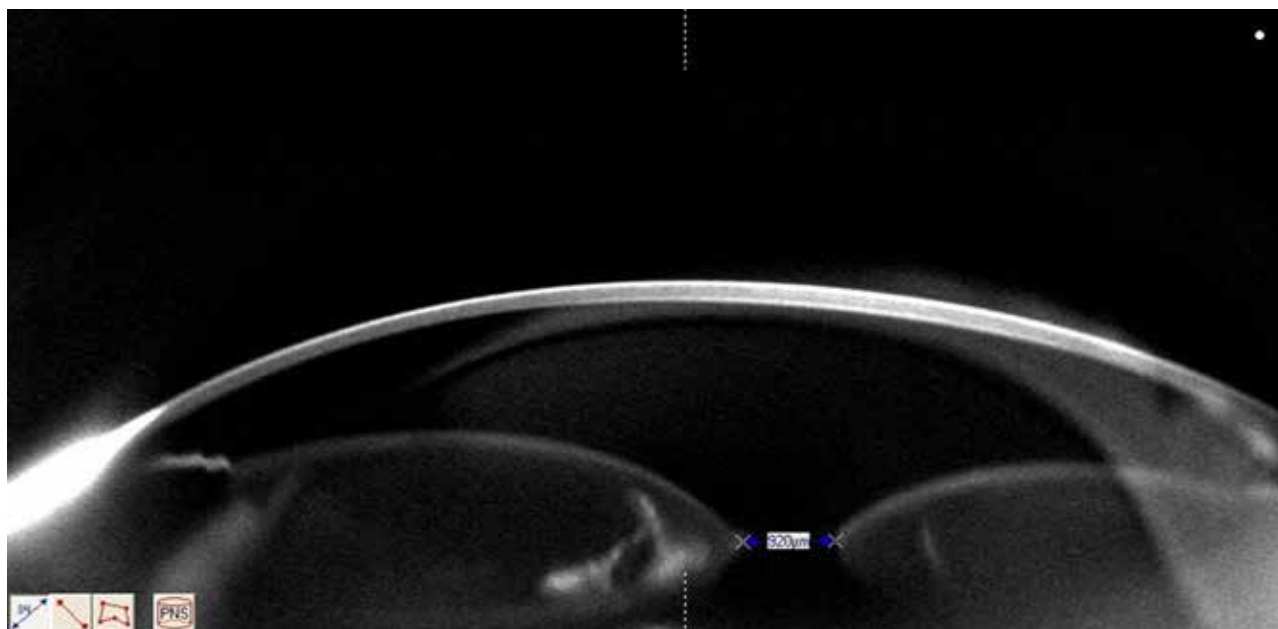


Figure 3: Pentacam scheimpflug image showing twin crystalline lenses

two crystalline lenses.²

Most of the previously reported cases had other ocular structures also affected along with twin crystalline lenses.¹⁻⁴ However, in this case, no other ocular abnormality was detected other than unilateral twin crystalline lenses and horizontally oval cornea. Another notable thing was, in all the reported cases as well as in this case only the left eye was affected and is this just a mere coincidence or has a deeper meaning to it, we can't say for sure.

References

1. Thakkar HH, Singh R. Congenital Double Crystalline Lenses. *Journal of Cataract & Refractive Surgery*. 2003;29(2):405-6.
2. Richardson O. Congenital Anomalies of the Anterior Segment. *Trans Can Ophthalmol Soc*. 1951;14:102-3.
3. Bhatt R, Jethani J, Saluja P, Bharti V. Single Lens to Lens Duplication: The Missing Link. *Indian journal of ophthalmology*. 2008;56(1):67.
4. Grey RH, Rice NS. Congenital duplication of the lens. *British Journal of Ophthalmology*. 1976 Oct 1;60(10):673-5.
5. Elder D. Anomalies of lens. In: *System of ophthalmology*. Henry Kempton; 1969. p. 688-741.

Cite This Article as: Chaurasiya SK and Paul M. A rare case report of unilateral twin crystalline lenses *Delhi J Ophthalmol* 2020;31(1), 84-85.

Acknowledgments: Nil

Conflict of interest: None declared


Source of Funding: None

Date of Submission: 27 Mar 2020

Date of Acceptance: 02 May 2020

Address for correspondence

Suraj Kumar Chaurasiya
 Ram Ganga Vihar Phase II (Extn),
 C.L. Gupta Eye Institute, Moradabad,
 Uttar Pradesh, India
 Email id: csurajk414@gmail.com



Quick Response Code