

Lamellar Cataract

Pavani Murthy Penugondla, Srinivasa S. Sastry, Sreenivasa P. Rao

Department of Cornea and Refractive Surgery, Sree Netralaya Eye Hospital, Kothapet, Hyderabad

Abstract

A 38-year-old male presented with complaints of decreased vision since childhood, which has been increasing in the past decade. Examination revealed a central lamellar cataract in both the eyes.

Delhi J Ophthalmol 2020;31;86; Doi <http://dx.doi.org/10.7869/djo.579>

Keywords: Lamellar, zonular, developmental cataract

Introduction

A 38-year-old male presented with complaints of decreased vision since childhood, which has been increasing in the past decade. Examination revealed a central lamellar cataract in both the eyes. Fundus was unremarkable. Post-op vision following cataract surgery was 20/30 in both eyes.

Lamellar/Zonular cataract is a developmental cataract, which can be acquired or inherited (autosomal dominant), Toxic insult during embryogenesis, calcium and vitamin D deficiency during pregnancy have also been reported as etiological causes. It is mostly bilateral and asymmetrical. Lamellae surrounding the fetal nucleus are involved with peripheral clear lamellae and radial riders.^{1,2}

References

1. Patil B, Sharma R, Nayak B, Sinha G, Khokhar S. Pediatric cataract. *Delhi J Ophthalmol* 2015;25: 160-165.
2. Khokhar SK, Pillay G, Dhull C, Agarwal E, Mahabir M, Aggarwal P. Pediatric cataract. *Indian J Ophthalmol* 2017;65:1340-9.
3. Joseph E, Meena CK. Pediatric cataract. *Kerala J Ophthalmol* 2018;30:162-71.
4. Ould Hamed MA, Yassine M (2018) Congenital Unilateral Lamellar Cataract. *J Clin Res Ophthalmol* 5(1): 013-013.

Cite This Article as: Pavani Murthy P, Srinivasa S Sastry, Sreenivasa P Rao. Lamellar Cataract. *Delhi J Ophthalmol* 2020;31;86.

Acknowledgments: Nil

Conflict of interest: None declared

Source of Funding: None

Date of Submission: 4th feb 2020

Date of Acceptance: 2nd March 2020

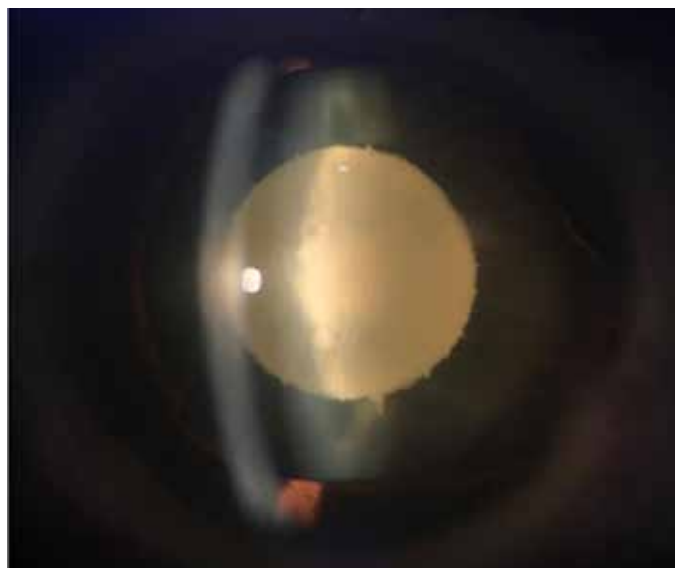

Figure 1: Right eye showing the central lamellar cataract with radial riders

Address for correspondence

Penugondla Pavani Murthy

Cornea consultant


Department of Cornea and Refractive Surgery

SreeNetralaya Eye Hospital

SBI Colony, Kothapet, Hyderabad

Telangana, India

Email: murthy.pavani@gmail.com



Quick Response Code