

Prosection of the Goat's Eye as a Teaching-Learning Method for the Undergraduate Medical Students During Clinical Postings in a Medical College in South India: A Study of Reflections

Aditi Vidha, Uma Kulkarni

Department of Ophthalmology Yenepoya Medical College, Mangalore, India.

Background: Understanding the complex anatomy of the eyeball is challenging for a medical undergraduate student. We evaluated the effectiveness of prosection (demonstrated dissection) of enucleated goat's eye as a teaching-learning method and explored the reflections of the undergraduate medical students.

Methods: After ethical approval and informed consent, the study was conducted on 71 undergraduate students during their clinical postings in ophthalmology. The students were randomized into two arms. Arm A was taught anatomy of the eye using PowerPoint presentation and arm B using prosection. Pre and post-test questionnaires were provided to compare knowledge scores. Students were asked to write their reflections about prosection.

Results: Mean pre and post Day 0 and Day 7 knowledge scores in both arms were identical and did not differ statistically ($p=0.530, 0.97, 0.92$) indicating that both the interventions were - quantitatively speaking - equally effective. Students' reflections on prosection were analyzed qualitatively. Students enjoyed the novelty of the teaching method, appreciated the unraveling of the complicated ocular anatomical arrangements, understood the eye three-dimensionally, saw the otherwise invisible structures of the eye, appreciated the transparent structures and discerned the complexity and interrelatedness of structures. Students reported enhanced learning through touching, feeling and seeing. They indicated that the learning was self-directed, collaborative, and promoted situated-learning through participation. Students opined that prosection supplemented by PowerPoint presentation should be included in the undergraduate ophthalmology curriculum.

Conclusion: Prosection, when aided by a systematic commentary and interaction, stimulates multi-modal learning to understand ocular anatomy and should be included in the curriculum to create an interest in the subject of ophthalmology among medical undergraduate students.

Abstract

Delhi J Ophthalmol 2020;31;36-40; Doi <http://dx.doi.org/10.7869/djo.588>

Keywords: Prosection, Dissection, Goat's Eye, Situated Learning, Reflection

Introduction

Understanding the 24-mm miniature and complex eyeball relies on accurate transformation of two-dimensional diagrams into three-dimensional imagery. For an ophthalmology teacher, as well as the undergraduate medical student, this necessitates out-of-box teaching-learning to simplify the 'hard-to-remember and easy-to-forget' abstruse anatomy and facilitate its comprehension.

Traditional chalk-and-talk teaching is effective; and the contemporary PowerPoint presentations can embed colorful illustrations and aid in recall.^{1,2} Nevertheless, undergraduate students often find ophthalmology complicated and difficult to correlate clinically. Applied anatomy is found to be better understood through cadaveric dissection among physicians-in-training.³ However, in the embalmed cadaver, the eye is shriveled and collapsed; rendering dissection impractical and leaving students deprived of this learning opportunity. Moreover, in the first year of the curriculum, under time-constraints to teach the other anatomical body parts (such as superior and inferior extremities, thorax, abdomen, head, face, neck and brain) the "less important" structures like the ear and the eye are often neglected.

Perceiving a need to bridge this gap, we explored prosection (demonstrated dissection) of enucleated goat's eye as a teaching-learning method, during the ophthalmology clinical

postings. The objective was to evaluate the effectiveness of prosection of goat's eye for understanding ocular anatomy and to explore the undergraduate students' reflections on the innovative teaching method.

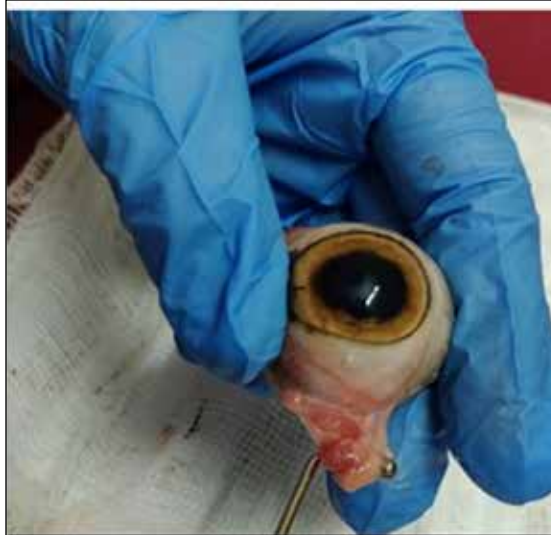Methodology

The study was conducted after approval from the Institutional Ethics Committee, and after taking written informed consent. It was a prospective study on 71 undergraduate medical students during their first ophthalmology clinical posting (6th term; 3rd year) between June and August 2019. Pre (Day 0) and post-intervention (Day 0 and Day 7) knowledge in ocular anatomy was assessed in both the arms with a validated, pre-tested, objective-type, single-best-response, structured questionnaire, consisting of 30 recall items, on topics as per curriculum and were scored for correct answers. The students were randomized using envelope method into two arms: A (PowerPoint presentation with pictures and text) and B (prosection - demonstrated dissection of goat's eye) (Figures 1 -6).

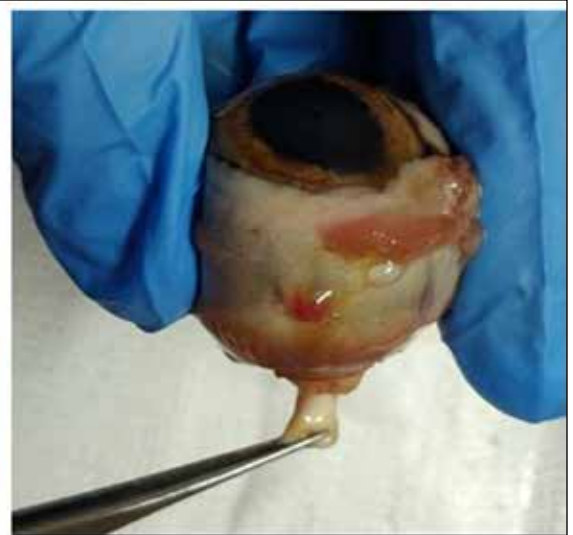Each intervention lasted 40-50 minutes and was carried out on small groups of 12-15 students and included the following topics: gross anatomy, the coats, segments and chambers of the eye, lens and zonules, extraocular muscles and optic nerve attachments.

The teaching was structured, and the facilitation interactive,

Figures 1 and 2:
Demonstration of gross anatomy

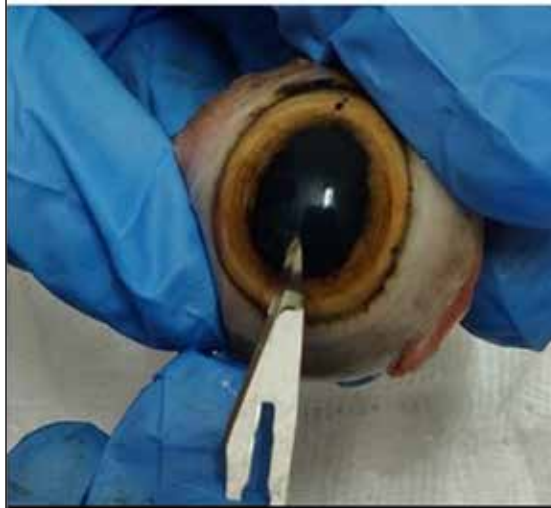


The enucleated goat's eye

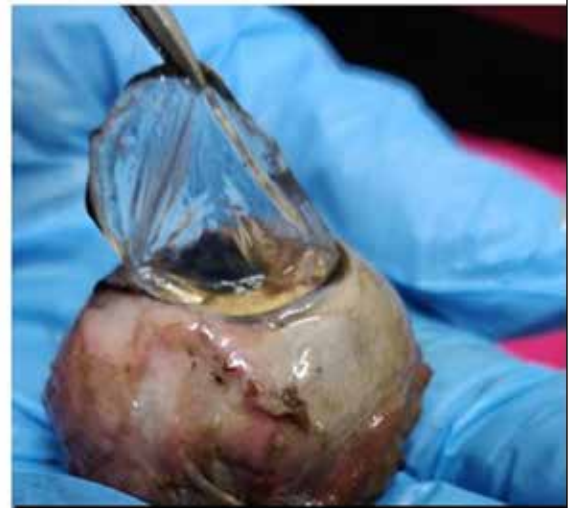

Gross anatomy and optic nerve

Figures 3 and 4:
Approaching the anterior chamber

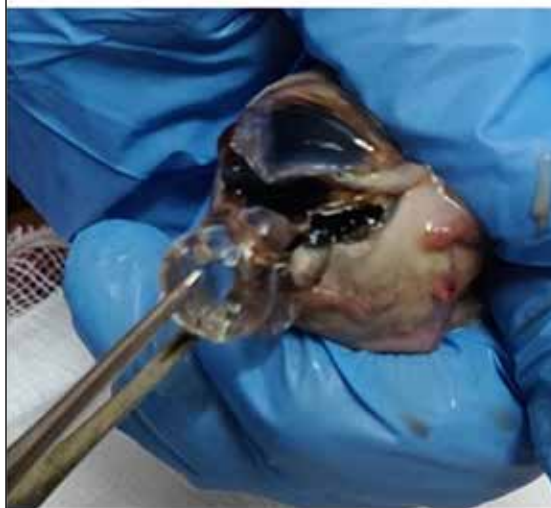

Instrumentation & demonstration

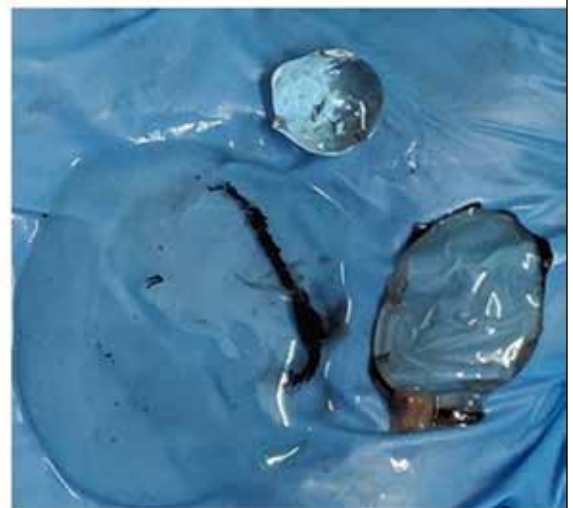

Excision of the Cornea

Figures 5 and 6:
Extraction of the lens



Lens removal



The transparent structures

with time for clarification of doubts. In addition, in arm B, students were allowed to touch and handle the tissues through gloved hands. The presentations were prepared and presented by the first author (AV) and validated and supervised by the second author (UK).

We chose goat's eye because of its similarity to the human eye, easy availability from abattoirs, without compromising animal rights and ethics. Also, there are no cultural and ethical issues like those associated with the use of pig's eye, which has even more similarity with the human eye. One student requested to be shifted to arm A owing to the discomfort anticipated during dissection. After D0 post-test, but before D7, students in arm A, after hearing about the "fun-learning" in arm B, requested that they be shown the prosection. We acceded - in the larger interest of the students' enthusiasm. We asked students to write their reflections about goat's eye dissection as a teaching-learning method. We have reported the narrative experience of the authors too. We present our findings in two parts: a quantitative part based on the questionnaire scores and a qualitative part based on the reflective narrations.

Discussion

Quantitative part: There were 35 students in Arm A and 36 in Arm B. The pre-intervention scores and the post-intervention scores on Day 0 and Day 7 are shown in the table below. The

Table 1: Pre and post-test scores for prosection of goat's eye versus PowerPoint presentation

Mean scores and range	Pre-intervention	Post-intervention Day 0	Post-intervention Day 7
Arm A	4.7±3.36 (range 1 to 12)	17.11±4.19 (range 5 to 23)	14.5±4.2 (range 3 to 22)
Arm B	5.25±3.77 (range 0 to 12)	17.08±5.71 (range 6 to 25)	14.6±5 (range 6 to 24)
	p= 0.530	p= 0.97	p= 0.92

scores were compared using t test and a p value of <0.05 was considered statistically significant (Table 1).

There was no statistically significant difference in the knowledge scores or gain in knowledge scores in the two arms, indicating that both methods were equally effective in imparting knowledge of ocular anatomy. Studies have demonstrated that cadaveric dissection positively influences learning and students retain information longer when taught anatomy using dissection.^{1,4} Although PowerPoint presentation has the advantage of impactful imagery, students are familiar with it and novelty is lacking. Prosection has the advantage of being novel, allows visualizing and feeling of the actual eyeball. However, the excitement may have led to distraction and inattentiveness. The lack of statistical significance could be because we tested only recall and not the higher domains of knowledge such as interpretation and synthesis. In terms of quantitative analysis there was no statistically significant difference between the two teaching methods.

Qualitative part: The students' reflections were analysed, coded, grouped under themes and subthemes as follows and some of the narratives are verbatim quoted thereafter:

1. **Novelty of the teaching method:** Students expressed that prosection was interesting and that routine lectures and PowerPoint presentations were sometimes mundane and monotonous. Some of the words/ sub-themes were "interesting" (29 students), "enhanced learning" (20), "useful" (10) and "reinforced learning" (8). With prosection, ophthalmology appeared exciting and interesting, and learning was fun and focused. As a novel experiential-learning technique, prosection created interest and stirred emotions.
 - i. "First I wasn't interested, but as the dissection started it became interesting" (B15)
 - ii. Usually the ppt and textbook reading feels boring and I would end up sleeping. But dissection was interesting. It was a wonderful experience. (B12)
2. **Elucidation of a complicated topic:** Prosection (with visual and kinesthetic learning elements) influenced the perspective of the students' understanding of ocular anatomy. Words used to indicate better understanding included "see" (25), "understand" (21), "learn" (15), "clarify" (13), "layers" (7), "remember" (3) among others.
 - a. Understanding the eye three-dimensionally: Students reported that the two-dimensional cross-section of the eye failed to give a clear understanding of its three-dimensional structure, whereas the prosection experience did. One student confessed that after dissection, she understood that the zonules were present all around the lens - 360 degrees and not just above and below.

"It was a really amazing experience. I was amazed about what all structures can be found inside the eye. From my childhood I have been drawing pictures of the eye and I had many questions in my mind. I could finally clear it perfectly and I am satisfied." (B9)
 - b. Seeing the otherwise invisible structures of the eye: Prosection had the advantage of exploring the otherwise invisible parts of the eye with instruments: inserting the tip of the forcep between structures to demonstrate the anterior chamber, its angle, posterior chamber and scleral sulcus; retracting the iris to demonstrate the zonules and ciliary processes; peeling off the lens capsule to feel the texture of the nucleus and cortex, removing the vitreous to visualise retina; peeling of retina to uncover the choroid and the optic nerve head and so on.

"I have always been confused about the chambers. It finally made sense. Also now that I have a picture in my mind, I understand the pigmented and non-pigmented structures better" (B8)
 - i. "Till now I had only "imagined" the interior of eye whenever I read any topic related to eye. This was a good experience that helped me find how much of my imagination was right and how much was wrong". (A6)
 - c. Understanding transparent structures: Students appreciated the transparent structures and described

them in their own words. The cornea looked like a contact lens, aqueous like clear 'water', the lens appeared like a 'marble' and the vitreous, a 'pulpish' clear gel. Through constant questioning, the students correlated transparency with avascularity, clear image formation and visualization of fundus. The students wondrously realized that it was the clear cornea that was transplanted during eye donation.

- d. Understanding the complexity and interrelatedness of structures: The systematic, sequential dissection, layer by layer unraveled the complex structure of the eye and their interrelatedness.

"As ma'am was taking out each layer of the eye, we students were getting more excited as this was our 1st experience." (A2)

"I had doubts regarding chambers and segments (of the eye). All were cleared during this class." (B27)

3. **Learning through 'touch':** Along with visualization, touch helped learning. Students used words like "feel" (23), "touch" (6), "texture" (3) in descriptions of the cornea (soft and thin), lens (globular, moulding nature), vitreous (gel-like, wobbly) and optic nerve (cord-like).

"There is always a difference between what we study just by reading books and dissecting, seeing the structure and touching it. The second method is always more effective than PowerPoint classes." (A20)

4. **Inclusion of prosection as a regular teaching method:**

Many opined that prosection should be included as a regular method in the first MBBS curriculum along with cadaveric dissection, and reinforced during clinical postings. Some students felt a lost opportunity during anatomy classes. Some indicated that each student should be given an opportunity to dissect goat's eye.

"Eyeball dissection should be introduced to all MBBS students in second year as it helps in revising what we studied in first year as well as make ophthalmology a more exciting and interesting subject". (B6)

5. **Facilitators' perspective:** We observed that the learning was active, enhanced and exploratory through asking doubts, observing and feeling tissues with undistracted attention. Students asked for the structures to be shown again. Questions included, which part of the eye is transplanted during eye donation, whether whole eye is removed during eye donation, difference between enucleation and evisceration, how avascular tissues survive, how cataracts can cause blurred vision, etc. indicating that the learning was active, reinforced and self-directed. The enhanced maturity of students during clinical postings enabled them to process and apply this fresh knowledge to the various clinical conditions they had encountered, indicating that their involvement in learning was 'mindful'.

We found that the teaching of ocular anatomy to students through prosection of the goat's eye created an active 'situated' learning atmosphere, promoted collaborative and peer-learning and encouraged reflection-in-action, all of which are very strong components of learning-by-doing or experiential learning.^{5,6,7} Learning by doing encourages students to think critically.⁸ Critical thinking is an important

skill set that enhances the students' learning in the higher domains of analysis, synthesis and evaluation, promotes competency-based learning and helps shape the overall professional development of the student.

Students better understood the complex three-dimensional structure, the transparent tissues, the otherwise invisible structures of the eye and their relatedness to each other. This is supported by other studies where students agreed that dissection helped them understand the three-dimensional perspective of structures better.^{9,10} In our study, prosection led to reinforced learning and increased applicability, as also observed by Kivell et al (2009) and Pawlina and Lachman (2004) who state that dissection provides students an opportunity to reinforce and validate previous learning through self-observations and understand three-dimensional structures with a better perspective.¹¹ Balcombe has argued "there is no better way to understand the structure and function of an organism than by directly examining the organism".¹² Chan & Ganguly (2008), through a questionnaire-based study found that small-group teaching through dissection improved students' performance.¹³ Seeing all the structures the way they are in real and not just images, definitely helped our students in giving a different perspective to what they had learnt, with a better touch of reality.

In our study the facilitator (AV) reported that students were seen thinking aloud and repeatedly asking the same questions. In other words, our students were reflecting-in-action, and this was driving their learning. Students opined that prosection should be integrated in the teaching curriculum of the undergraduates in the first year and reinforced during clinical postings as it increased their understanding and clinical applicability. Kivell et al (2009) have similarly recommended dissection of porcine eye, in the early period of the clinical clerkship. A study by Ramsey-Stewart (2010) reported that after a 7-week dissection course on anatomy, a significant increase in clinical anatomical knowledge was demonstrated among the students and all students graded the course as helpful and suggested it to be a part of the curriculum.¹⁴

Granger (2004) argues that the importance of dissection doesn't merely provide academic merits, but is also invaluable for psychosocial development of medical students.¹⁵ The same was observed in our study, wherein the teachers noticed mindful learning of students and enabled them to think beyond ocular anatomy. There is a need to diversify teaching style to cater to the learning styles of each distinctive student.¹⁶ Prosection, according to our study, when aided by a systematic commentary and interaction, stimulates visual, aural and kinesthetic learners and may therefore be considered a superior teaching method satisfying most of the criteria in the VARK model of Neil Fleming.¹⁷

Conclusion

To conclude, prosection of goat's eye was an effective teaching-learning tool for undergraduate medical students and was comparable to PowerPoint teaching in terms of gain in knowledge scores. In addition, prosection showed distinct advantages. It allowed an enhanced, systematic and sequential learning of the complicated, miniature

anatomy of the eye. It proved to be a superior teaching method suiting different learners (kinesthetic and visual). Prosection promoted collaboration among peer-groups and encouraged social development of learning. It was well-received as an innovative teaching method, instilling interest, attentiveness and involvement among students and teachers. We recommend that prosection be considered as a regular teaching method in conjunction with the traditional classroom teaching methods.

Generally, for a teacher, the essence of teaching is often lost in the efforts of making an impressive PowerPoint presentation and for the student, the essence of learning is lost in attendance, grades and percentages. Prosection is that teaching-learning method which can be cherished both by the teacher and the learner.

Limitations

It would have been best if each student would have done the dissection by herself. We used the prosection method to explore the worthiness of introducing this innovative method in the clinical posting. If we go by the well-described quote by Confucius, "I read and I forget, I see and I remember, I do and I understand" (Kendall, 1991, as cited by Franta, 1994),¹⁸ dissection rather than prosection of the goat's eye may offer enhanced benefits to the undergraduate medical students. The other limitation in our study was that D7 responses were probably contaminated due to early crossover in the study design, driven by students' desire to undergo the prosection experience. Nevertheless, the feedback provided by the students, retrospectively justified our actions.

Disclaimer

No animals were harmed specifically for the purpose of this study. The dissection was carried out with safety precautions-wearing gloves and using sterilized set of instruments exclusively earmarked for this purpose. Afterward, the dissected eyes and tissues were disposed as per biomedical waste disposal policy of the hospital. No learner or facilitator reported any injury during the study.

References

- Ankolekar VH, Souza AD, Souza AS, Hosapatna M. Effectiveness of PowerPoint Presentations in Teaching Anatomy: A Students' Perspective. *Advanced Science Letters*. 2017 Mar 1;23(3):1977-9.
- Craig RJ, Amernic JH. PowerPoint presentation technology and the dynamics of teaching. *Innovative Higher Education*. 2006 Oct 1;31(3):147-60.
- Shyamal A, Bokariya P, Kothari R, Vajir SJ, Hiware SD, Batra P. IS Dissection Better Than Prosection For Learning Anatomy?. *International Journal of Scientific Research*. 2019 Jul 1;8(6).
- Schrock JR. Defending dissection. *The American Biology Teacher*. 1992; 54: 454
- Yardley S, Teunissen PW, Dornan T. Experiential learning: AMEE guide No. 63. *Medical teacher*. 2012 Feb 1;34(2):e102-15.
- Sandars J. The use of reflection in medical education: AMEE Guide No. 44. *Medical teacher*. 2009 Jan 1;31(8):685-95.
- Kolb DA. *Experiential learning: Experience as a source of learning*. 2nd Ed. 2015.
- Wass R, Harland T, Mercer A. Scaffolding critical thinking in the zone of proximal development. *Higher Education Research & Development*. 2011; 30(3): 317-328.
- Azer S, Eizenberg N. Do we need dissection in an integrated problem-based learning medical course? Perceptions of first- and second-year students. *Surg Radiol Anat*. 2007;29:173-80.
- Kivell TL, Doyle SK, Madden RH, Mitchell TL, Sims EL. An interactive method for teaching anatomy of the human eye for medical students in ophthalmology clinical rotations. *Anatomical sciences education*. 2009 Jul;2(4):173-8.
- Pawlina W, Lachman N. Dissection in learning and teaching gross anatomy: rebuttal to McLachlan. *The Anatomical Record Part B: The New Anatomist: An Official Publication of the American Association of Anatomists*. 2004 Nov;281(1):9-11.
- Balcombe J. (2000). *The use of animals in higher education. Problems, alternatives, and recommendations*. Washington, DC: Humane Society Press.
- Chan LK, Ganguly PK. Evaluation of small-group teaching in human gross anatomy in a Caribbean medical school. *Anatomical sciences education*. 2008 Jan;1(1):19-22
- Ramsey-Stewart G, Burgess AW, Hill DA. Back to the future: teaching anatomy by whole-body dissection. *Med J Aust*. 2010;192:668-71.
- Granger NA. Dissection laboratory is vital to medical gross anatomy education. *The Anatomical Record Part B: The New Anatomist: An Official Publication of the American Association of Anatomists*. 2004 Nov;281(1):6-8.
- Fleming ND. I'm different; not dumb. Modes of presentation (VARK) in the tertiary classroom. In: Zelmer A, editor. *Research and Development in Higher Education, Proceedings of the 1995 Annual Conference of the Higher Education and Research Development Society of Australasia (HERDSA)*. Vol. 18. Higher Education Research and Development;1995. p. 308-13.
- Fleming N. VARK: A guide to learning styles. Available from: <http://www.var-k-learn.com/english/index.asp>.]
- Franta P. Service-learning: A new priority for career centers. *Journal of Career Development*. 1994;21(2):131.

Cite This Article as: Aditi Vidha, Uma Kulkarni Prosection of the Goat's Eye as a Teaching-Learning Method for the Undergraduate Medical Students During Clinical Postings in a Medical College in South India: A Study of Reflections. *Delhi J Ophthalmol* 2020 ; 31 (2) :36- 40.

Acknowledgments: Nil

Conflict of interest: None declared

Source of Funding: None

Date of Submission: 29 Dec 2019

Date of Acceptance: 19 May 2020

Address for correspondence

Uma Kulkarni

Professor, Ophthalmology

Yenepoya Medical College, Mangalore

Mailing id: "Lakshmi Keshava, 4th cross, Shivabagh, Mangalore, India.

Email: umakulkarni@yenepoya.edu.in,



Quick Response Code