

Bandage Contact Lens: a boon for corneal ulcer cases

Rashmi Kewaliya Joshi, Surbhi Kanawa, Anju Kochar

S.P. Medical College, PBM Hospital Bikaner Rajasthan, India.

Purpose: Bandage contact lenses are fabricated hydrogel lenses, effective in many corneal problems, most commonly in the healing of incisions occurring after refractive surgery and traumatic corneal abrasions. They promote healing, improve vision and act as a delivery mechanism for drugs. The principle therapeutic aim of these lenses is to provide relief from pain, provide mechanical protection and seal corneal perforations by acting as a splint for the underlying weaker tissue. This study was planned to evaluate therapeutic efficacy of bandage contact lenses in cases of non healing corneal ulcer, impending perforation and perforated corneal ulcer cases.

Methods: It was a single centre prospective study. 65 corneal ulcer cases were selected in whom BCL was applied from 1 week to 3 months. Cases were divided in 2 groups; Group A, with descemetocoele or small corneal perforation, in whom BCL was applied at 1st day and group B with non-healing corneal ulcer cases, in whom BCL was applied after 20-30 days.

Results: Out of 65 patients 36 were males and 29 were females. Group A had 34 cases and Group B had 31 cases. The healing time of corneal ulcer was 12.80 ± 6.48 days in group A and 10.24 ± 4.59 days in group B. No serious complication was noted in any case. 85% cases reported visual recovery.

Conclusion: 90-97% relief was noted post BCL application without undue complications. Timely BCL application, broad spectrum antibiotic and antifungal treatment and proper monitoring helped to salvage these eyes.

Abstract

Delhi J Ophthalmol 2020;31;51-55; Doi <http://dx.doi.org/10.7869/djo.591>

Keywords : Bandage Contact Lens, Corneal Ulcer, Perforation

Introduction

The burden of corneal ulcer cases is increasing at an immense rate. They cause sight threatening complications and are prevalent among all age groups. Corneal ulcer can be of bacterial, fungal, viral, or parasitic etiology. Sometimes sterile corneal ulcers can occur secondary to loss of sensory function. In medical therapy, antibiotics, antifungal, antiviral, mydriatics and sometimes steroids are used for their treatment.¹ Many times, these cases respond poorly to medical therapy due to a number of reasons like delayed presentation at tertiary centre, non-compliance, environmental conditions etc. This may result in complications like severe thinning, descemetocoele, ectatic cicatrix or perforation. The indications for surgical management are large ulcer with risk of scleral involvement, extreme thinning or perforation, worsening in spite of treatment and uncertain etiology. Different modalities used are tissue adhesives, bandage contact lenses, lamellar or full thickness patch graft, penetrating keratoplasty or conjunctival graft.² Surgery has its own complications such as inconvenience of observation, higher cost and a larger psychological and economic burden. Therefore some cheaper, convenient and feasible methods like Bandage contact lenses are required for these cases.

The Bandage contact lenses (BCLs) are effective in many corneal problems, most commonly used in the healing of incisions occurring after refractive surgery and traumatic corneal abrasions. They promote healing, improve vision and act as a delivery mechanism for drugs.

Contact lenses have undergone many modifications from first corneal plastic lens to the introduction of present hydrogel lens by Wichterle and Linn 1960.³ Bandage contact lenses are fabricated hydrogel lenses.⁴ This study was planned to

evaluate therapeutic efficacy of bandage contact lenses in cases of non healing corneal ulcer, impending perforation and perforated corneal ulcer cases.

Materials and Methods

It was a single centre prospective study conducted from May 2016 to July 2019 at a tertiary care hospital. Out of 250 patients of corneal ulcer of varying etiology attending the department for treatment, 65 corneal ulcer cases were selected in whom BCL was applied after obtaining written consent. The BCLs used in the study were soft hydrogel low water content lenses (<45%). In some, BCL was kept for 1wk and others up to 3 months based on patient compliance and healing process. Before the commencement of the study, approval was sought and obtained from the Institutional Ethics Committee.

Before BCL application, a detailed clinical history and thorough local examination was done. Routine blood investigations including fasting blood sugar to rule out diabetes mellitus and test for HIV was performed to rule out immuno-compromised status of the patient. Treatment given to each patient was customized according to his local presentation and systemic status and also changed during the course as per need. As a part of routine protocol, corneal scrapings were taken and sent for culture and sensitivity at the time of presentation and again after a week in culture positive cases.

In our study the BCL applied cases were divided in 2 groups based on a number of factors:

Group A: Cases who presented with descemetocoele or small perforation with absence of iris incarceration with the size of perforation not exceeding 1 mm.

Group B: Non- Healing corneal ulcer cases with corneal thinning (not healed in 10-20 days). The size of ulcer in these cases ranged from 3.5 to 6 mm in diameter, central or para-central in location and up to half of the stromal layer in depth with no scleral involvement.

Trial fitting was done prior to BCL application as keratometry reading was not possible. First 4% xylocaine eye drop was instilled in patient’s conjunctival sac and after 2 minutes interval BCL was applied to the patient’s diseased cornea. Lens fit was examined on slit lamp and patient was kept under observation for minimum 3 hrs (to check proper fitting and tolerance of the patient). Topical and systemic medications were continued and eye ointments withdrawn. The patients were instructed to report immediately if there is pain, foreign body sensation or foginess of vision.

Evaluation

A proforma was prepared to thoroughly evaluate the patients for amelioration of signs and symptoms and for any improvement in visual status. Slit lamp examination was performed on every follow up to evaluate corneal ulcer status and proper BCL alignment was noted. IPD patients were reviewed on a daily basis till discharge and then as per schedule. Outdoor based patients were followed up at day 1, day 3, day 7 and then on weekly basis for 3 months.

Results

A total of 65 corneal ulcer cases were taken in our study, in which BCL was applied. Out of 65 patients, 36 were males and 29 were females. We divided the patients in two groups. The mean age of patients in group A was 45.20±20.71 and in group B was 41.62±15. (Table 1)

In Group A, we had a total of 34 cases. 15 (44%) cases presented with descemetocele on their first visit, BCL was applied to them. 19 (56%) patients had marked corneal thinning or a

Table 1 : Demographic profile of patients in two groups.

S. No.		Group A No. (%)	Group B No. (%)
1	Males	21(32)	15(23)
2	Females	13(20)	16(25)
3	Mean Age	45.20±20.71	41.62±15.54

very small perforation with no iris tissue incarceration. In these cases also BCL was applied immediately after complete evaluation. Cyanoacrylate glue was not applied in any of these cases. Culture could not be sent for these cases as there were chances of perforation. As per clinical presentation treatment was started in these cases. (Figure 1 and 2).

Table 2 shows the etiological distribution of cases in group B. Maximum numbers of cases were of bacterial and fungal ulcer. BCL was applied in them since they showed poor healing even after 20-30 days of continued treatment.

Table 3 shows 20% of the patients in group A informed of

Table 2 : Etiological distribution of cases in Group B

S. No.	Etiology of Corneal Ulcer in Group B	No. Of Cases (%)
1	Viral Corneal Ulcer	3 (9.6%)
2	Bacterial Corneal Ulcer	7 (22.5%)
3	Neuroparalytic Keratitis	1 (3.2%)
4	Marginal Corneal Ulcer	2 (6.5%)
5	Fungal Corneal Ulcer	7(22.5%)
6	Bacterial + Fungal Corneal Ulcer	5 (16.1%)
7	Negative culture report	6 (19.4%)
	Total	31

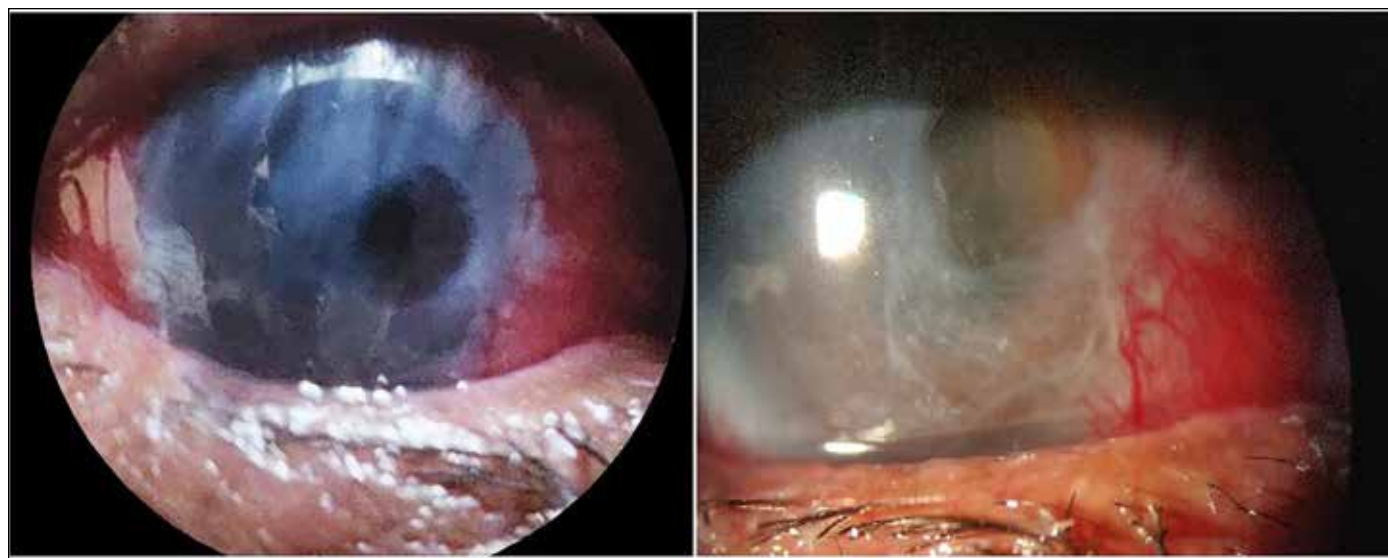


Figure 1: Shows image of a case of corneal ulcer with descemetocele at the time of presentation in the left and image after 10 days of BCL application in the right.

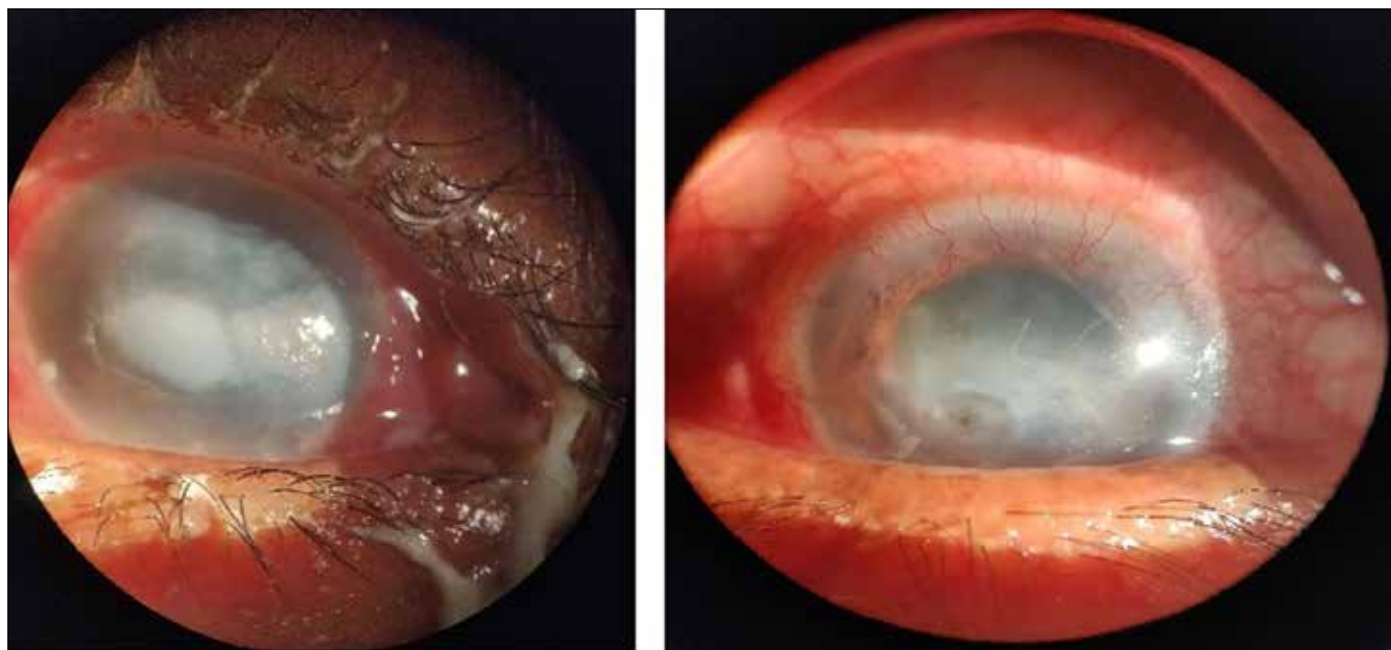


Figure 2: Shows images of a case of corneal ulcer who presented with para-central infiltrate with small perforation (left). BCL was applied to this case and showed marked improvement within 7 days (right). Edge of Bandage contact lens is also clearly visible in the image to the right.

Table 3 : Improvement on Follow up in Group A

Improvement on Follow up in BCL applied Cases (%)N=34					
S. No.	Parameters	1st day	3rd Day	1wk	1 month
Symptoms					
1	Pain relieved	20%	60%	80%	97%
2	Improvement in Blepharospasm	3%	71%	87%	97%
3	Foreign body sensation Relieved	86%	94%	94%	94%
Signs					
1	Vision Improved	8%	42%	75%	85%
2	Congestion Decreased	14%	52%	75%	94%
3	Decrease in ulcer size	3%	60%	83%	97%

pain relief on 1st day and about 97% of the patients reported relief in pain by end of 1st month of BCL application. From all 34 cases 94% of cases showed relief from foreign body sensation by 3rd day itself. 97% of cases showed decreased ulcer size and 94 % showed decreased congestion by 1 month of BCL application. Although improvement in vision was only shown by 85% of cases it could be largely due to corneal opacification even after healing. (Figure 3). Figure 3 shows series of images at day 1, day 7, after 1 month and after 3 months of a case of non healing corneal ulcer undergoing treatment along with BCL application. (Table 4) shows that 20% cases in group B showed relief in

Table 4 : Improvement on Follow up in Group B

Improvement on Follow up in BCL applied Cases (%)N=31					
S. No.	Parameters	1st day	3rd Day	1wk	1month
Symptoms					
1	Pain relieved	20%	60%	80%	90%
2	Improvement in Blepharospasm	10%	60%	82%	95%
3	Foreign body sensation Relieved	65%	85%	90%	92%
Signs					
1	Vision Improved	6%	35%	65%	75%
2	Congestion Decreased	9%	52%	75%	90%
3	Decrease in ulcer size	0%	30%	65%	85%

pain on day 1st while 90% of the cases had pain relief by the end of the month. 95% cases showed improvement in blepharospasm which was marked in few of these ulcer cases earlier. Congestion decreased up to 90% and also ulcer size reduced in about 85% of these cases. However only 75% of cases showed improvement in vision, which could be attributed to large leucomatous corneal opacities. The healing time of corneal ulcer was 12.80±6.48 days in group A compared with 10.24±4.59 days in the other group. No serious complication was noted in any case in this study. In group A two patients showed no improvement in this study and BCL was discontinued after 1 month of application because of intolerance to BCL. However in these 2 cases no disease progression was noted.

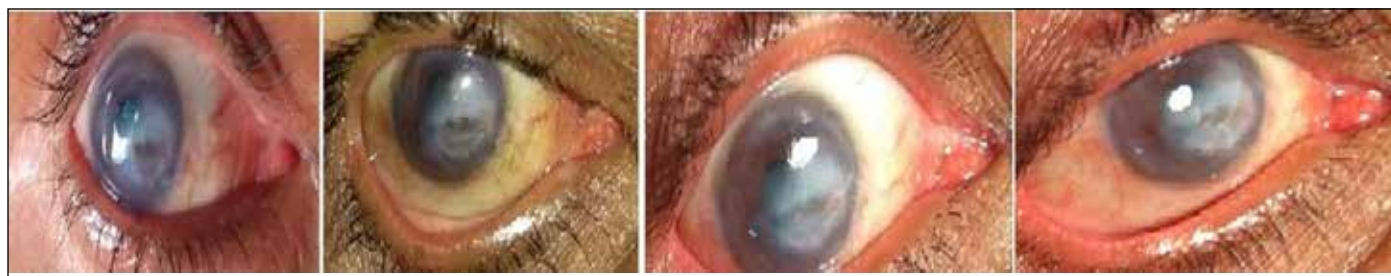

Figure 3: Shows series of images at day 1, day 7, after 1 month and after 3 months of a case of non healing corneal ulcer undergoing treatment along with BCL application.

Discussion

Bandage contact lenses are useful in various corneal diseases as they promote corneal healing, pain relief and better drug delivery. They are also used in trichiasis, entropion and traumatic corneal abrasions. BCLs have been shown to be useful in various other conditions like bullous keratopathy, dry eye syndrome and filamentary keratitis.^{5,6}

In our study, we have exclusively used BCL in all spectrums of corneal ulcer cases. As most of the patients in our study came from rural areas, they mostly neglected the condition initially or took treatment from some quacks. Such patients presented in late stages and came with small perforation or descemetocele or corneal thinning. BCL was immediately applied in them after complete evaluation to prevent further deterioration. As culture report could not be sent for these patients, empirical treatment based on clinical assessment was started along with BCL application.

Thirty four of such cases (Group A) of corneal perforation and descemetocele were included in our study, which showed marked improvement after BCL application. Similar results with improvement of up to 80% are shown in various other studies which reported healing by rapid epithelialization of ulcer after BCL use.^{7,8} The mechanism by which BCL helps in healing of small perforation is multi-factorial which includes mechanical protection, structural support and opposition of wound margins.⁹ Corneal healing and re-epithelialization is promoted by BCL as a result of its protective action on new epithelial cells which are otherwise repeatedly disturbed by eyelid blinking and eye movements. BCL application for 4-7 days helps in closing off the leak initially by epithelialization and later by scar formation. They are however useful in small corneal perforations or lacerations only when they have good opposition of edges and alignment with no prolapse of uveal tissue. Along with BCL aqueous suppressant topical medications used in the form of supportive treatment help in reducing intra ocular pressure, decreasing outflow from the site of defect and in promoting healing.¹⁰

In group B we had 31 cases of non healing corneal ulcer out of which 85% cases showed improvement post BCL application. Comparable results with improvement of up to 60-100% have been shown in other studies.¹¹ One of the important causes of non healing corneal ulcer is persistence of infection. BCL exaggerates the effects of locally applied drugs by increasing the contact time of medication. Increased drug absorption may occur due to compromised cornea in contact lens wearers. Medications can be absorbed and concentrated into the lens during the treatment which can

later be released gradually over a prolonged period of time.¹² In our study we have observed marked relief (90-97%) from troublesome symptoms like pain, watering, blepharospasm and foreign body sensation post BCL application.

We observed healing of corneal perforation and ulcer with acceptable visual results and no serious complications after BCL application. Similar results were found in one case series on usage of BCL in perforated corneal injuries.¹³ Another study has shown that BCL is safe with no serious complications after application and helps in better drug penetration of antibiotic eye drops.¹⁴

Patients have also reported improvement in vision post BCL application. Marked visual improvement was not seen, which could be attributed to nebular and leucomatous opacities of cornea or cataractous lens changes. We were still able to salvage these cases from undergoing mutilating surgery like evisceration. Moreover there is a later hope of better visual recovery by penetrating keratoplasty surgery.

Conclusion

This study shows that BCL is helpful in cases of descemetocele, small perforation and non healing corneal ulcers. BCL application in these cases leads to 90-97% relief without undue complications. Timely BCL application, broad spectrum antibiotic, antifungal treatment and proper monitoring helped to salvage these eyes. However further studies are required to establish its role in infective keratitis cases and as an alternative to surgical management.

References

1. Bowling B. Kanski's Clinical Ophthalmology - A Systematic Approach. 8th edition. Ed. Elsevier; 2016; 175-180.
2. Garg P, Rao GN. Corneal ulcer: diagnosis and management. Community Eye Health. 1999;12(30):21-23.
3. Witcherle O, Lim D. Hydrophilic gels for biological use. Nature. 1960;185:117-8.
4. MP Rubinstein. Applications of contact lens devices in the management of corneal disease. Eye;2003;17; 872-876
5. Punjabi S, Bedi N. A clinical study to evaluate therapeutic efficacy of soft contact lenses in corneal diseases. Int J Res Med Sci 2016;4: 4632-6.
6. Gasset AR, Kaufman HE. Therapeutic uses of hydrophilic contact lenses. Am J Ophth. 1970;69:252.
7. Saji Nair A, Accamma Mamman. Bandage contact lens: A clinical study. Indian Journal of Clinical and Experimental Ophthalmology, April-June,2017;3(2): 227-230
8. Mondino BJ. Inflammatory diseases of the peripheral cornea. Ophthalmology. 1988;95:463-72.
9. Shipra Gupta, Pankaj Gupta, Rony Sayegh. Healing a persistent corneal defect in : ophthalmic pulse 2014 August 33-35

10. Natalic Cheung et al. Management of descemetocoele and corneal perforation : Eye wiki 2020
11. Buxton JN, LR Clyde. A Therapeutic Evaluation of Hydrophilic Contact Lenses. Am J Ophth. 1971;72(3):532-5.
12. Muntingh GL. Drug and contact lens interactions : SA Fam Pract 2004; 47(8) : 24-28
13. C E Hugkulstone. Use of a bandage contact lens in perforating injuries of the cornea. Journal of the Royal Society of Medicine. June 1992;85: 323
14. Sun YZ, Guo L, Zhang FS. Curative effect assessment of bandage contact lens in neurogenic keratitis. Int J Ophthal. 2014;7(6):980-983

Cite This Article as: Joshi Rashmi, Kanawa Surbhi. Bandage Contact Lens: a boon for corneal ulcer cases. Delhi J Ophthalmology. 2020 ; 31(2): 51-55

Acknowledgments: Nil

Conflict of interest: None declared

Source of Funding: None

Date of Submission: 13th March 2020

Date of Acceptance: 22nd May 2020

Address for correspondence

Surbhi Kanawa, Resident
Department of Ophthalmology
S.P. Medical College, PBM Hospital
Bikaner, Rajasthan, India.
Mailing Address: 61, Tagore Nagar,
Kartarpura, Jaipur, India,
Email: surkanawa@gmail.com



Quick Response Code