

# Bronchodilator Nebulization – A Rare Presentation of Bilateral Acute Angle Closure Glaucoma

Divya Deepthi Syamala, Malleswari Medikonda

Sankara Eye Hospital, Vijayawada –Guntur Expressway, Pedakakani, Guntur, Andhra Pradesh, India.

## Abstract

Bronchodilator nebulization is one of the most commonly administered treatment for an acute attack of reactive airway disease. Development of acute angle closure glaucoma following nebulization therapy is a rare occurrence. We report a case of acute angle closure of both eyes in a 54 year old gentleman shortly after receiving therapy with inhaled salbutamol and ipratropium. This patient presented to our tertiary care eye hospital and was immediately treated with medical management and laser iridotomy. This case report highlights this rare but possible side effect of inhaled bronchodilator therapy. Health care providers need to be aware of this uncommon adverse effect and appropriate preventive measures such as identifying at risk individuals, usage of protective eye-wear, etc should be practiced.

Delhi J Ophthalmol 2020;31;85-89; Doi <http://dx.doi.org/10.7869/djo.600>

**Keywords:** Acute Angle Closure, Salbutamol, Ipratropium, Glaucoma

## Introduction

Acute angle closure glaucoma (AACG) affects about 0.1% of people older than 40 years and the risk increases further with advancing age<sup>1</sup>. Precipitation of AACG with use of inhalational agents like alpha-adrenergic drugs is well documented in literature especially in the elderly. The symptoms usually start within few hours to up to 9 days after exposure to inhalational therapy. It usually manifests with sudden decrease in vision, photophobia and headache in the distribution of ipsilateral trigeminal division of ophthalmic nerve.

It is crucial to have a high index of suspicion to promptly recognise symptoms and diagnose AACG in these patients to prevent permanent damage. As per existing evidence, there seems to be a synergistic effect to combined bronchodilator therapy (salbutamol and ipratropium) in precipitating an acute attack of AACG.<sup>2</sup>

## Case Report

A 54 year old gentleman presented with headache, pain and blurring of vision in both eyes especially the left eye beginning 8 hours earlier. Past medical history was significant for rheumatic mitral valve disease with recent mitral valve replacement few weeks ago. He was on treatment with acitrom, amiodarone, verapamil, furosemide, spironolactone, and pantoprazole orally. One day prior to the presentation to ophthalmology department, he had developed an episode of acute breathlessness for which he received nebulization with ipratropium bromide and salbutamol. Patient developed acute ocular pain and blurring of vision in left eye followed by right eye within 8 hours of receiving the nebulization.

On presentation to the emergency department, patient was conscious, oriented and in severe pain. Systemic examination was normal except for tachycardia secondary to pain. On Ocular examination, his visual acuity was assessed as counting fingers in both eyes. Both eyes revealed moderate conjunctival congestion, microcystic corneal

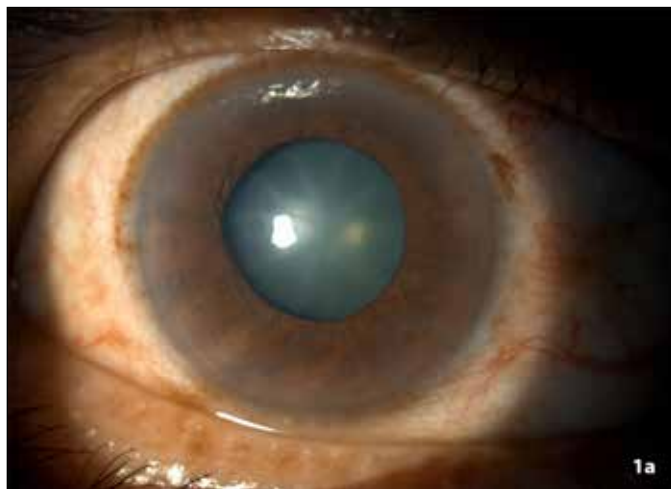


Figure 1a: Anterior segment of RE showing congestion and mid-dilated pupil

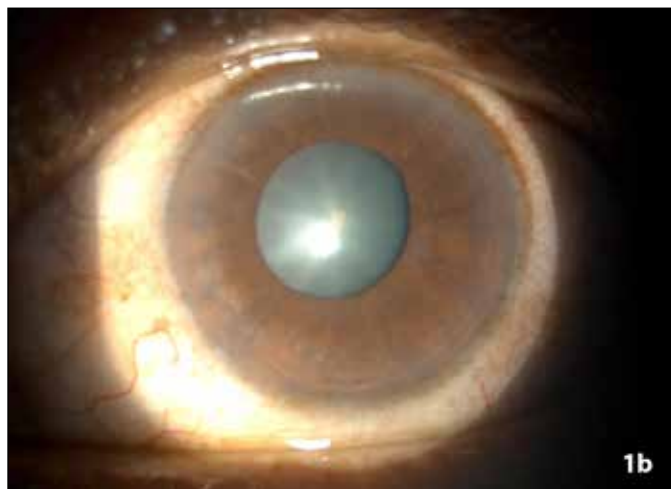


Figure 1b: Anterior segment of LE showing congestion and mid-dilated pupil edema, extremely shallow anterior chamber (Figure 2), fixed and mid-dilated pupils (Figure 1). The Intraocular pressure (IOP) was 42 mmHg in RE and 40 mmHg in LE.



Figure 2a: Van Herick's RE showing Grade 1



Figure 2b: Van Herick's LE showing Grade 1




Figure 3a: Gonioscopic images RE showing closed angles(A=superior angle,B=nasal angle,C=inferior angle,D=temporal angle)




Figure 3b: Gonioscopic images LE showing closed angles(A=superior angle,B=temporal angle,C=inferior angle,D=nasal angle)

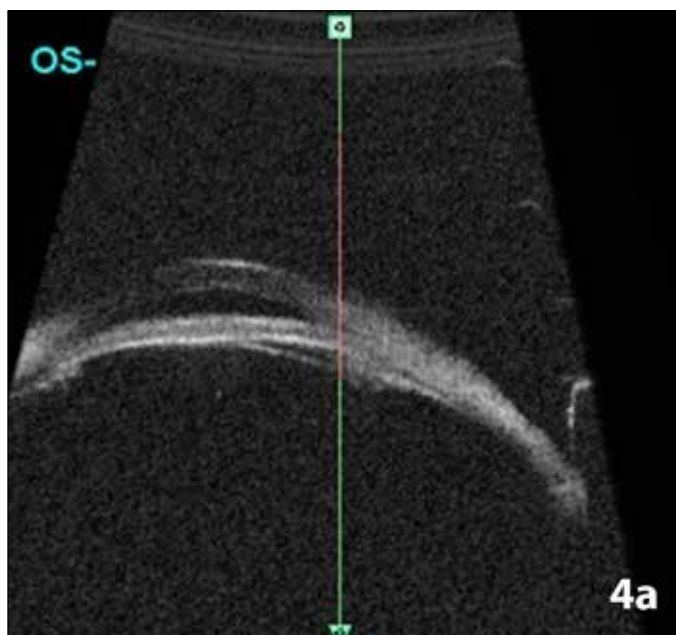


Figure 4a: Ultrasound Biomicroscopy of LE pre PI showing shallow AC

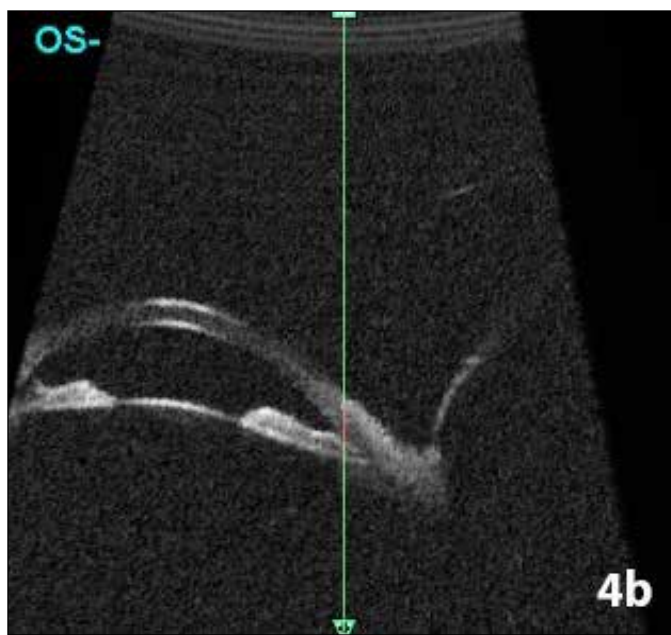


Figure 4b: Ultrasound Biomicroscopy of LE post PI showing deepening of AC

Gonioscopic examination of both eyes revealed 360° closed angles, (Figure 3a & 3b) thus confirming the diagnosis of acute angle closure glaucoma in both eyes. Patient was treated with prednisolone 1 % eye drops QID for inflammation, oral glycerol 40 ML, acetazolamide BD, topical brimonidine 0.2% eye drops TID, brinzolamide 1% TID and pilocarpine 2% QID. Two hours after the treatment and partial clearing of corneas in both eyes, Peripheral Iridotomy (PI) was performed with Nd YAG laser in both eyes. This decreased the IOP to 22 mm Hg in Right eye and 16mm Hg in Left eye with immediate symptomatic relief. Patient was prescribed prednisolone acetate 1% eye drops 4 times per day in both eyes and advised to continue topical and systemic ocular hypotensive treatment and review after 3 days. Three day follow-up examination demonstrated IOP of 12mm Hg in

RE and 14mmHg in LE, patent iridotomies in both eyes with deepened anterior chambers (Figure 6) and his unaided visual acuity improved to 6/12 in both eyes. All ocular hypotensive medications were stopped and topical steroids tapered over 3 weeks period. His fundus examination in both eyes was normal except for pallor of the optic discs due to raised intraocular pressure at the time of acute attack (Figure 5).

**Discussion**

AACG is one of the commonest emergencies faced in clinical ophthalmology. It may cause blindness if not promptly diagnosed and managed. Acute angle closure attack generally occurs following pupillary block and can also occur in association with ciliary body position and lens thickening.<sup>3</sup> Many medications have been implicated in triggering AACG

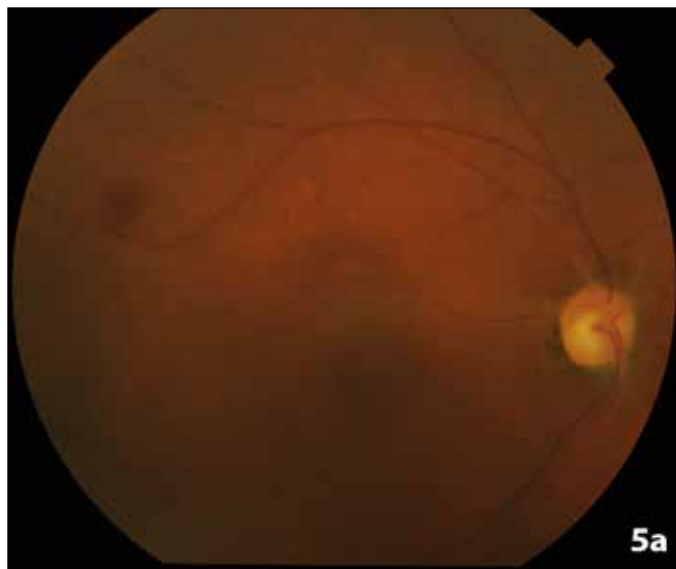


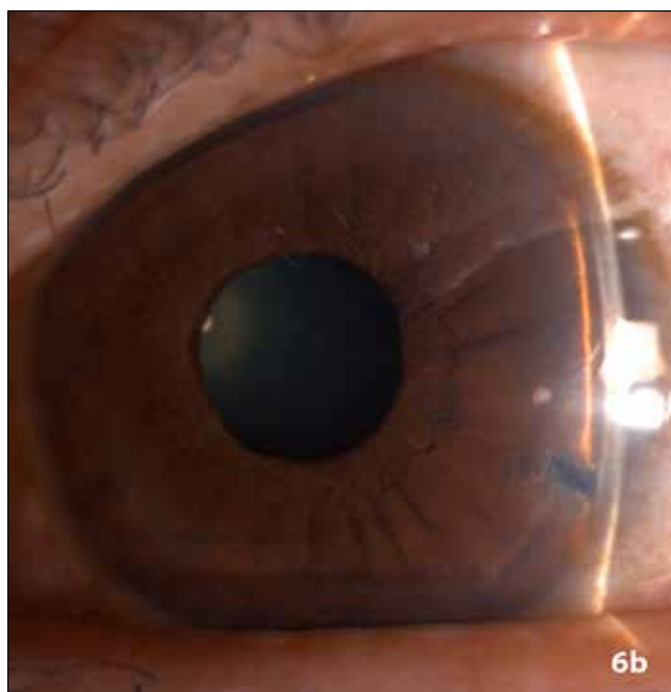
Figure 5a: Fundus photo showing disc pallor in RE

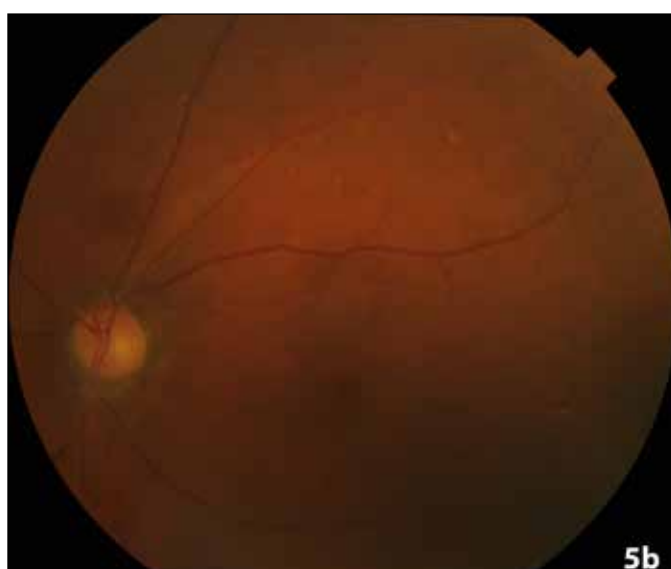
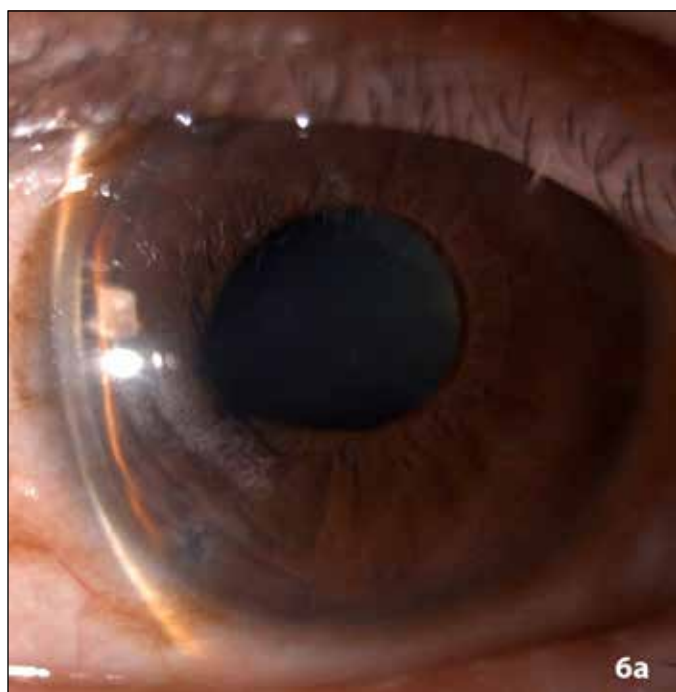
Figure 5b: Fundus photo showing disc pallor in LE



**Figure 6a:** Anterior segment of RE post PI showing deepened anterior chamber and PI



**Figure 6b:** Anterior segment of LE post PI showing deepened anterior chamber and PI

like adrenergic, cholinergic, anticholinergic, antihistaminic, antidepressant and antispasmodic agents.<sup>3,4,5</sup>

One of the frequently used bronchodilator drug for obstructive airway disease is salbutamol (beta2 agonist). Stimulation of the sympathetic pathway due to topical absorption causes pupillary dilatation precipitating an acute attack of AACG. Similar phenomenon has also been reported with usage of ipratropium which is an anticholinergic drug. The combined use of beta agonist and anticholinergic drugs has been reported to increase the chances of AACG.<sup>6,7,8</sup> Corneal absorption of salbutamol during nebulization has been hypothesised by Kalra and Bone to result in increased intraocular pressure (IOP) and angle narrowing. This may result in increased aqueous humor secretion secondary to agonist action on beta2 receptors in the ciliary body. Similarly, AACG can be precipitated by antagonist action of ipratropium on the parasympathetic pathway. In fact, all the patients with narrow angles in their series who were exposed to inhalation treatment with combined salbutamol and ipratropium, had a documented increase in IOP. About half of these patients developed transient angle closure. It was observed that this increase in IOP did not happen in patients wearing protective eyewear such as goggles. This suggests that the changes in IOP and angle probably were caused by topical absorption.

### Risk factors

Common risk factors implicated for AACG are elderly age, female sex, Asian ethnicity, strong family history of similar eye disease and hypermetropia. A few innate anatomical features may also predispose to the risk such as a thick crystalline lens, plateau iris configuration and narrow irido-corneal angles. A significant number of people who develop AACG due to pupillary block are seldom

aware that they are predisposed because of presence of innately narrow iridocorneal angles. If at all it is known that a person has innately narrow angle, then further evaluation with gonioscopy is warranted and consultation with an ophthalmologist should be sought for appropriate management.

There are recommendations regarding assessing probability of AACG in patients who need inhalational bronchodilators. The possibility of precipitating an attack of AACG should always be kept in mind when administering nebulized medicine to elderly patients. Previous history of AACG or symptoms such as blurred vision, red eye, nausea, unilateral headache and experiencing coloured halos should be elicited. It is advisable that an ophthalmologist consultation is sought for patients deemed to be at risk for AACG before initiating on bronchodilator therapy. This may be feasible in selected hospitalized settings however the practicality of this approach for an acutely sick patient in the emergency room has been questioned.

One practical approach is to avoid simultaneous nebulization of adrenergic and anticholinergic drugs at the same time. However the ideal interval of time gap between nebulization of these two classes of drugs is not clearly established. The rationale for combined use of ipratropium and salbutamol is the possible synergism between the 2 classes of drugs.<sup>9</sup> It has been advised that at risk patients be treated prophylactically with topical miotics (1% pilocarpine hydrochloride) before using inhaled bronchodilator drugs.<sup>10</sup> Glaucoma medications should be continued in known patients of glaucoma who are on treatment with inhalational bronchodilator therapy. Further, patients should be advised against rubbing their eyes after the nebulization to prevent auto-inoculation.

All patients planned for inhalation with anti-cholinergic

and alpha-adrenergic drugs should be educated regarding the signs and symptoms of AACG so that an impending attack can be promptly identified and averted by early intervention. Apart from patient education, it is also imperative that doctors and other health care professionals be aware of the possibility of this complication secondary to nebulization therapy. Other practical measures that reduce ocular deposition of nebulized medicine are using protective eyewear, using properly fitting and positioned face masks and hand-held nebulizers.

### Conclusion

The risk of precipitating AACG with usage of nebulized drugs such as salbutamol and ipratropium should always be kept in mind while treating patients with bronchospasm. Necessary precautions should always be taken to prevent direct drug contact with eyes during nebulization.

### References

1. Duke-Elder S, Jay B: Diseases of the lens and Vitreous: Glaucoma and Hypotony. St Louis: Mosby, 1969, p 392-398. (System of Ophthalmology;v 11).
2. Shah P, Dhurjon L, Metcalfe T, et al: Acute angle closure glaucoma associated with nebulized ipratropium bromide and salbutamol. *BMJ* 1992;304:40-41
3. Lai J, Gangwani R (2012) Medication-induced acute angle closure attack. *Hong Kong Med J* 18:1139-1145
4. Lachkar Y, Bouassida W (2007) Drug-induced acute angle closure glaucoma. *Curr Opin Ophthalmol* 18:129-133
5. Tripathi R, Tripathi B, Haggerty C (2003) Drug-induced glaucomas: mechanism and management. *Drug Saf* 26:749-767
6. Hall SK. Acute angle-closure glaucoma as a complication of combined beta-agonist and ipratropium bromide therapy in the emergency department. *Ann Emerg Med* 1994;23:884 – 887.
7. Mulpeter KM, Walsh JB, O'Connor M, et al. Ocular hazards of nebulized bronchodilators. *Postgrad Med J* 1992;68: 132-133.
8. Kalra L, Bone MF. The effect of nebulized bronchodilator therapy on intraocular pressures in patients with glaucoma. *Chest* 1988;93:739 –741.
9. Gross NJ. Ipratropium bromide. *N Engl J Med* 1988;319:486-492.
10. Berdy GJ, Berdy SS, Odin LS, et al: Angle closure glaucoma precipitated by aerosolized atropine. *Arch Intern Med* 1991;151:1658-1660.

**Cite This Article as:** Divya Deepthi Syamala, Malleswari Medikonda Bronchodilator nebulization – a rare presentation of Bilateral Acute angle closure glaucoma *Delhi J Ophthalmology*. 2020;31 (2):85-89

**Acknowledgments:** Nil

**Conflict of interest:** None

**Source of Funding:** None

**Date of Submission:** 14th March,2020

**Date of Acceptance:** 17th May,2020

### Address for correspondence

**Divya Deepthi Syamala** M.B.B.S,  
M.S(Ophth)

Department: Anterior Segment and  
Glaucoma Institution: Sankara Eye  
Hospital, Guntur, Andhra Pradesh,  
India.

Email : sdd332@gmail.com



Quick Response Code