

Keratoconus: Available Treatment Options

Twinkle Choksi¹, Saroj Sahdev², Rajendra Pawar³

¹Ophthalmology, TNMC and BYL Nair Hospital, Mumbai, India.

²Department of Ophthalmology TNMC and BYL Nair Hospital, Mumbai India.

³Department of Excellence Eye Centre, Mumbai India.

Abstract

Treatment of keratoconus has evolved substantially over years. Treatment modalities are aimed at stabilization of progressive ectasia with least invasive approach. Mainstay of treatment has shifted from keratoplasty – (penetrating or lamellar) to less invasive techniques like corneal collagen cross linking, intrastromal corneal ring segments and topography-guided PRK. Recently Bowman Layer Transplantation has evolved as a less invasive, promising option in patients with advanced progressive form of disease.

Delhi J Ophthalmol 2021; 31; 13-17; Doi <http://dx.doi.org/10.7869/djo.616>

Keywords: Ectasia, Collagen Cross-Linking, Intrastromal Corneal Ring Segments, Bowman Layer Transplantation.

Introduction

Keratoconus management remains a challenge for clinicians and multiple algorithms have been developed to help decision making. Treatment is directed towards achieving two important goals:

- (a) Stabilize progressive disease
- (b) Provide visual rehabilitation in safe and effective manner.

Keratoconus Progression

According to Global consensus on Keratoconus and Ectatic Diseases published in 2015, “ectasia progression” is defined by a consistent change in at least two of the following parameters¹

1. Steepening of anterior corneal surface
2. Steepening of posterior corneal surface
3. Thinning and/or an increase in the rate of corneal thickness change from periphery to the thinnest point.

A specific time interval between ² consecutive examinations was not defined. Progression can be measured at shorter intervals in younger patients and those who are at greater risk for progression.

The panel stated that for corneal cross-linking (CXL), it was important to document progression. However, at risk groups like children, adolescents and patients with advanced keratoconus could be considered for CXL without documented progression.

Corneal Cross-Linking (Cxl)

CXL involves use of riboflavin as photosensitizer and UV-A irradiation to initiate polymerisation and formation of interfibrillar and intrafibrillar carbonyl based collagen covalent bonds. This can be clinically identified as demarcation line in the anterior 250 to 300 microns of corneal stroma in first 3-months. However the significance of demarcation line as an indicator of clinical outcome is debated ². The beneficial effects of CXL in terms of corneal flattening have been found to last for years after procedure.³

Standard Dresden protocol involves central 8-10mm

epithelial debridement. 0.146% riboflavin-5-phosphate in 20% dextran ophthalmic solution is then applied for every 2-min for 30-min. At the end of 30-min, anterior chamber is checked for yellow flare and pachymetry is checked. Minimum corneal thickness of 400 microns is essential at this stage to prevent endothelial damage. 365 nm UV-A light at 3 mW/cm is irradiated for 30 min while continuing riboflavin instillation at 5-min intervals.

Dextran-Free Riboflavin

Corneal pachymetry tends to decrease while soaking with riboflavin in 20% dextran due to osmotic effect. 0.1% riboflavin-5-phosphate in HPMC is found to effectively achieve yellow flare while preventing reduction in pachymetry.⁴

Transepithelial Cxl

In order to eliminate complications resulting from epithelial debridement, several modifications have been proposed to standard riboflavin formulations. Increasing the concentration of riboflavin or addition of benzalkonium chloride/ethylenediaminetetraacetic acid/ vitamin E-TGPS can facilitate adequate transepithelial diffusion.⁵ Iontophoresis-assisted CXL uses low intensity electric current to allow diffusion of riboflavin through intact epithelium.⁶ Such formulations need to be thoroughly removed from the epithelial surface as they can interfere with UV-A transmission. However, the demarcation line achieved with transepithelial CXL is found to be fainter and superficial than standard CXL.⁷ Long term studies demonstrating stabilisation in previously progressive keratoconus is awaited.

Accelerated CXL

Based on Bunsen-Roscoe law of photochemical reciprocity, accelerated CXL uses higher irradiance of UV-A over shorter period to deliver equivalent total energy. Long UV-A exposure during standard protocol is considered a drawback of the procedure since it increases patient discomfort and causes corneal desiccation.⁸ Shetty et al. reported that the outcomes of 9 mW/cm for 10 min and 18 mW/cm for 5 min were similar to standard CXL.¹⁰ However 30 mW/

cm was not as efficacious. This was believed to be due to oxygen depletion in high fluence treatment. The Brunsen-Roscoe law is based on non-living physical systems. It's application in biological models is complicated by multiple confounding factors. High fluence treatment causes rapid oxygen depletion which takes approximately 30min for its replenishment. For photochemical reaction to occur, reactive oxygen species are indispensable.

Pulsed CXL

In order to replenish oxygen during high fluence treatment, pulsed CXL with on-off interval is proposed. Peyman et al. and Mazzotta et al. have demonstrated safety and efficacy of pulsed CXL with adequate depth of demarcation line.⁹

Customised CXL (CuRV)

CXL can be customised by modifying UV-A irradiance, total energy dose, pulsing or distribution of cross-link area. A greater total energy is delivered to cone area with the aim of inducing greater stiffness and maximum flattening. Additional treatment zones of lower energy are applied to surrounding area with the aim to stabilise that area. Multiple demarcation lines with varying depth may be observed correlating with the total used. Anterior corneal curvature and posterior corneal elevation are used as a guide to map the area of treatment. Additionally thinner corneas can be treated with less total energy for shorter periods to minimise endothelial damage.¹¹

Spectacles and contact lenses

Spectacles can be prescribed to patients with early disease in the absence of anisokenia. As the disease progresses, vision is affected considerably due to irregular astigmatism.

Soft contact lenses (SCL) used for keratoconus are thicker than conventional SCL (from 0.3 to 0.6 mm). This prevents them from adapting to irregular corneal surface, at the same time reducing oxygen permeability (DK). Keratoconus SCL also have adjustable peripheral curves and thinner peripheral zones to permit lens movement and increase DK. HydroCone (Toris K) (SwissLens, Prilly, Switzerland) and Kerasoft IC (Bausch & Lomb Inc., Rochester, NY) are available in high toric and spherical powers frequently

required for keratoconus patients.¹² Kerasoft IC gives the advantage of quadratic specific design that can be customised individually for periphery.

Rigid Gas Permeable Contact Lenses (RGPCLs) can be classified as corneal (8-10 mm) and intralimbal (10.5-12 mm). They are preferred for central and paracentral cones. Depending on the base curve, RGPCLs can be moncurve, bicurve, multicurve, reverse geometry lenses or specifically designed base curve e.g. Rose K, IKone.

Total diameters more than 12 mm can be divided into miniscleral and scleral lenses (figure 1). These lenses bear partially or totally on sclera and are preferred in keratoconus with decentered apex which cannot be fitted with other lenses. They need to be filled up with ophthalmic solution to prevent air bubble formation. When settled on the eye they should display central clearance of 200 microns.

Piggyback CL (figure 1) improve patient comfort and vision quality but have disadvantages like hypoxia and complicated handling of dual lenses. Hybrid contact lenses with rigid centre and soft periphery combine the advantages of both RGPCL and soft CL. Intrastromal Corneal Ring Segments

Table 1. Variety of ICRS

Name	Arc length (°)	Thickness (mm)	Inner diameter (mm)	Outer diameter (mm)	Profile
Intacs	150	0.25-0.45	6.8	8.1	Hexagonal
Intacs SK	150	0.40-0.45	6.0	7.3	Oval
Keraring	90-210	0.15-0.35	5.0	6.0	Triangular
MyoRing	360	0.15-0.35	5.0-8.0	5.0-8.0	Triangular

Intrastromal corneal ring segments (ICRS) are known to regularise cone and induce flattening of central cornea. Various ICRSs are available with varying characteristics (Table 1). Selection of type of rings, number of rings, location of insertion depends on patient parameters like topography, refractive error, location of cone, etc.

Patients planned for ICRS insertion should meet following criteria:

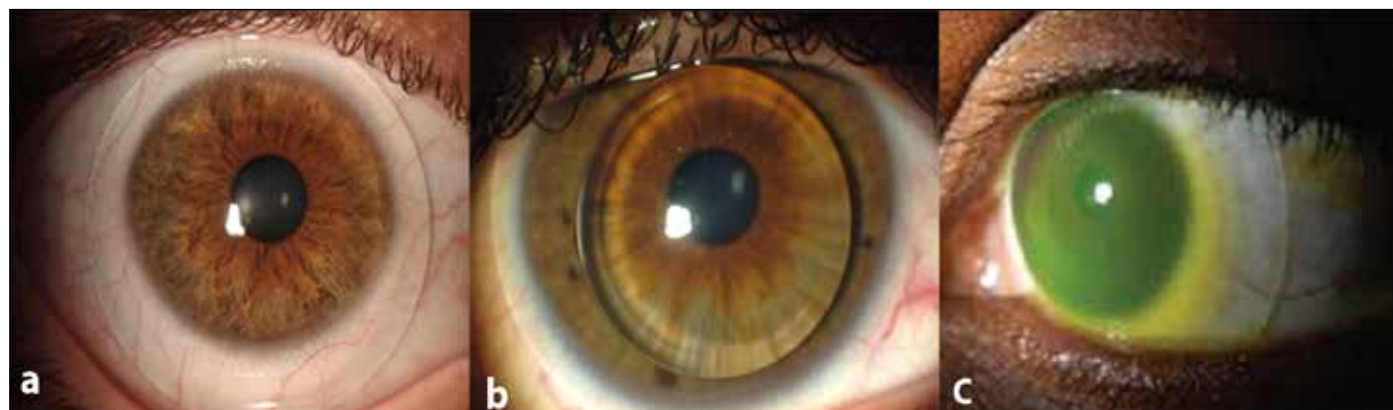
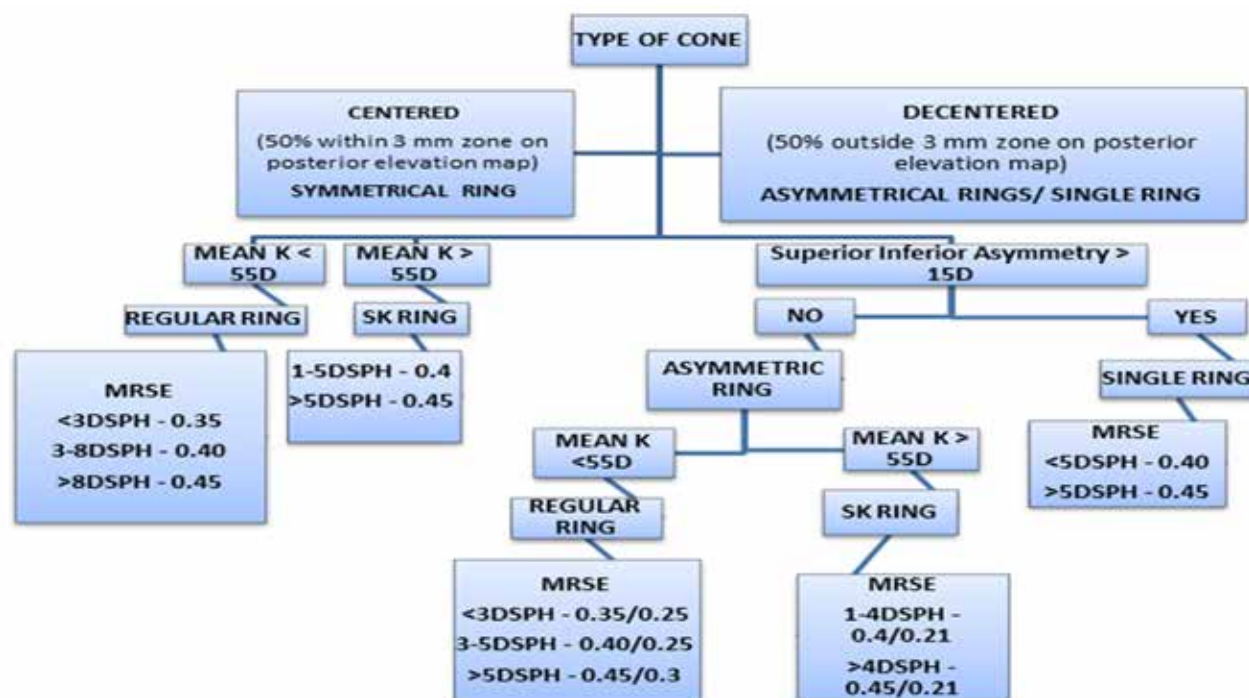


Figure 1: (a) Miniscleral lens (b) Piggyback lenses (c) Scleral lens for keratoconus



K = keratometry, SK = steep K, MRSE = mean refractive spherical equivalent

Figure 2: Nomogram for insertion of INTACS ring type and size.

1. Corrected distant visual acuity below 0.9 in decimal score
2. Intolerance to contact lens use
3. Absence of corneal scarring

CXL Plus

The channels are created at 70% to 80% depth of corneal thickness mechanically or preferably with femtosecond laser. The corneal incision for insertion is made on temporal side of cornea or on the steepest meridian. The outcomes are predictable and favourable with proper preoperative planning, use of femtosecond laser and stable form of disease. Shetty et al. has described nomogram for insertion of INTACS ring size and type to guide preoperative planning in keratoconus patients (Figure 2).¹³

The term CXL plus is used when CXL is performed in combination with various other refractive procedures viz. ICRS implantation, photorefractive keratectomy, phakic IOL implantation, etc for the treatment of keratoconus. CXL when combined with topography guided PRK has advantage of improving functional visual outcome in addition to increasing corneal stability. The main advantages of simultaneous PRK and CXL over sequential topography-guided PRK after CXL in keratoconus treatment are: the cross-linked portion of the cornea remains unaffected by laser ablation and the probable stromal scarring occurring due to PRK alone is minimized.²⁵

For designing this combined procedure, it is important to consider ablation depth and postoperative corneal thickness. Based on preoperative corneal pachymetry reading, CDVA,

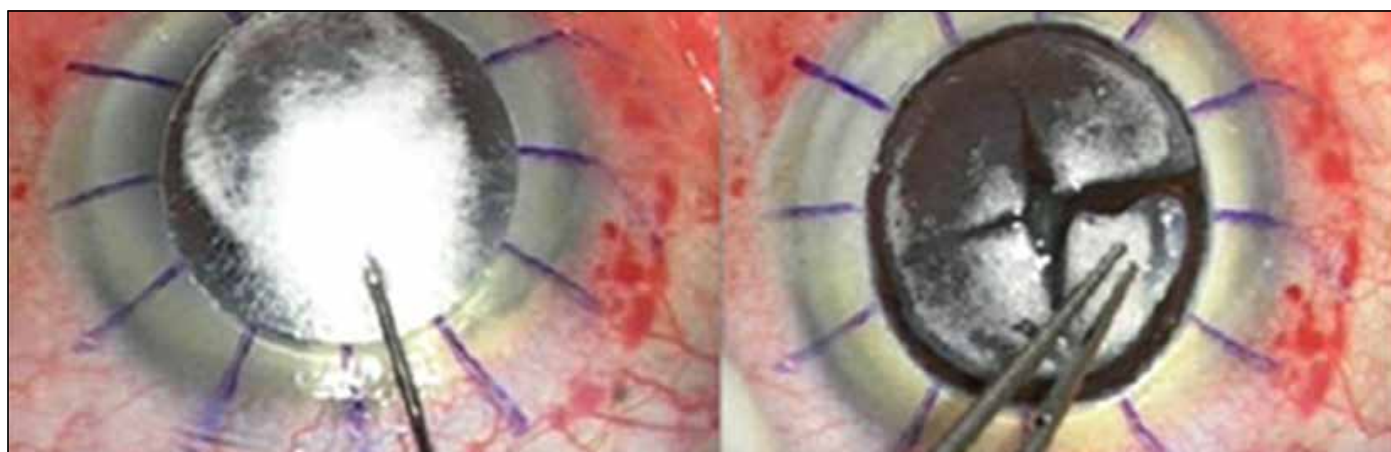


Figure 3: Big Bubble Technique for DALK

and ablation depth treatment procedure has to be modified. A maximum ablation depth of 50 μm and a minimal post-operative corneal thickness of 350 μm were recommended by Kanellopoulos²⁶ whereas, a maximum ablation depth of 60 μm and minimal corneal thickness of 450 μm following PRK was suggested by Stojanovic et al.²⁷ Use of 0.02% mitomycin C following laser ablation during PRK has also been described.

Keratoplasty

Approximately 12 - 20% patients with keratoconus eventually require corneal transplant.¹⁴ Patients with advanced keratoconus not amenable to visual rehabilitation with other modalities are considered for keratoplasty with different techniques.

Penetrating keratoplasty (PK) has been conventionally performed for advanced keratoconus. However due to slow visual rehabilitation, higher rates of rejection, longer course of steroid, residual stigmatism, anisometropia and higher incidence of postoperative glaucoma, deep anterior lamellar keratoplasty (DALK) is considered the treatment of choice. Patients with deep central corneal scarring benefit from full thickness PK. With the advent of femtosecond laser, the outcomes of PK have improved due to precise donor and recipient corneal cuts, improved alignment and better wound stability.¹⁵

The advantages of DALK over conventional PK include endothelial preservation, lower rates of rejection, advantages of larger graft, shorter postoperative course of steroids, lesser incidence of cataract and glaucoma. The term "deep lamellar keratoplasty" (DLK) was first applied by Archila¹⁶ who showed that injecting air into the stroma can facilitate the removal of the host tissue. The different techniques of DALK include layer-by-layer manual dissection, Anwar's big-bubble, viscoelastic dissection, hydrodelamination, and femtosecond laser-assisted DALK.¹⁷

The layer-by-layer method is used in those with stromal scarring and is a time-consuming approach.¹⁸ In the Archila technique, air is injected into the cornea until it is opaque, then a deep incision down to the DM is made such that a layer of stroma is maintained to protect the DM.¹⁹ In the Melles technique, the aqueous in the anterior chamber is completely replaced with an air bubble. The difference between the refractive indices of air and the corneal tissue creates a mirror image which helps determine the depth of the incision and location of the DM.²⁰ The big bubble technique, which was introduced by Anwar and Teichmann,²¹ constitutes the injection of air deep into the stroma, and the surface of DM appears smooth after removing the stroma. The air is injected slowly until a large bubble is formed, and then, the anterior two-thirds of the cornea is debulked using a crescent blade. With viscoelastic dissection, the anterior stroma is removed, and then air is injected into the anterior chamber, and finally, the posterior stroma is separated from the DM using an ophthalmic viscoelastic device (OVD).²² During the hydrodelamination technique, which was described by Sugita and Kondo,²³ a saline solution is injected into the cornea to separate the stroma, and then lamellar dissection is done deep down to the DM.

The use of femtosecond laser in DALK allows lamellar incisions at precise depths, accurate side cuts, secure wound closure and faster suture removal.

Bowman Layer Transplantation

Fragmentation of Bowman layer is a commonly observed in patients with advanced keratoconus. Bowman layer transplantation is a procedure described for advanced and progressive keratoconus. The procedure involves transplantation of isolated donor Bowman layer into the midstromal layer of diseased cornea. This induces wound healing reaction, causes flattening and prevents further progression. Since the graft is acellular in nature and procedure is sutureless, the risks of rejection and suture related complications are minimal. Though the procedure is surgically challenging, it remains a promising alternative in patients with advanced forms of disease. Use of femtosecond laser and intraoperative OCT can help overcome steep surgical curve and enable Bowman Layer Transplantation to become widely accepted procedure.²⁴

The authors have no potential conflict of interest in the subject matter described above.

References

- Gomes J AP, Tan D, Rapuano C, Belin M, Ambrósio R, Guell J et al. Global consensus on keratoconus and ectatic diseases. *Cornea* 2015;34:359-69.
- Malhotra C, Jain AK, Gupta A, Ram J, Ramachandirane B, Dhingra D, Sachdeva K, Kumar A. Demarcation line depth after contact lens-assisted corneal crosslinking for progressive keratoconus: Comparison of dextran-based and hydroxypropyl methylcellulose-based riboflavin solutions. *J Cataract Refract Surg.* 2017 Oct;43(10):1263-70.
- Balparda K, Maldonado MJ. Corneal collagen cross-linking. A review of its clinical applications. *Arch Soc Esp Ophthalmol.* 2017 Apr;92(4):166-74.
- Ehmke T, Seiler TG, Fischinger I, Ripken T, Heisterkamp A, Frueh BE. Comparison of Corneal Riboflavin Gradients Using Dextran and HPMC Solutions. *J Refract Surg.* 2016 Dec;32(12):798-802.
- Kır MB, Türkyılmaz K, Öner V. Transepithelial corneal crosslinking in treatment of progressive keratoconus: 12 months' clinical results *Curr Eye Res.* 2017 Jan;42(1):28-31.
- Jia HZ, Pang X, Fan ZJ, Li N, Li G, Peng XJ. Iontophoresis-assisted corneal crosslinking using 0.1% riboflavin for progressive keratoconus *Int J Ophthalmol.* 2017 May;10(5):717-22.
- Bonnel S, Berguiga M, De Rivoire B, Bedubourg G, Sendon D, Froussart-Maille F, Rigal-Sastourne JC. Demarcation line evaluation of iontophoresis-assisted transepithelial corneal collagen cross-linking for keratoconus. *J Refract Surg.* 2015 Jan;31(1):36-40.
- Razmjoo H, Peyman A, Rahimi A, Modrek HJ. Cornea Collagen Cross-linking for Keratoconus: A Comparison between Accelerated and Conventional Methods. *Adv Biomed Res.* 2017 Feb;6:10.
- Jiang LZ, Jiang W, Qiu SY. Conventional vs. pulsed-light accelerated corneal collagen cross-linking for the treatment of progressive keratoconus: 12-month results from a prospective study. *Exp Ther Med.* 2017 Nov;14(5):4238-44.
- Shetty R, Pahuja N, Roshan T, Deshmukh R, Francis M, Ghosh A, Sinha Roy A. Customized Corneal Cross-linking Using Different UVA Beam Profiles. *J Refract Surg.* 2017 Oct;33(10):676-82.
- Seiler TG, Fischinger I, Koller T, Zapp D, Frueh BE. Customized Corneal Cross-linking: One-Year Results. *Am J Ophthalmol.* 2016 Jun;166:14-21.
- Su S, Johns L, Rah MJ, Ryan R, Barr J. Clinical performance of

- KeraSoft IC in irregular corneas. *Clin Ophthalmol.* 2015 Oct 22;9:1953-64.
- 13 Rohit Shetty, Sharon D'Souza, Sarika Ramachandran, Mathew Kurian, Rudy M M A Nuijts. Decision making nomogram for intrastromal corneal ring segments in keratoconus. *Indian J Ophthalmol.* 2014. 62; 1: 23-28.
 - 14 Fogla R. Deep anterior lamellar keratoplasty in the management of keratoconus. *Indian J Ophthalmol* 2013;61:465-8.
 - 15 Fung SS, Aiello F, Maurino V. Eye (Lond). Outcomes of femtosecond laser-assisted mushroom-configuration keratoplasty in advanced keratoconus. 2016 Apr;30(4):553-61.
 - 16 Archila EA. Deep lamellar keratoplasty dissection of host tissue with intrastromal air injection. *Cornea.* 1984-85;3:217-8.
 - 17 Karimia F, Feizi S. Deep Anterior Lamellar Keratoplasty: Indications, Surgical Techniques and Complications Middle East Afr J Ophthalmol. 2010 Jan-Mar; 17(1): 28-37.
 - 18 Tsubota K, Kaido M, Moden Y, Satake Y, Bissen-Miyajima H, Shimazaki J. A new surgical technique for deep lamellar keratoplasty with single running suture adjustment. *Am J Ophthalmol.* 1998;126:1-8.
 - 19 Archila EA. Deep lamellar keratoplasty dissection of host tissue with intrastromal air injection. *Cornea.* 1984-85;3:217-8.
 - 20 Melles GR, Rietveld FJ, Beekhuis WH, Binder PS. A technique to visualize corneal incision and lamellar dissection depth during surgery. *Cornea.* 1999;18:80-6.
 - 21 Anwar M, Teichmann KD. Big-bubble technique to bare Descemet's membrane in anterior lamellar keratoplasty. *J Cataract Refract Surg.* 2002;28:398-403.
 - 22 Melles GR, Lander F, Rietveld FJ, Remeijer L, Beekhuis WH, Binder PS. A new surgical technique for deep stromal, anterior lamellar keratoplasty. *Br J Ophthalmol.* 1999;83:327-33.
 - 23 Sugita J, Kondo J. Deep lamellar keratoplasty with complete removal of pathological stroma for vision improvement. *Br J Ophthalmol.* 1997;81:184-8.
 - 24 Tong CM, van Dijk K, Melles GRJ. Update on Bowman layer transplantation. *Curr Opin Ophthalmol.* 2019 Jul;30(4):249-255.
 - 25 Al-Mohaimed MM. Combined corneal CXL and photorefractive keratectomy for treatment of keratoconus: a review. *Int J Ophthalmol.* 2019;12(12):1929-1938.
 - 26 Kanellopoulos AJ. Comparison of sequential vs same-day simultaneous collagen cross-linking and topography-guided PRK for treatment of keratoconus. *J Refract Surg.* 2009;25(9):S812-S818
 - 27 Stojanovic A, Zhou W, Utheim TP. Corneal collagen cross-linking with and without epithelial removal: a contralateral study with 0.5% hypotonic riboflavin solution. *Biomed Res Int.* 2014;2014:619398.

Cite This Article as: Choksi Twinkle; Sahdev Saroj, Pawar Rajendra, Keratoconus: Available Treatment Options Delhi Journal Ophthalmology 2020 ; 31 (3) :13 - 17.

Acknowledgments: Nil

Conflict of interest: None declared

Source of Funding: None

Date of Submission: 20 June 2020

Date of Acceptance: 29 June 2020

Address for correspondence

Twinkle Choksi, Assistant Professor MD (Ophthalmology) FICO DNB FCAS

Department of Ophthalmology
TNMC and BYL Nair Ch. Hospital,
Mumbai India.

Email: parmar.twinkle@yahoo.com



Quick Response Code