

# A Unique Presentation of Meibomian Gland Carcinoma

Ashish Kumar Pandey, Anirudh Singh, Mansur Ali Khan Anjali Maheshwari

Department of Ophthalmology, Command Hospital, Old Air Port Road, Bangalore, India.

## Abstract

**Background:-** The sebaceous gland carcinoma is a lethal highly malignant slow-growing tumor of the eyelid arising from meibomian glands, glands of Zeis, sebaceous glands of caruncle, and periocular skin. It is third most common malignancy of the eyelid and the incidence rate is about 1-1.5%.<sup>1</sup> We report a unique case of meibomian gland carcinoma which was a diagnostic challenge due to its unusual presentation. Case Report 62 year old male presented with solitary painless slowly growing mass left upper eyelid of 6 months duration. Incisional biopsy revealed basal cell carcinoma. Wide local excision was performed and defect closed with primary suturing. Biopsy of the mass revealed meibomian gland carcinoma with positive medial and lateral margins. Second surgery was performed in which wider local excision was done including medial canthus. Defect of 3.5 cm was closed with Tenzel's flap. Conclusion: The case is being reported for highlighting the unusual presentation of the meibomian gland carcinoma as a slow growing swelling and confusing nature of the histopathology reports.

Delhi J Ophthalmol 2021; 31; 63-66; Doi <http://dx.doi.org/10.7869/djo.627>

Keywords: Carcinoma, Meibomian gland, Pagetoid, Sebaceous gland.

## Introduction

The sebaceous gland carcinoma is a lethal highly malignant slow-growing tumour of the eyelid arising from meibomian glands, glands of Zeis, sebaceous glands of caruncle, and periocular skin. It is third most common malignancy of the eyelid and the incidence rate is about 1-1.5%.<sup>1</sup> Prevalence is more in elderly individuals, usually females with a predilection in the upper lid where meibomian glands are numerous. Clinical diagnosis is very important in early stage and more difficult as it mimics chalazion or blepharoconjunctivitis. Intraepithelial spread and the ability to cause skipped lesions gives a special feature from other lid tumors. The upper eyelid is the site of origin in about two-thirds of all cases, but sebaceous gland carcinoma may arise from any of the periocular structures previously mentioned<sup>2</sup> and may have a variety of clinical appearances. The carcinoma may exhibit multicentric spread to the other eyelid, conjunctiva or corneal epithelium. This neoplasm may spread through the canaliculus to the lacrimal excretory system and even to the nasal cavity.<sup>3</sup> Dysplasia and anaplasia of the sebaceous lobules in the meibomian glands are exhibited by sebaceous gland carcinoma, with associated destruction of tarsal and adnexal tissues. Typically, sebaceous gland carcinoma shows highly pleomorphic cells arranged in lobules or nests with hyperchromatic nuclei and vacuolated (foamy or frothy) cytoplasm due to a high lipid content. Histologically, sebaceous gland carcinoma may resemble the appearance of squamous cell carcinoma. However, the cytoplasm in sebaceous gland carcinoma tends to be more basophilic compared with the eosinophilic appearance of squamous cell carcinoma.

## Case Report

62 years old male with no known comorbidities, no history of smoking presented with complaints of swelling/ mass over left upper eyelid of 6 months duration which was insidious in onset and gradually progressive and initially painless. Mass was causing partial closure of the eyelid. Later he

developed mild pain for last 1 week. Patient was earlier diagnosed as a case of recurrent chalazion. On evaluation his best corrected visual acuity right eye is 6/9 and left eye is 6/12. Patient had a mass in the left upper eyelid extending horizontally from midpoint of upper eyelid to medial canthus measuring 10 mm and vertically measuring 5 mm above upper lid margin (Figure 1). Mass was smooth, oval shaped, horizontally oriented, non lobulated with well defined margins, which was merging with the free border of upper eyelid inferiorly and to the tarsal plate superiorly. On Palpation there was no tenderness, mass was mobile in side to side and up and down position, skin over the mass was shiny but no excoriation was present. Transillumination test was negative and no ulcerations. Upper lid margin showed loss of eyelashes, poliosis and trichiasis. Anterior segment examination revealed immature senile cataract in both eyes. Rest of the anterior segment and posterior segment examination of both eyes were within normal limit. On initial assessment, the mass was diagnosed as a case of recurrent chalazion, however possibility of malignancy was also taken

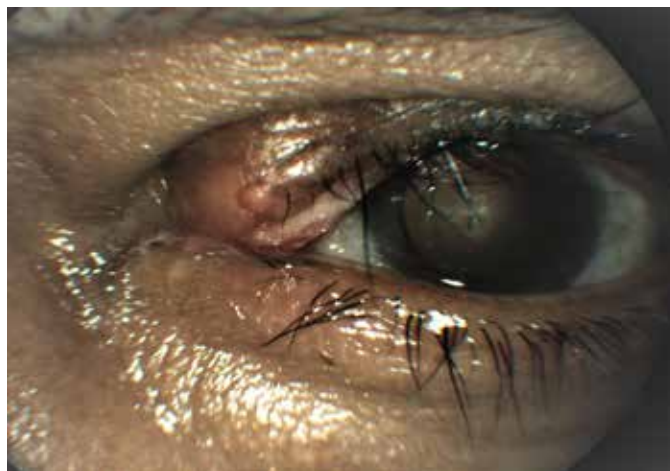

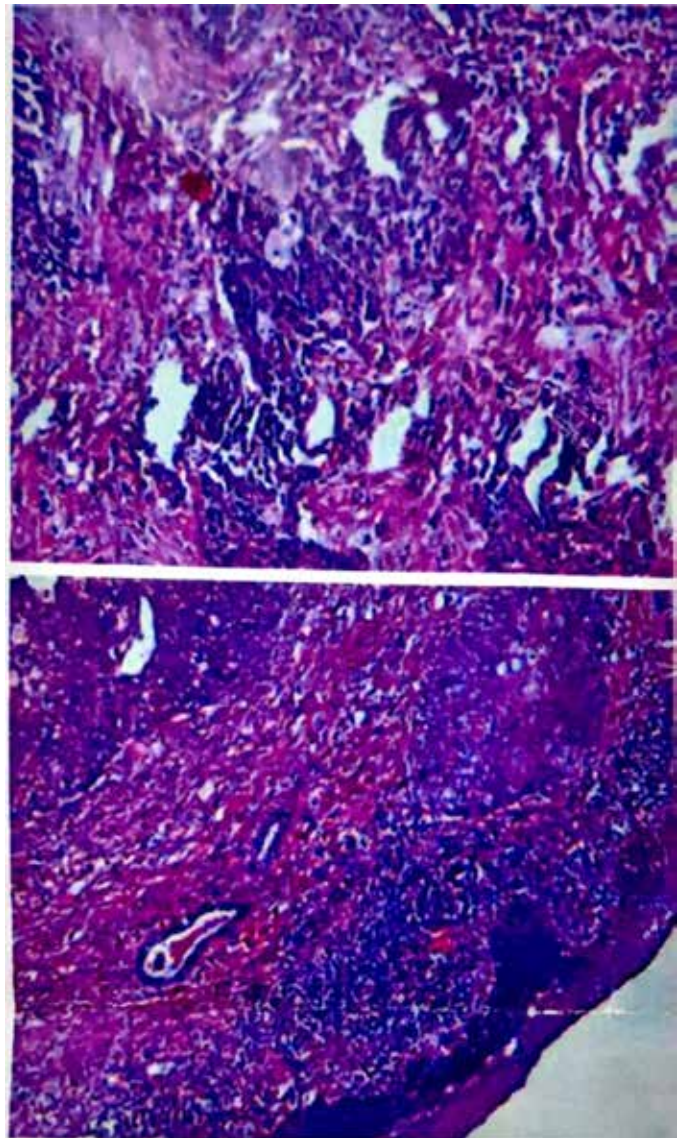
Figure 1: pre operative appearance of the mass in left upper eyelid (meibomian gland carcinoma)

into consideration. On Systemic examination there was no regional or systemic lymphadenopathy. Management of this patient was done in 3 steps as mentioned below.

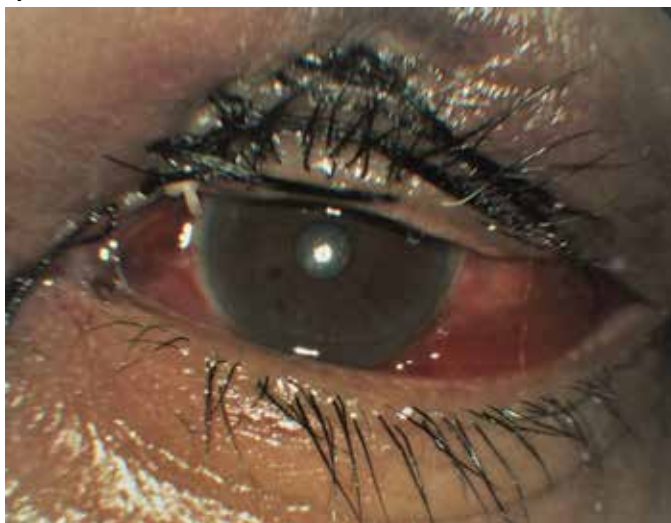
**Step 1:-** Incisional biopsy was performed to identify the mass. Biopsy report revealed basal cell carcinoma with sebaceous differentiation. To further confirm the diagnosis immunohistochemistry was done which showed epithelial membrane antigen (EMA) and p40 protein positive, suggestive of basaloid squamous carcinoma. Sebaceous gland carcinoma was kept as second differential diagnosis. CECT chest and abdomen was within normal limit. PET CT showed no evidence of metastasis, no abnormally enhancing lesion in left upper eyelid region.

**Step 2:-** After the incisional biopsy report it was decided to perform wide local excision of the mass. Wide local excision was done with 5 mm margin under local anaesthesia. Extent of excision was decided intraoperatively on the basis of clinical appearance of clear margins. Excision led to a horizontal defect of 20 mm. In view of suspected squamous/sebaceous cell carcinoma conjunctival map biopsy was done. Lateral canthotomy was performed and closure of the defect done with primary suturing (Figure 2). Histopathology of the mass showed meibomian gland carcinoma with pagetoid spread and positive medial and lateral margins. (Figure 3). Conjunctival map biopsy was negative for any carcinoma.

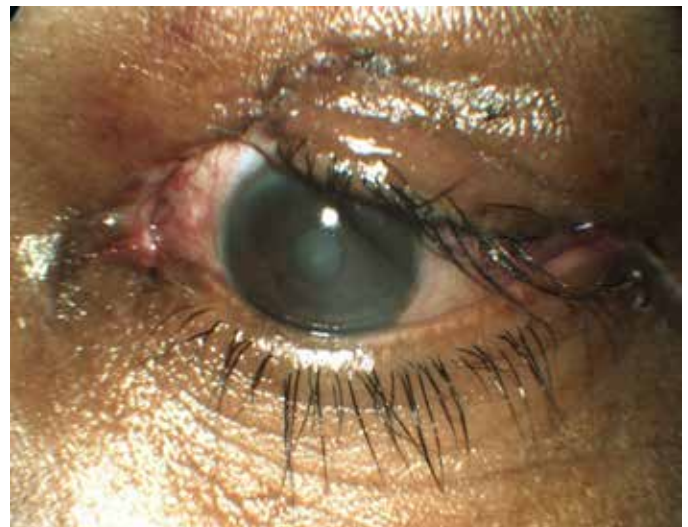
**Step 3:-** In view of positive margins of the mass on histopathology, a second surgery was planned in which wide local excision of the margins were done, caruncle was removed and part of levator palpebrae superioris was excised. Simultaneously frozen section was performed to get a clear margin. After the excision of the margins a defect of 3.5 cm was left. It was not possible to close the defect with primary suturing because of previous surgery, hence the defect was closed with Tenzel's semilunar flap. (Figure 4) The patient was followed up after two weeks and the flap was well taken up with partial movement of the upper eyelid.



**Figure 3:** Histopathology of the lesion which shows meibomian gland carcinoma with pagetoid spread



**Figure 2:** post operative day 1 appearance of upper eyelid after wide local excision and lateral canthotomy



**Figure 4:** Post operative appearance of eye after second surgery in which wider local excision was performed and defect was closed with Tenzel's flap

Since the histopathology of the lesion showed meibomian gland carcinoma with pagetoid spread, opinion of oncophysician was sought for adjuvant treatment. In view of negative conjunctival map biopsy and no evidence of metastasis on PET scan, no adjuvant therapy was given to the patient. 08 months post operatively, patient recovered well, there is no clinical or radiological evidence of tumour activity. Clinically patient has good levator function (Figure 5) and PET scan was within normal limit with no hotspots (Figure 6).

### Discussion

Meibomian gland carcinoma is a slow-growing tumour arising from the meibomian glands. It is the third most common malignancy in the eyelid with an incidence of 1-5.5% of eyelid malignancies. Some studies show an increased incidence of sebaceous gland carcinoma in the Asian population. The tumour has a poor prognosis when compared to other eyelid malignancies because of delayed diagnosis, as it is frequently mistaken for blepharoconjunctivitis or a chalazion.<sup>4,5,6</sup> Therefore, any recurrent chalazion or unilateral blepharoconjunctivitis in elderly individuals with features like a loss of lashes should be biopsied.

The diagnosis of sebaceous gland carcinoma of the periorbital region is often delayed. Histopathologically it mimics squamous cell carcinoma or basal cell carcinoma. Sebaceous gland carcinoma arises from meibomian gland, sebaceous gland or from gland of Zeis. Histopathologically sebaceous carcinoma can spread within the epidermis in a single-cell fashion (pagetoid spread), can mimic squamous cell carcinoma in situ<sup>10</sup> or basal cell carcinoma.

Immunohistochemistry plays a key role in the histological differentiation between sebaceous cell carcinoma, basal cell carcinoma and squamous cell carcinoma. In a study by Sramek et.al,<sup>11</sup> it was found that two important stains can distinguish between the three. EMA, Ber-EP4. Both EMA and Ber-EP4 positive immunophenotype supports sebaceous carcinoma, EMA positive, Ber-EP4 negative supports squamous cell carcinoma and EMA negative, Ber-EP4 positive supports basal cell carcinoma.

Treatment of sebaceous gland carcinoma is primarily surgical. Treatment options include surgery which ranges from wide local excision for local tumour to exenteration of orbit. Radical surgical excision with frozen section control by a standard method or Mohs micrographic surgery is the most common and effective method of treatment.

An excision of 4-5 mm of normal tissue carries very good prognosis.<sup>7</sup> Approximately, 30% of Sebaceous gland carcinoma recur after resection.<sup>8</sup> Other modalities of treatment are mitomycin C, cryotherapy, and radiotherapy.<sup>9</sup> Radical neck dissection is required if there is involvement of regional lymph nodes. Distant metastasis requires adjuvant chemotherapy and radiotherapy.

The mortality rate is 5-10% because of delay in making diagnosis and delay in the treatment. The distant metastasis

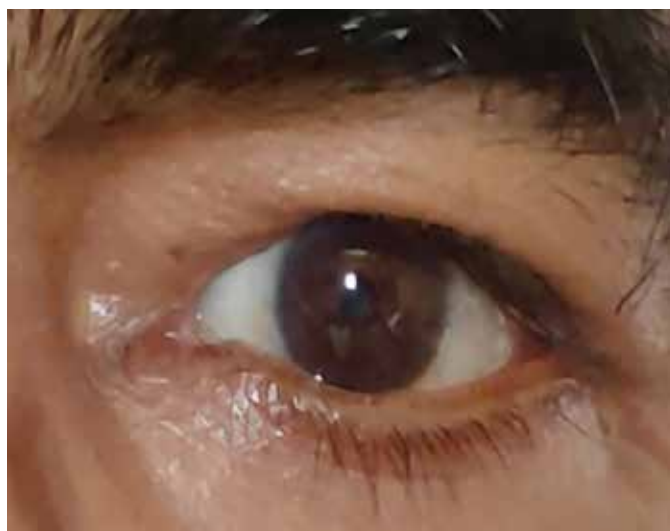

Figure 5: Eight months post operative picture, showing good levator function and no residual tumour

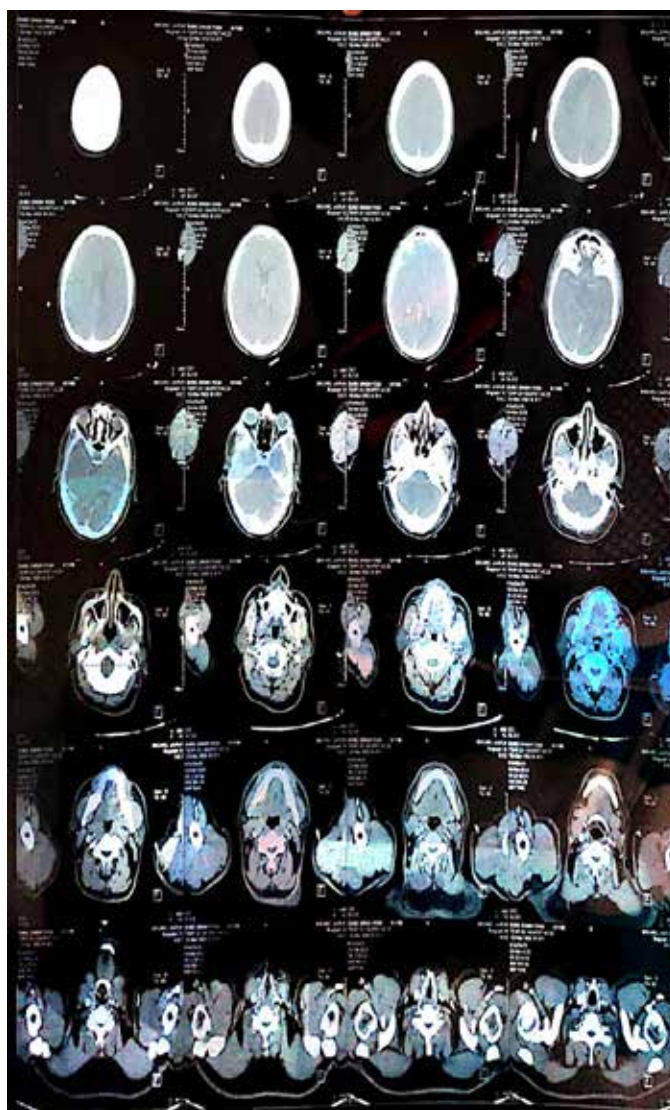


Figure 6: PET scan report of the patient showing no hotspots, 08 months post operatively.

carries 25% of mortality rate. The poor prognostic factors are involvement of upper or both eyelids and, tumour size of 10 mm or more. Other prognostic factors are symptoms of more than 6 months (mortality 38%), poorly differentiated tumour, orbital extension, pagetoid spread, infiltration into blood vessel and lymphatics and multicentric origin. Tumours <6 mm have an excellent prognosis. This case is reported to highlight the indolent presentation of the carcinoma, with smooth margins, non lobulated appearance, no fixity to underlying structure, no metastasis.

### References

1. Ni C, Kou PK. Meibomian gland carcinoma: A clinicopathological study of 156 cases with long-period follow up of 100 cases. *Jpn J Ophthalmol* 1979;23:388-401.
2. Font RL. Eyelids and lacrimal drainage system. In: Spencer WH, editor. *Ophthalmic Pathology: An Atlas and Textbook*. 4th ed., Vol. 4. Philadelphia, PA: WB Saunders; 1996. p. 2218-433
3. Khan JA, Grove AS Jr, Joseph MP, Goodman M. Sebaceous carcinoma. Diuretic use, lacrimal system spread, and surgical margins. *Ophthalm Plast Reconstr Surg* 1989;5:227-34
4. Foster CS, Allansmith MR. Chronic unilateral blepharoconjunctivitis caused by sebaceous carcinoma. *Am J Ophthalmol* 1978;86:218-20.
5. Sweebe EC, Cogan DG. Adenocarcinoma of the Meibomian gland; a pseudochalazion entity. *AMA Arch Ophthalmol* 1959;61:282-90.
6. Condon GP, Brownstein S, Codère F. Sebaceous carcinoma of the eyelid masquerading as superiorlimbic keratoconjunctivitis. *Arch Ophthalmol* 1985;103:1525-9.
7. Muqit MM, Roberts F, Lee WR, Kemp E. Improved survival rates in sebaceous carcinoma of the eyelid. *Eye (Lond)* 2004;18:49-53.
8. Epstein GA, Putterman AM. Sebaceous adenocarcinoma of the eyelid. *Ophthalmic Surg* 1983;14:935-40.
9. Wali UK, Al-Mujaini A. Sebaceous gland carcinoma of the eyelid. *Oman J Ophthalmol* 2010;3:117-21.
10. Pickford MA, Hogg FJ, Fallowfield ME, Webster MH. Sebaceous carcinoma of the periorbital and extraorbital regions. *Br J Plast Surg*. 1995;48:93-96.
11. Sramek B, Lisle A, Loy T. Immunohistochemistry in ocular carcinomas. *Journal of cutaneous pathology*. 2008 Jul;35(7):641-6.

**Cite This Article as:** Ashish Kumar Pandey, Anirudh Singh, Mansur Ali Khan Anjali Maheshwari, A Unique Presentation Of Meibomian Gland Carcinoma, *Delhi Journal Ophthalmology* 2020;31(3):63-66.

**Acknowledgments:** Nil

**Conflict of interest:** None declared

**Source of Funding:** None

**Date of Submission:** 17 April 2020

**Date of Acceptance:** 06 May 2020

### Address for correspondence

**Ashish Kumar Pandey**

Senior Resident

Department of Ophthalmology

Command Hospital

Old Air Port Road

Bangalore, India.

Email: ashishdoc252@gmail.com



Quick Response Code