

# Case series of Ectopia Lentis associated with Marfan's syndrome

Sagarika Laad, Harpal Singh, Satendra Singh, Parag Ramnani, Shashank Gupta, Ritu Gupta

Department Of Ophthalmology, Peoples College Of Medical Sciences And Research Center Bhanpur, Bhopal, India.

**Purpose:** To report 4 cases of Marfan's syndrome with ectopia lentis.

**Methods:** Case 1- Fifty year old woman presented with sudden painless diminution of vision both eye since 1 day with history of blunt trauma by wood-log. Vision was counting finger 3 feet in both eyes, small pupil with sluggish reactions and posteriorly dislocated lens. B-scan showed posterior dislocation of lens in both eyes with retinal detachment in right eye. Case 2- Two sisters aged 15 and 12 year also presented with superotemporal subluxation of lens. Best corrected vision was 6/12 both eye in younger one and 6/9 in right and 6/12 in left eye of elder one. Case 3- A 22 year old male reported with painless diminution of vision since childhood. Vision was 1/60 in right and 6/60 in left eye. Anterior segment shows lens in anterior chamber in right eye and superonasal subluxation of lens in left eye. All patients presented with typical features of Marfan's syndrome like tall-statured with long, thin extremities; arachnodactyly, prognathis and a high arched palate.

## Abstract

**Results:** Case 1 improved with +10 D lens in left eye and no improvement in right as there was Retinal detachment present. She was referred to vitreoretinal surgeon. Case 2 are under observation and managed conservatively. Case 3 is also referred to vitreoretinal surgeon. **Conclusion-** Ectopia lentis is reported as most common feature in Marfan's syndrome. Though posterior dislocation is rarely reported. There should be multifaceted approach to manage such cases and prevent sight-threatening complication.

Delhi J Ophthalmol 2021;31; 87-89; Doi <http://dx.doi.org/10.7869/djo.635>

**Keywords:** Marfan's, Ectopia Lentis, Visual Outcome

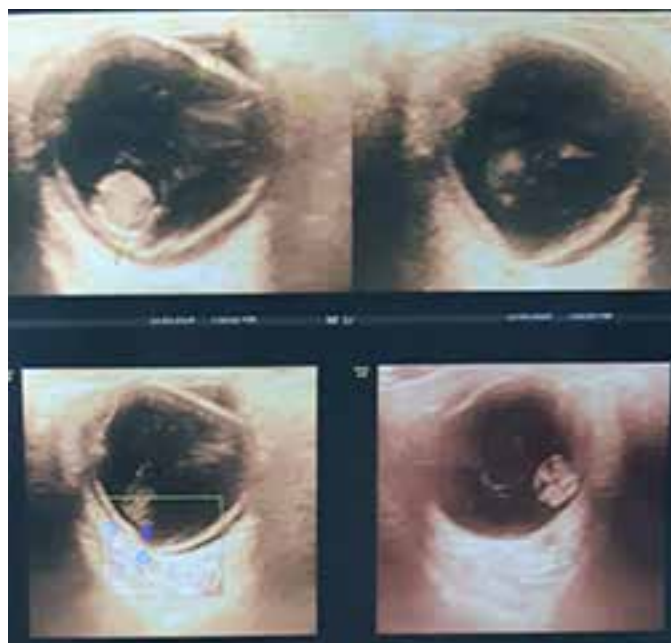
## Introduction

Marfan's Syndrome has been estimated to occur in 4 to 6 person per 100000 of population.<sup>1</sup> Ophthalmic features of this syndrome have been frequently reported.<sup>2</sup> Ectopia lentis, the commonest ocular feature, occurs in 70 to 80 % of cases. Reports on isolated spontaneous complete posterior dislocation lying over the retina, or producing secondary complications like glaucoma or uveitis exist in literature.<sup>3</sup> However, bilateral posterior dislocation is a rare feature. In our study we reported 4 cases of Marfan's Syndrome with ectopia lentis including case of post traumatic posterior dislocation lens.

Ectopia lentis is an acquired or hereditary condition in which lens is displaced from its natural position because of defects in the zonular filament. Karl Stellwag, an ophthalmologist from Austria, first formulated the term in 1856 and identified the lens movement within its normal space.<sup>4</sup> The Danish national survey carried out in 1993 showed that an estimated 6.4 per 100,000 individuals had ectopia lentis, of which mostly associated with syndrome.<sup>5</sup> Typically, ectopia lentis is associated with some acquired causes, such as trauma, inflammation, and hyper mature cataract. Although acquired causes are common, Williams postulated its genetic predisposition in 1875 and linked ectopia lentis to two generations in a family.<sup>6</sup> Genetic mutations, as in the case of Marfan syndrome (fibrillin1-gene), have been strongly associated with lens Subluxation with a rate of up to 60% of the cases because of a structural defect in the ciliary zonules.<sup>7</sup>

**Case 1 :-** A 50 year old woman presented with complain of sudden painless diminution of vision both eye since 1 day with history of blunt trauma over forehead. On ocular

examination, vision was counting finger 3 feet in both eyes, slit lamp examination reveals normal cornea and anterior chamber, small pupil with sluggish reactions. Central fundus showed posterior dislocation of lens at 6 o' clock, rest details were normal. B-scan revealed hyperechoic circular substance in both eyes, suggested posterior dislocation of lens. Also, separation between retina and sclera with clear subretinal space suggested retinal detachment in right eye. (Figure 1) Patient was improved to 6/9 with +10D in left eye



**Figure 1:** B-scan Picture showing retinal detachment with posteriorly dislocated lens

and no improvement in right eye. As B-scan revealed Retinal detachment in right eye, she referred to Vitreo-retinal surgeon for further management.

**Case2:-** Two girls aged 12 and 15 years, came for routine checkup. Their best corrected vision was 6/12 both eye in younger one and 6/9 in right and 6/12 in left eye of elder one. On ocular examination, revealed both having superotemporal subluxation of lens. Rest anterior segment and posterior segment was normal.

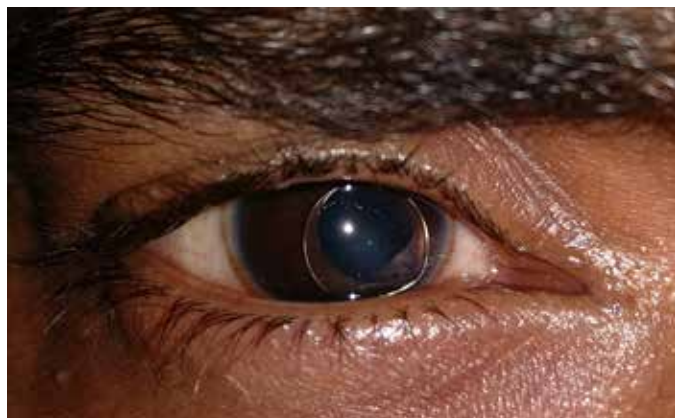
**Case 3:-** A 22 year old male came with complains of diminution of vision since childhood. No history of trauma or any relevant history. Best corrected visual acuity in right eye was 1/60 and in left eye 6/60. On ocular examination, right eye showed the entire crystalline lens in anterior chamber pushing the iris backwards with mid dilated fixed, irregular pupil (Figure 2). In left eye, there was superonasal subluxation with no visible zonules (Figure 3). Fundus in both eyes was grossly normal as details were not visible. Right eye lens-extraction was performed, and post-operative vision was 6/36 with +10D spherical. Left eye was kept under observation.

All 4 patients had family history of similar complain.. According to Ghent criteria's the presence of ectopia lentis and family history of Marfan syndrome is sufficient for diagnosis

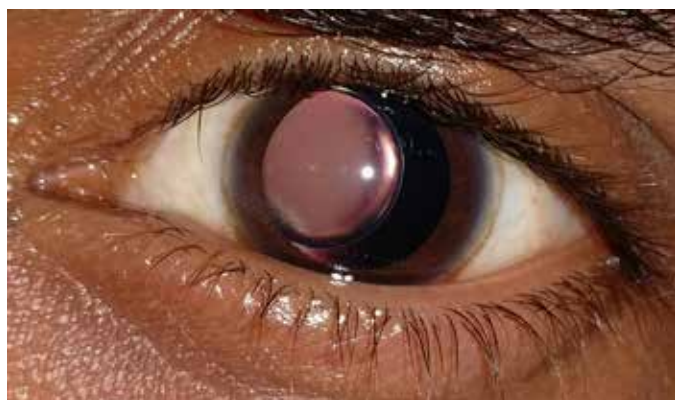
of Marfan syndrome. Although cardiac examination was not permitted by patient thus not done. The score calculated on the basis of revised Ghent criteria's systemic score was  $\geq 7$  (wrist and thumb sign, hind-foot deformity, reduced elbow extension and facial features including malar hypoplasia, dolichocephaly, prognathism, high-arched palate) which was suggestive for Marfan's syndrome.

### Discussion

Ocular involvement is the commonest feature of Marfan's Syndrome. Of which ectopia lentis is estimated to occur in 50-80% of the patients. It usually remains stable in early childhood, and progresses in second decade, when it may produce pupillary block glaucoma and uveitis. In subluxation, the zonules are broken from the equator, resulting in displacement of lens from its position, whereas in ectopia lentis, due to zonular laxity, lens gets moved from its position. Lenticular displacement in Marfan's syndrome has been termed as ectopia lentis and not Subluxation of lens. This hypothesis cannot explain complete anterior or posterior dislocation, both of which have been reported in this syndrome. Though Posterior dislocations is rare, only 3% patients is reported.<sup>8</sup> Anterior dislocation is usually symptomatic, presents with pupillary block glaucoma or secondary uveitis. Posterior dislocation is silent and rarely causes glaucoma or uveitis. Also, the vitreous changes are well explained in Marfan's Syndrome.<sup>9</sup> Liquefaction of the gel and posterior vitreous detachment is reported. Disruption of anterior hyaloid phase results in loss of support which in turn augment the posterior dislocation of lens. Lens dislocation can be due to high-intensity trauma, hereditary ocular diseases, or associated with systemic diseases.<sup>10</sup> The clinical presentation and complications depends, whether it is a complete or partial dislocation. Anterior lens dislocation into the anterior chamber can increase the risk of acute angle closure glaucoma, while in posterior dislocation, lens is buried in the vitreous cavity, may lead to retinal detachment.<sup>11</sup> In our case series, all patients presented differently. First case was post-traumatic bilateral posterior dislocation of lens with retinal detachment in right eye. This could be explained by a blunt head trauma leads to zonules rupture with a force strong enough to disturb anterior hyaloid phase.<sup>12</sup> In second case, two daughters of women in first case were incidentally diagnosed for Marfan syndrome with ectopia lentis. And third case had came for routine checkup with no history of trauma. Trauma has been reported as the most common cause of lens dislocation in a study of 166 hospitalized cases.<sup>13</sup> A case from Thailand was found to have an anterior dislocation resulted from water splash.<sup>14</sup> Another case of physically abused elderly who suffered a posterior lens dislocation in Japan.<sup>15</sup> A young boy from Serbia suffered from a spontaneous dislocated lens in left eye followed by right eye 2 years later.<sup>16</sup> The management of ectopia lentis is challenging for ophthalmologists. A multidisciplinary team should be involved in managing associated disorders. The goal of treatment is to achieve good vision and to prevent amblyopia and other complications. The primary treatment is to implement a conservative approach by giving glasses



**Figure 2:** Picture showing anteriorly dislocated lens in right eye



**Figure 3:** Picture of left eye showing superonasal subluxation of lens

or contact-lenses. Surgical intervention should not be considered if there is no evidence of complications or failed medical treatment.<sup>17</sup>

### Conclusion

In our study, the first patient had improved with +10 diopter lens and satisfied with the vision but there was presence of retinal detachment in right eye she was referred to vitreo-retina specialist for further management. Second case was kept for observation and 3rd case underwent for lens extraction surgery. Invasive attempts to remove the lenses are associated with potential complications, such as glaucoma and retinal detachment which have been reported in the literature.<sup>18</sup> Special attention should be given to carry out a proper examination and addressing all patient's complains. Therefore, preventing life and vision threatening conditions, providing better visual outcome.

### References

1. Pyeritz RE, Mckusick VA The Marfan Syndrome: Diagnosis & Management New Engl J Med, 300: 772-777,1979.
2. Nelson LB, Maumenee IH: Ectopia Lentis, Surv Ophthalmol 27:143-160,1982.
3. Croxwatto JO, Laobardi, A, Malbream ES: Phacotoxic ' ndophthalmities with Posterior dislocation lens in Marfan's Syndrome Ophthalmologica 193: 23-26, 1986.
4. Obituary. Karl Stellwag Von Carion, M.D. BMJ. 1904;2(2293):1615-6. DOI: 10.1136/bmj.2.2293.1615-c
5. Fuchs J, Rosenberg T. Congenital ectopia lentis. A Danish national survey. Acta Ophthalmol Scand. 1998 Feb;76(1):20-6. DOI: 10.1034/j.1600-0420.1998.760105.x
6. Williams E. Rare Cases, with Practical Remarks. Trans Am Ophthalmol Soc. 1875;2:291-301.
7. Maumenee IH. The eye in the Marfan syndrome. Trans Am Ophthalmol Soc. 1981;79:684-733.
8. Cross HE & Jensen A.D.: Ocular manifestations in Marfan's syndrome and homocystinuria. Am J Ophthalmol. 75:405,1973
9. Schepens CL: Retinal Detachment and Allied Disease. Vol. 2, 1983 W.B Saunders Co. Ch. 28, 653, 1983.
10. Tesser RA, Hess DB, Buckley EG. Pediatric cataracts and lens anomalies. In: Nelson LB, Olitsky SE, editors. Harley's Pediatric Ophthalmology. 5th ed. Philadelphia: Lippincott Williams & Wilkins; 2005. p. 255-84.
11. Nelson LB, Maumenee IH. Ectopia lentis. Surv Ophthalmol. 1982 Nov-Dec;27(3):143-60. DOI: 10.1016/0039-6257(82)90069-8
12. Marcus DM, Topping TM, Frederick AR Jr. Vitreoretinal management of traumatic dislocation of the crystalline lens. Int Ophthalmol Clin. 1995;35(1):139-50. DOI: 10.1097/00004397-199503510-00015
13. Jarrett WH II. Dislocation of the lens. A study of 166 hospitalized cases. Arch Ophthalmol. 1967 Sep;78(3):289-96. DOI: 10.1001/archophth.1967.00980030291006
14. Kunavisarut P, Intarated C, Pathanapitoon K. Bilateral traumatic anterior crystalline lens dislocation by watersplash during Songkran festival: case report. J Med Assoc Thai. 2009 Nov;92(11):1544-7.
15. Mutoh T, Tien T, Horie M, Matsumoto Y, Chikuda M. Case of bilateral complete posterior dislocation of lens caused by elder abuse. Clin Ophthalmol. 2012;6:261-3. DOI: 10.2147/OPHT. S28990
16. Jovanovic M. Bilateral spontaneous crystalline lens dislocation to the anterior chamber: a case report. Srp Arh Celok Lek. 2013 Nov-Dec;141(11-12):800-2. DOI: 10.2298/SARH1312800J
17. Ruellan YM. Traitement chirurgical des déplacements du cristallin [Surgical treatment of dislocation of the crystalline lens]. J Fr Ophtalmol. 1985;8(12):823-31.
18. Huang HM, Kao ML, Kuo HK, Tsai SH, Chen YJ, Liu CC. Visual results and complications after trans pars plana vitrectomy and lensectomy for lens dislocation. Chang Gung Med J. 2004 Jun;27(6):429-35.

**Cite This Article as:** Sagarika Laad, Harpal Singh, Satendra Singh, Parag Ramnani, Ritu Gupta. Case series of Ectopia Lentis associated with Marfan's syndrome. Delhi Journal Of Ophthalmology.2020; Vol 31,No( 3): 87-89

**Acknowledgments:** Nil

**Conflict of interest:** None declared

**Source of Funding:** None

**Date of Submission:** 14 August 2019

**Date of Acceptance:** 04 September 2020

### Address for correspondence

**Sagarika Laad** Senior Resident  
Department Of Ophthalmology  
Peoples College Of Medical Sciences  
And Research Center, Bhanpur,  
Bhopal, India.  
Email: sagarikalaad@gmail.com



Quick Response Code