

Bilateral Endogenous Endophthalmitis In Association with Knee

Rajwinder Kaur,¹ Shallu Samria,¹ Balbir Khan,² Harijot Singh,³ Kulbir kaur⁴

¹Department Of Ophthalmology, Adesh Institute Of Medical Sciences And Research, Bathinda, Punjab, India.

²Department Of Ophthalmology, Adesh Medical College And Hospital, Kurukshetra, Haryana, India.

³Department Of Pediatrics, Adesh Medical College And Hospital, Bathinda, Punjab, India.

⁴ Department Of Clinical Research, Revival Research Institute, Michigan, USA.

Endogenous endophthalmitis is a rare condition caused by the haematogenous spread of microorganisms from a remote infection site to the eye. Common predisposing conditions are intravenous drug use (IVDU), diabetes, malignancy, immunosuppression, chronic renal failure, parenteral nutrition or invasive medical procedures. Endogenous endophthalmitis with staphylococcal bone infection is rare but a serious condition. We describe a case of bilateral endogenous endophthalmitis in a 32 year old intravenous drug abuser who presented with knee osteomyelitis, which further get complicated to septic pulmonary emboli and infective endocarditis. A high index of suspicion is required to diagnose this condition. Early and aggressive management is the key to the favorable visual outcome.

Abstract

bone infection is rare but a serious condition. We describe a case of bilateral endogenous endophthalmitis in a 32 year old intravenous drug abuser who presented with knee osteomyelitis, which further get complicated to septic pulmonary emboli and infective endocarditis. A high index of suspicion is required to diagnose this condition. Early and aggressive management is the key to the favorable visual outcome.

Delhi J Ophthalmol 2021;31; 90-92; Doi <http://dx.doi.org/10.7869/djo.636>

Keywords: Endophthalmitis, Osteomyelitis, Endocarditis

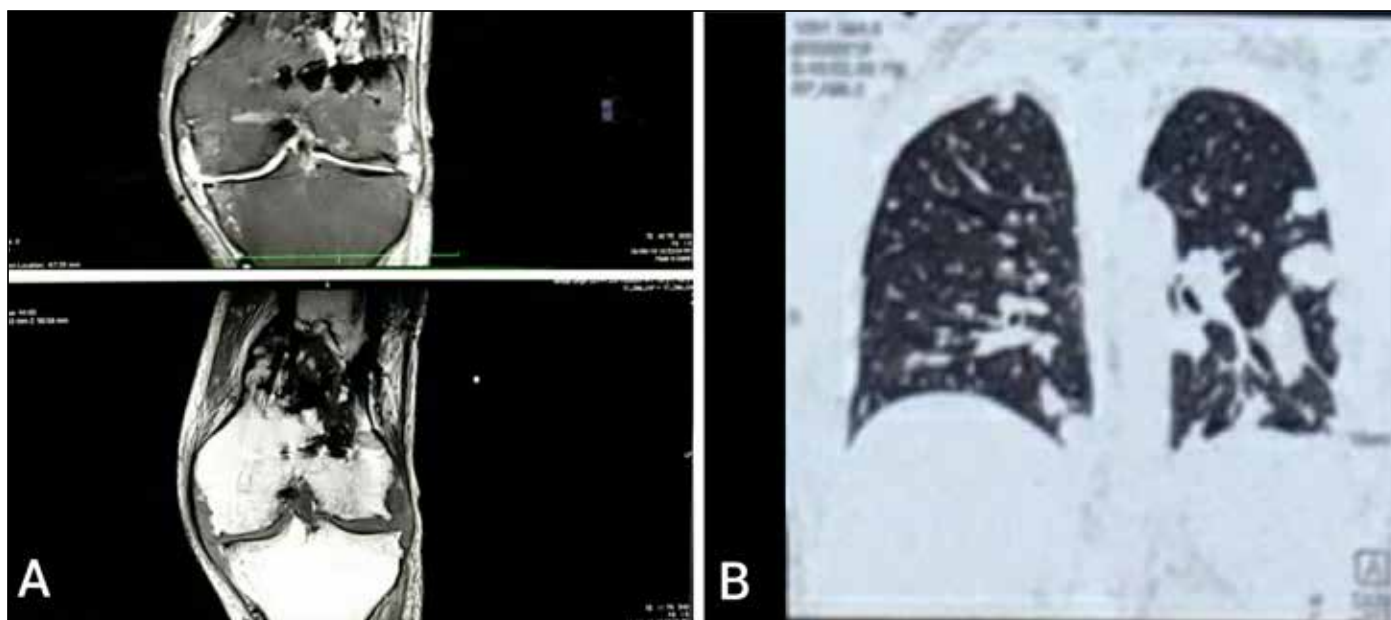
Introduction

Endophthalmitis is classified as either endogenous or exogenous, depending on the route of infection. Exogenous endophthalmitis results from direct inoculation as a complication of neurosurgery, penetrating trauma, foreign bodies or corneal ulceration as well as following a breach of ocular barriers during periocular infections.¹ Endogenous endophthalmitis (EE), which results from bacteremic or fungemic seeding of the eye, is rare.² Endogenous bacterial endophthalmitis (EBE) is most frequently associated with underlying medical condition: compromised host, malignancy or intravenous drug abuse.³

Here, we report a case of intravenous drug user who had vision threatening endogenous endophthalmitis along with life threatening complications.

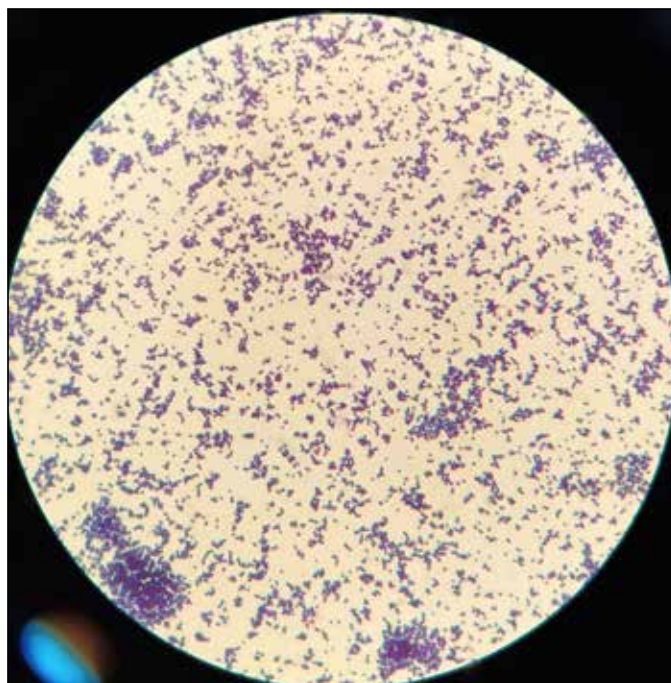
Case report

A 32-year-old male, IV drug user for 2 years presented with high-grade fever, swelling of left knee joint, left wrist accompanied with pain, periarticular redness and decreased range of movements. Routine investigations revealed leukocytosis. Magnetic resonance imaging (MRI) left knee joint was suggestive of heterogeneous collection showing T1/T2 internal heterogeneity involving distal end of femur with underlying bone destruction, i.e. osteomyelitis with septic arthritis (Figure 1A). Subsequently left knee arthrotomy with drainage was done. Pus culture and blood culture showed the growth of *S. aureus*. The patient was managed with IV antibiotics depending on the sensitivity report. The patient went into septic shock and respiratory distress. IV antibiotics were upgraded, inotropes were started. Contrast-enhanced computed tomography chest was done which was



Figures 1: MRI (STIR and T1W) sequences showed a heterogenous destructive lesion involving the distal end of femur alongwith collection in knee joint suggestive of osteomyelitis. Figure 1B is the HRCT chest showed multiple parenchymal subpleural nodules with areas of consolidation and cavitation

suggestive of multiple parenchymal subpleural nodules, areas of consolidation with cavitations with possibility of septic pulmonary emboli (Figure 1B). On day 5 of admission, the patient reported poor vision in both eyes which on further enquiry had been present at the time of his original presentation to the hospital. Best corrected visual acuity (BCVA) was finger counting at 2 meters in both eyes. On diffuse light, there was no visible hypopyon and fundus examination showed a subretinal abscess at the macula in both eyes. Fundus photographs were taken with MIIRetcam in intensive care unit which demonstrated yellowish subretinal lesion of 2 disc diameter in right eye and 4-5 disc diameter in size in left eye with fuzzy margins suggestive of subretinal abscess (Figure 2B and 2A). Diagnosis of bilateral endogenous endophthalmitis was made and vitreous tap was taken under all sterile conditions and sent for gram stain, KOH stain and culture sensitivity. Vitreous tap also showed gram positive cocci in gram stain (Figure 3). KOH stain was negative for any fungal element. Intravitreal vancomycin (1mg / 0.1 ml) and ceftazidime (2.25 mg / 0.1 ml) and dexamethasone (0.1mg/ml) were given. Fortified vancomycin, ceftazidime and prednisolone eye drops each one hourly and atropine 1% eye drops twice a day were given. BCVA improved to <6/60 in left eye and 6/60 in right eye. Subretinal abscess at macula decreased in size after 48 hours but there was presence of vitreous balls in left eye (Figure 2C and 2D). Intravitreal antibiotics were repeated in left eye. Optical coherence tomography (OCT) demonstrated disintegration and necrosis of the retinal layers with sparing of the internal limiting membrane in the macular region in both eyes (Figure 4). In view of persistent fever, two-dimensional echo was done which showed large vegetation at the posterior leaflet of tricuspid valve with moderate



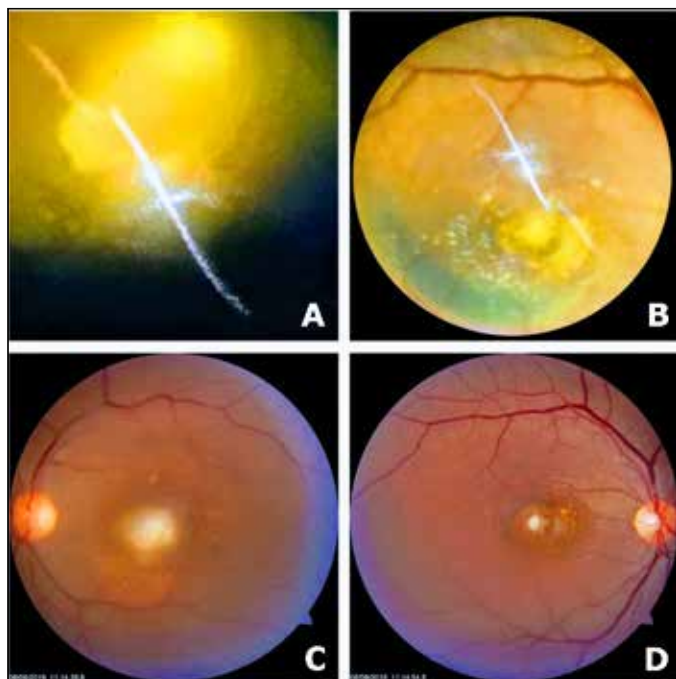
Figures 3: Gram stain showing gram positive cocci.

tricuspid regurgitation suggestive of infective endocarditis. IV antibiotics were upgraded. The patient was managed with the same treatment for the next 6 weeks. Subsequent echo showed marked decrease in the size of vegetation. The patient is currently stable, afebrile and off antibiotics. On the final visit, patient was maintaining the BCVA of 6/60 in left eye and 6/60 in right eye.

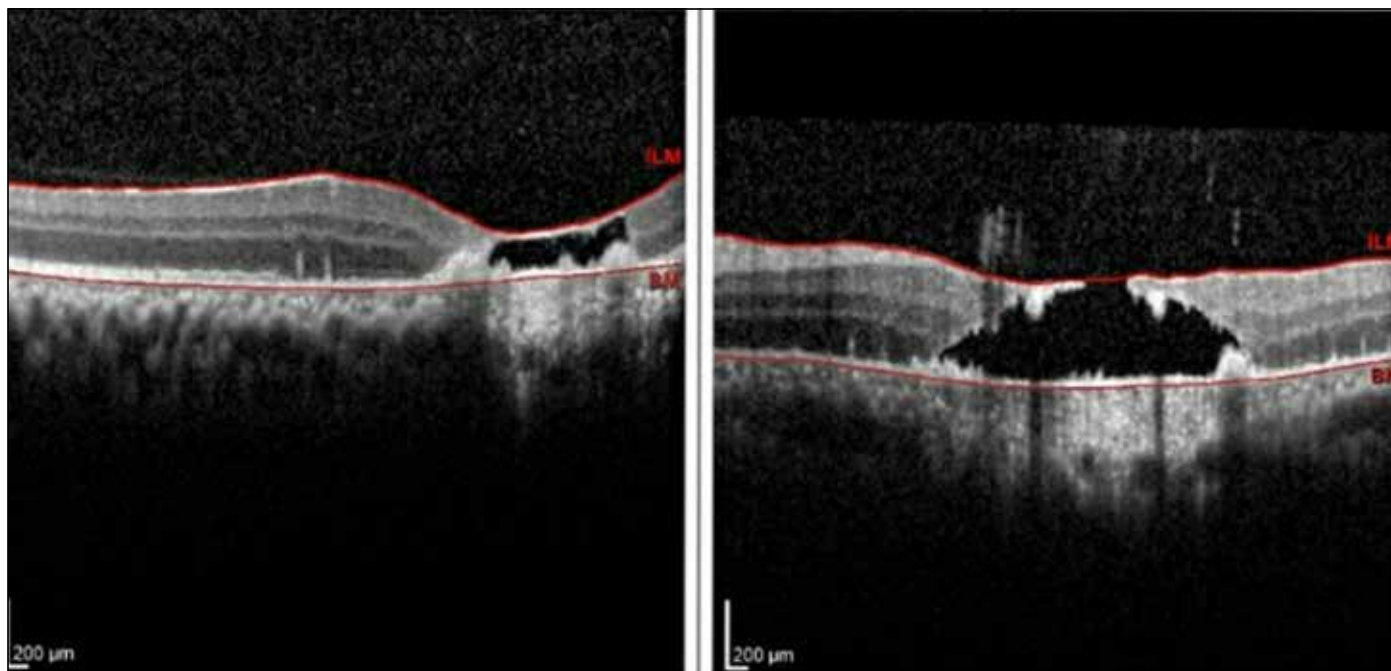
Discussion

Intravenous drug use (IVDU) is a known risk factor for EE and is emerging as a common problem in the community. This is the first reported case showing an IV drug abuser developing serious complications like septic arthritis with vision threatening bilateral endogenous endophthalmitis and life threatening complications like septic pulmonary emboli and infective endocarditis. Identification of the causative organism in EBE can be achieved through a combination of blood cultures and intravitreal sampling with respective sensitivities of these methods being 56% and 58%.⁴ Vitreous tap, pus culture and blood culture also showed the growth of *S. aureus* in our case.

Unilateral endogenous endophthalmitis in a patient of diabetes mellitus with foot osteomyelitis which was due to streptococci was described in 2015. The case ended in corneal melting and formation of vitreous abscess necessitating evisceration.⁴ There was another case report of 3 patients of staphylococcal endogenous endophthalmitis associated with vertebral osteomyelitis reported by Steeples LR et al in 2016.⁵ Another case of unilateral staphylococcal endogenous endophthalmitis was reported in 2017 by Martinez EC et al. It was associated with type 2 diabetes mellitus and plaque psoriasis taking interleukin 17inhibitor.⁶



Figures 2: (A) and (B) demonstrated yellowish subretinal lesion of 4-5 disc diameter in size in left eye and 2 disc diameter in right eye with fuzzy margins on first visit (C) and (D) demonstrated the decrease in size of subretinal lesion at the macula after the treatment.



Figures 4: OCT picture of macula of right eye and left eye demonstrated significant necrosis of retinal layers with sparing of internal limiting membrane at the final visit.

Despite the severity of the condition, the diagnosis is often delayed as in this patient, and this delay is one of the poor prognostic factors. Other poor prognostic indicators include poor initial visual acuity, bilateral involvement, and central lesion involving macula as in our case. Treatment of EBE involves a combination of intravitreal and intravenous antibiotics as well as intravitreal dexamethasone with a consideration of early vitrectomy. OCT is a useful tool in assessing the visual prognosis, as the macula showed necrotic changes in both eyes, so the patient was not treated with vitrectomy.

Conclusion

Assessment of vision in all systemically unwell patients is important for early diagnosis of endogenous bacterial endophthalmitis. Late diagnosis and management significantly reduces the prognosis of the disease.

References

1. Okada AA, Johnson RP, Liles WC, D'Amico DJ, Baker AS. Endogenous bacterial endophthalmitis. Report of a ten-year retrospective study. *Ophthalmology* 1994;101(5):832-8.
2. Durand ML. Bacterial and Fungal Endophthalmitis. *Clin Microbiol Rev* 2017;30(3):597-613.
3. Jackson TL, Paraskevopoulos T, Georgalas I. Systematic review of 342 cases of endogenous bacterial endophthalmitis. *Surv Ophthalmol* 2014;59(6):627-35.
4. Mavrakanas TA, de Haller R, Philippe J. Endogenous endophthalmitis in a patient with diabetes and foot osteomyelitis. *Can J Diabetes* 2015;39(1):18-20.
5. Steeples LR, Jones NP. Staphylococcal endogenous endophthalmitis in association with pyogenic vertebral osteomyelitis. *Eye* 2016;30:152-5.
6. Martinez CE, Allen JB, Davidorf FH, Cebulla CM. Endogenous endophthalmitis and osteomyelitis associated with interleukin 17 inhibitor treatment for psoriasis in a patient with diabetes. *Case Reports* 2017;2017:bcr-2017-219296.

Cite This Article as: Rajwinder Kaur, Shallu Samria, Balbir Khan, Harijot Singh, Kulbir kaur. Bilateral Endogenous Endophthalmitis In Association with Knee. *Delhi Journal Of Ophthalmology*. 2021 ; Vol 31,No (3): 90-92.

Acknowledgments: Nil

Conflict of interest: None declared

Source of Funding: None

Date of Submission: 22 December 2019

Date of Acceptance: 23 November 2020

Address for correspondence

Rajwinder kaur MS

Department Of Ophthalmology

Adesh Institute Of Medical Sciences

and Research, Bathinda Punjab, India.

Email: rajujerry26@gmail.com



Quick Response Code