

Photo essay

IOL Opacification Simulating White Cataract

Ankit Ahir, Isha Agarwalla, Mohit Garg, Ganesh Kuri, Bhavya Gokani

Department of Ophthalmology, Sri Sankaradeva Netralaya, Beltola, Guwahati. India.

Abstract

A 79-year-old male patient presented complaining of decreased visual performance in his right eye(OD) over a 2 month period. On examination, visual acuity was CFCF with a white reflex in pupillary area. On diffuse biomicroscopic examination thin layer of whitish opacification was seen on anterior surface of lens, simulating the presence of total cataract.

Delhi J Ophthalmol 2021;31; 110-111; Doi <http://dx.doi.org/10.7869/djo.645>

Keywords : Iol Opai Fixation White Cataract, Calcium Deposit, Iol Extraction

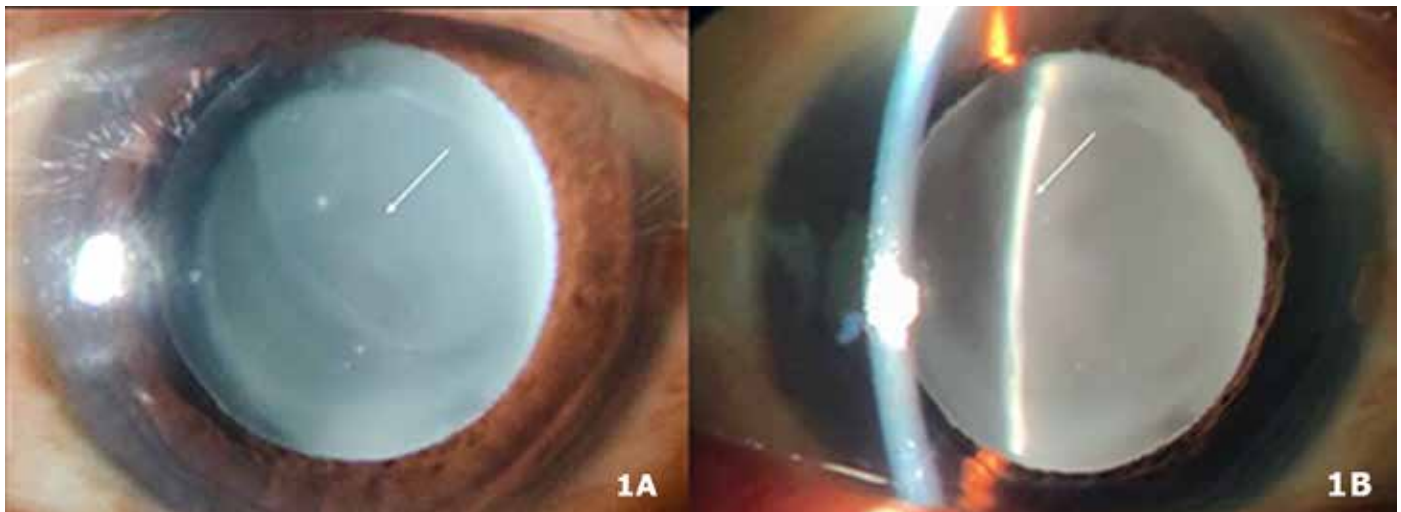


Figure 1: (A) On diffuse biomicroscopic examination thin layer of whitish opacification was seen on anterior surface of lens, simulating the presence of total cataract.

Figure 1: (B) Slit beam revealed presence of IOL beneath and a uniform thickness of opacification on the surface.

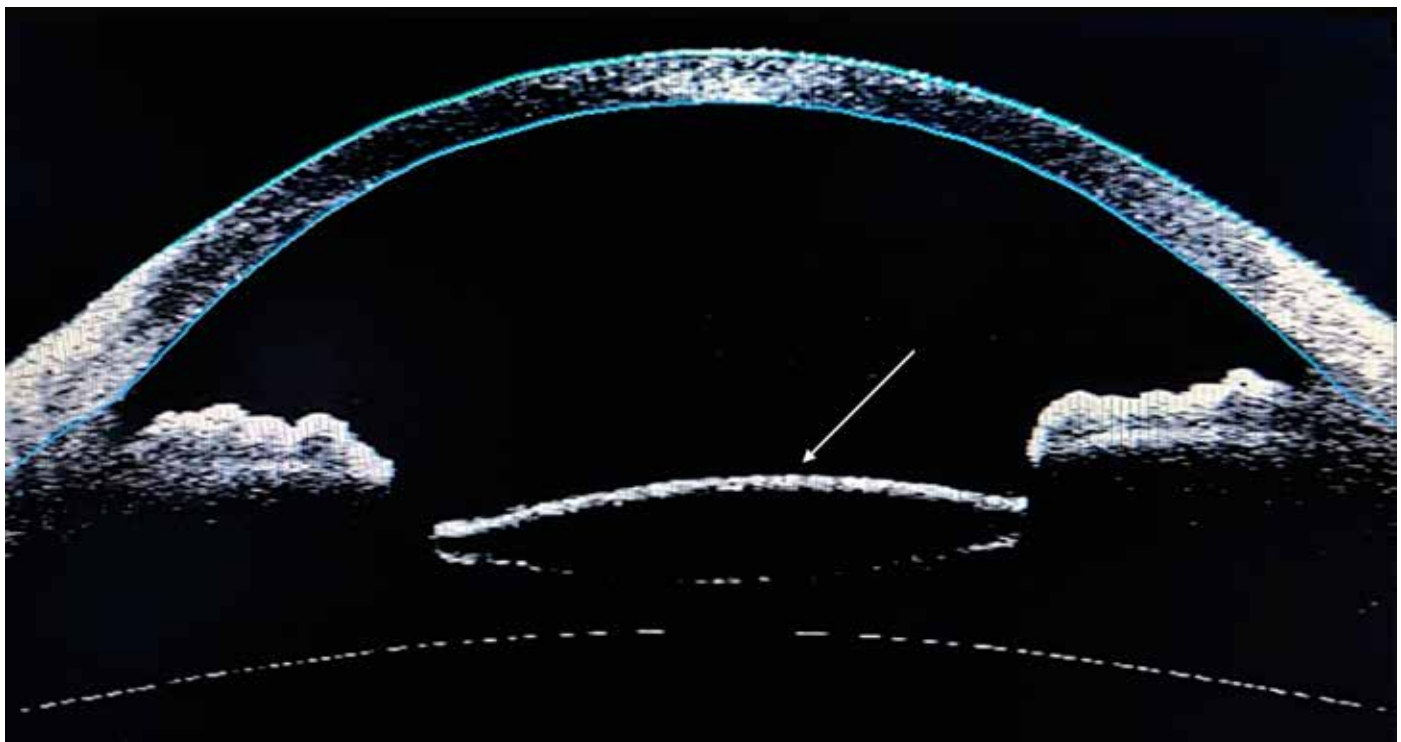


Figure 2: AS-OCT revealed a uniformly thickened opacification over the IOL surface that did not extend beyond the equator.

Case Details

A 79-year-old male patient presented complaining of decreased visual performance in his right eye(OD) over a 2 month period. On examination, visual acuity was CF/CF with a white reflex in pupillary area. On diffuse biomicroscopic examination thin layer of whitish opacification was seen on anterior surface of lens, simulating the presence of total cataract (Figure 1A). Slit beam revealed presence of IOL beneath and a uniform thickness of opacification on the surface (Figure 1B).

AS-OCT revealed a uniformly thickened opacification over the IOL surface that did not extend beyond the equator (Figure 2). Posterior segment was unremarkable.

Diagnosis of opacified IOL was confirmed and IOL explant and replacement was done for the patient with a silicon IOL.

Comments

IOL opacification, although a very rare complication, occurrence depends upon the IOL material, underlying eye conditions such as uveitis, diabetic retinopathy or trauma.^{1,2} Exact etiopathogenesis is unknown, however conditions that lead to breakdown of blood-aqueous barrier leads to opacification and calcium deposits have been found most commonly.³ IOL opacification has been found following procedures of endothelium, where there is contact of air bubble with IOL surface.⁴ These cases lead to a surprise in diagnosis, thus a correct sequelae of proper history and examination is to be followed. In most cases, explant of IOL is required.

References

1. Izak AM, Werner L, Pandey SK, Apple DJ. Calcification of modern foldable hydrogel intraocular lens designs. *Eye (Lond)* 2003;17:393-406.
2. Tandogan T, Khoramnia R, Choi CY, Scheuerle A, Wenzel M, Hugger P, et al. Optical and material analysis of opacified hydrophilic intraocular lenses after explantation: A laboratory study. *BMC Ophthalmol* 2015;15:170.
3. Morgan-Warren PJ, Andreatta W, Patel AK. Opacification of hydrophilic intraocular lenses after Descemet stripping automated endothelial keratoplasty. *Clin Ophthalmol* 2015;9:277-83.
4. Fellman MA, Werner L, Liu ET, Stallings S, Floyd AM, van der Meulen IJ, et al. Calcification of a hydrophilic acrylic intraocular lens after Descemet-stripping endothelial keratoplasty: Case report and laboratory analyses. *J Cataract Refract Surg.* 2013;39:799-803.

Cite This Article as: Ankit Ahir, Isha Agarwalla, Mohit Garg, Ganesh Kuri, Bhavya Gokani. IOL opacification simulating White Cataract *Delhi Journal Of Ophthalmology.* 2020; Vol 31,No(3): 110-111.

Acknowledgments: Nil

Conflict of interest: None declared

Source of Funding: None

Date of Submission: 20 August 2020

Date of Acceptance: 11 September 2020

Address for correspondence

Isha Agarwalla

Sri Sankaradeva Netralaya,

Beltola, Guwahati.

Email: ishaagarwalla@gmail.com



Quick Response Code