

Viral Retinitis: Review

Anamika Patel,¹ Mudit Tyagi²

¹LV Prasad Eye Institute GMRV Campus, Department of Vitreo Retina and Uveitis Services Vizag, Andhra Pradesh, India.

²Uveitis and Ocular Immunology Services, Smt.Kanuri Santhamma Center for Vitreoretinal Diseases L.V.Prasad Eye Institute, Hyderabad, Telangana, INDIA

Abstract

Retinitis is one of the common presentation of posterior uveitis. The cause could be either an infection or inflammation but until proven otherwise, retinitis is infectious. It could present either as unifocal or multifocal presentation and may manifest either as full thickness retinitis, chorioretinitis or retinochoroiditis.

Delhi J Ophthalmol 2021; 31; 19- 25; Doi <http://dx.doi.org/10.7869/djo.651>

Keywords: Retinitis, Infectious Posterior Uveitis, Viral Retinitis, CMV, ARN, PORN

Introduction

Retinitis is an inflammation of retina that may or may not involve subjacent structures. It could be either retinitis or retinochoroiditis or chorioretinitis. Retinitis can present as either a focal retinal infiltrate like retinitis or may have a full thickness retinal involvement. Retinitis can be having both infectious and non infectious etiologies. Table 1 and 2 list the common causes of both infective and non infective retinitis. The aim of this review is to dwell upon the main types of viral retinitis.

Table 1: Etiological diagnosis of retinitis

Infectious	Noninfectious
Viral	Sarcoidosis
Bacterial	Behcets
Fungal	Post fever Retinitis
Protozoal	
Nematode	

Table 2 : Microorganisms causing retinitis

Viral	Cytomegalovirus Herpes simplex virus Ebstein barr virus Varicella zoster virus West Nile virus Chikungunya Subacute Sclerosing Panencephalitis (Measles) Zika Virus Ebola Virus
Bacteria	M tuberculosis Rickettsiosis (Epidemic Retinitis) Typhoid Bartonellosis Brucellosis Borreliosis Bacteria causing endogenous endophthalmitis
Spirochetal	Treponema pallidum
Protozoal	Toxoplasma gondii
Fungal	Aspergillus, candida
Nematode	Diffuse unilateral Subacute Necrotizing Neuroretinitis (Toxocara canis, Baylisascaris procyonis and Ancylostoma caninum, Strongyloides sp, Alaria mesocercaria and filarial worms)

CMV (Cytomegalovirus virus) Retinitis

Cytomegalovirus virus is a double stranded virus which belongs to the herpesviridae family. The various mode of transmission are congenital, breast milk, saliva, sexually transmitted fluids, organ transplantation and blood transfusion. Males and females are both affected.¹ It predominantly affects the immunocompromised patients with CD4 counts below 50 cells / mm.² The virus remains latent in immunocompetent individuals and gets reactivated when the immunity is compromised.^{3,4} It causes full thickness necrotizing retinitis. Anterior segment inflammation is generally mild to none and patients become symptomatic only when they experience a decrease in vision. Photophobia, watering and pain are generally not experienced by the patients.⁵

CMV Retinitis is known to present clinically in 3 different forms:-

- a) Fulminant form
- b) Indolent granular form
- c) Frosted branch angitis like clinical picture

CMV retinitis is predominantly a clinical diagnosis which may either first present at the periphery of retina and later can spread in contiguous manner or may primarily present as a posterior pole affliction. One can recognize this retinitis for its white border and retinal atrophy in the center of retinitis or what is known as central clearing (Figure 1).

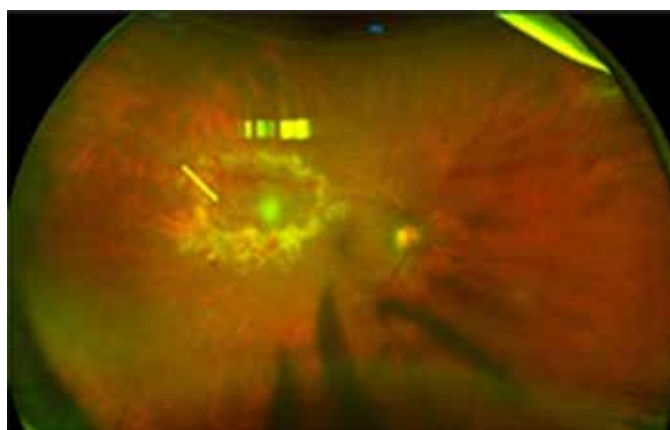


Figure 1: Right eye colour fundus photograph showing CMV retinitis at superotemporal aspect -Note the central clearing denoted by yellow arrowhead.

It is one of the slowly replicating virus which aids one to differentiate it from other necrotizing retinitis.⁶ Fulminant form: The common brushfire like description is for the fulminant form which presents along with the multiple retinal hemorrhages. The virus is known to resides at the edge of the retinitis lesion⁷ (Figure 2). Indolent or granular variant of CMV retinitis: It is the initial presentation when the vascular endothelium is affected. When small vessels are involved it leads to multiple small retinal lesions (Figure 3). Frosted branch angitis: Third rare atypical variant is frosted branch angitis like presentation where there occurs perivascular sheathing (Figure 4).

Once healed these lesions leave atrophic and necrotic retina. Ocular complications occur when the treatment is not initiated or is inadequate or when the infection is exuberant. The most common complication is the development of the retinal detachment which occur due to necrotic retina. One may come across optic nerve head involvement also (Figure 5) and exudative retinal detachment as well in few cases.

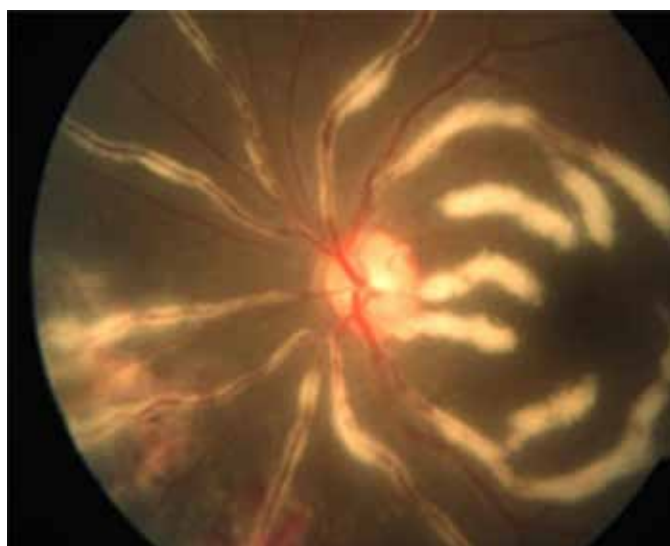


Figure 4: Left eye colour fundus photograph showing the Frosted branch angitis variant of CMV retinitis showing retinal vasculitis characterized by prominent retinal vessel sheathing. It has an appearance like of frozen branch of a tree. Also note the presence of necrotizing retinitis at the inferonasal aspect along with the presence of hemorrhages.

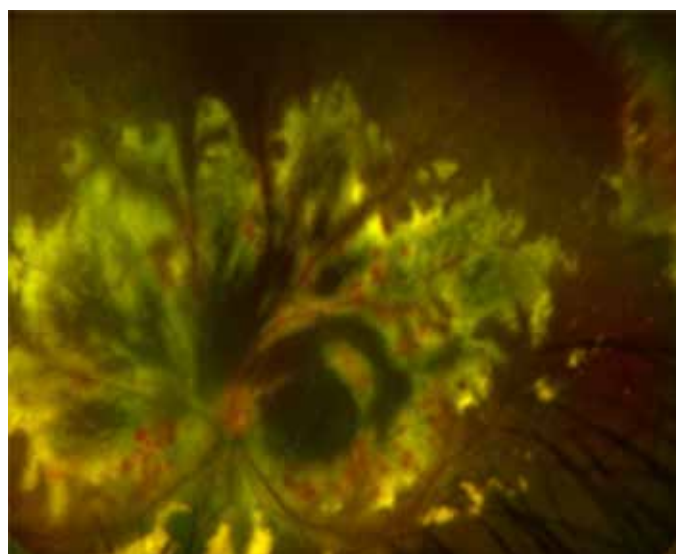


Figure 2: Left eye colour fundus photograph showing fulminant variant of CMV retinitis showing necrotizing retinitis at the posterior pole and presence of hemorrhages along the retinitis.

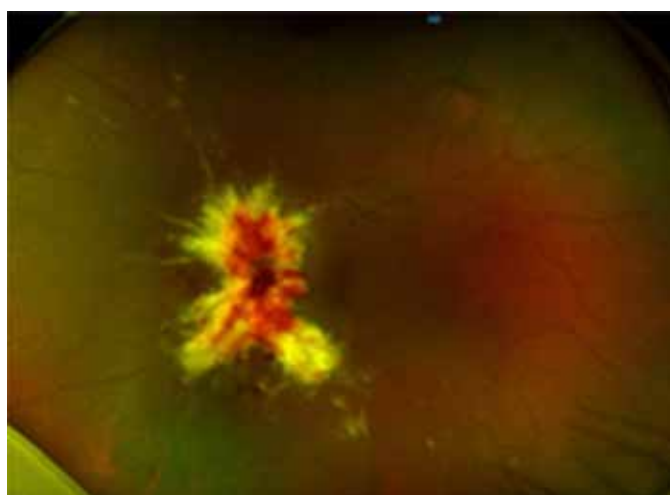


Figure 5: Left eye colour fundus photograph showing CMV retinitis with optic disc infiltration. Appreciate the optic disc is not very distinct and presence of necrotizing retinitis admixed with hemorrhages.

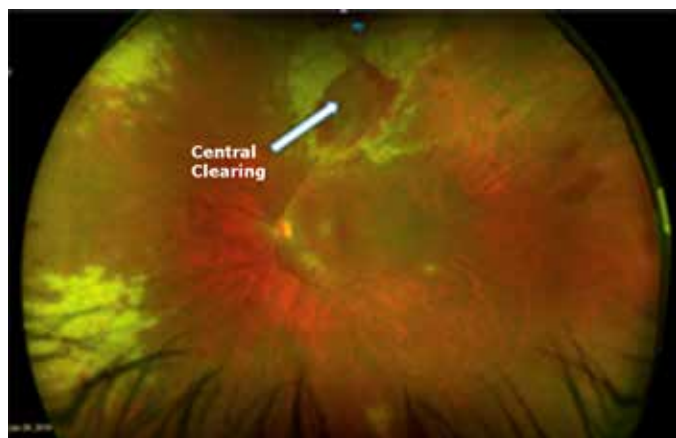


Figure 3: Right eye colour fundus photograph showing Indolent variant of CMV retinitis at superotemporal aspect -Note the central clearing denoted by yellow arrowhead. Note the

Vision loss: the common causes of vision loss are necrotic damage to fovea, retinal detachment and optic nerve involvement.

Pathology

Histologically it is characterized by presence of coagulative necrosis and presence of cytomegalic cells in RPE and retina.⁸ OCT Features: Invernizzi et al. have described the Spectral domain OCT features of CMV retinitis in both active and healed phases. They have described the nebulous vitritis, posterior hyaloid thickening, epiretinal membrane and retinal swelling as features of active CMV retinitis. Amongst the chorioretinal involvement their study has described two kinds of chorioretinal involvement in active retinitis, one is characterized by inner retinal hyperreflectivity, outer nuclear layer empty spaces and bridges of retinal tissue sparing the choriocapillaris and another one is cavernous retinitis.⁹

Treatment

It is extremely important to start the anti-retroviral treatment (HAART) to not only stop the progression of the retinitis but to avoid the other eye involvement and to prevent the systemic complications associated like pneumocystis and other comorbidities of HIV infection. Since the antivirals used in treatment of CMV Retinitis are virustatic and not viricidal, the treatment is indefinite in immunocompromised individuals.

Ganciclovir: It is an acyclic purine nucleoside which is effective against herpesviruses, like herpes simplex virus, varicella-zoster virus, Epstein-Barr virus, and CMV. It is phosphorylated to its active form ganciclovir triphosphate via the viral protein called viral kinase so that it can bind to CMV DNA polymerase to inhibit CMV DNA replication. It has an intravenous dose of 5 mg / kg 12-hours for 2 weeks followed by maintenance dose of 5 mg/kg/day till the resolution of retinitis occurs. One of the major side effects associated with the usage of Intravenous ganciclovir is myelosuppression, hence the patients need constant monitoring.

Valganciclovir: It is a prodrug of ganciclovir. It gets hydrolysed to its ganciclovir form by the intracellular esterase of gut which is then phosphorylated by viral and cellular kinase to ganciclovir triphosphate. Valganciclovir inhibits the viral synthesis by replacing the dGTP in growing chain of virus. Valganciclovir has a better bioavailability than Ganciclovir and is therefore the preferred drug and is given in the 900 mg dose of two times per day for first 3 weeks as an induction dose followed by the maintenance dose of 450 mg two times till the CD4 counts rises to more than 200 for minimum three consecutive months and upon resolution of retinitis. Systemic complications of oral antivirals are neutropenia and bone marrow suppression.^{10,11} For the patients in whom the oral treatment is not feasible intravitreal ganciclovir in a dose of 2-4 mg/0.05-0.1 mL is opted for as biweekly injections for first three weeks followed by once every week till the CD4 count rises again and the retinitis resolution is noted.^{12,13} For patients who do not show improvement to the ganciclovir or are resistant to ganciclovir, various alternative treatment options are Intravenous foscarnet before opting for cidofovir. Intravenous foscarnet is given in a dose of 60 mg/kg 8-hour for 2-3 per week or 90 mg / kg 12-hour for 2-3 week as induction dose and 90-120 mg / kg /day as maintenance dose Intravitreal dose is 2.4 mg / 0.1 mL is twice weekly for three weeks and once weekly till the resolution of retinitis is noted.

Foscarnet is a pyrophosphate analogue which binds to CMV DNA polymerase and hence inhibits DNA replication.¹⁴ It has lower plasma solubility and higher ionization and that's the reason higher intravenous dose is required in compare to ganciclovir. Another important factor which one must remember is the nephrotoxicity associated with the foscarnet, hence before the treatment is begun and during the treatment, Renal Function Test is advised. Other side effects associated with Foscarnet are hypocalcaemia, hypomagnesaemia, anemia and genital ulceration.

Physicians must ask for periodic Complete blood counts, Serum electrolytes and Urea creatinine.¹⁵ Cidofovir is a nucleoside analog which is considered when the patient of CMV retinitis develops resistance to ganciclovir or is intolerant to other treatment options for CMV retinitis. Cellular enzymes diphosphorylates cidofovir to its active form which acts as competitive inhibitor of viral DNA. It has a long intracellular half-life which makes twice weekly dosing possible in compare to all other available antivirals like ganciclovir or foscarnet or valganciclovir. It is given in dose of 5 mg / kg once weekly for 2 week as induction dose. Probenecid pre- and post-infusion are given along with the intravenous probenecid in order to prevent nephrotoxicity. Side effects associated with cidofovir are anterior uveitis, renal impairment and ocular hypotony.¹⁶

Acute Retinal Necrosis (ARN)

It is a necrotizing retinitis which is caused by Varicella Zoster Virus, Herpes Simplex Virus – 1 and 2, Cytomegalovirus and Epstein Barr Virus. In contrast to the CMV retinitis which commonly occurs in immunocompromised patients, ARN manifests in immunocompetent individuals. However in certain immunocompromised individuals subclinical impaired cellular immunity has also been proposed by few groups.

One must elicit the history of past history of fever, chicken pox, herpes zoster ophthalmicus and viral encephalitis. These patients have both anterior and posterior segment inflammation and ARN is known to cause panuveitis.

ARN is also known present with pigmented Keratic precipitates which may be either granulomatous or non-granulomatous, raised intraocular pressure and occasionally even an anterior scleritis.¹⁷ Posterior segment manifestations include severe and extensive vitritis and necrotizing yellowish cream-colored retinitis which when exuberant could give a headlight in the fog appearance albeit in periphery unlike toxoplasma which presents usually as a solitary unifocal lesion (Figure 6). Areas of retinal necrosis are seen in far to midperipheral part of retina. When untreated these retinitis lesions progress in circumferential pattern. Severity of the disease is classified as mild (less than 25%), moderate (between 25-50 %) and severe (>50%), based on the percentage of the retina involvement.¹⁸⁻¹⁹ Retinal arteries are commonly affected, and it causes occlusive retinal vasculitis leading to localized retinal ischemia and non-perfusion. Occlusive vasculitis progresses beyond the area of retinitis. It is a unilateral condition however bilateral retinal necrosis occurs as well.²⁰ Another associated feature that one may come across is presence of Kyrieleis arteriolitis.²¹ The risk of other eye involvement is high in first three months.²²

Association of Age with ARN: It has a bimodal age distribution with peaks in fourth and sixth decade. In younger individuals it is caused by HSV-2 and older individuals it is caused by VZV and HSV-1.^{23,24}

Invernizzi et al. had described ocular coherence tomography features of the necrotizing retinitis of viral etiology mainly the CMV and HSV. They reported the presence of intraretinal edema characterized by cystic spaces or lacunae in the outer nuclear layer and presence of vertical strips within the outer nuclear layer as a feature suggestive of viral necrotizing retinitis. They have conjectured the hyper reflectivity of vertical strips as a result of swelling of retinal muller cells which extends from RPE to inner retinal layers.²⁵

Complications

The two most common complications of ARN are associated optic neuropathy and rhegmatogenous retinal detachment which are seen in about 75% of cases.²⁶

One should suspect optic neuropathy when patient has sudden diminution of vision within 24-36-hour interval.²⁷

Table 3:

Diagnostic criteria	Supportive features
Multifocal, deep retinal opacification without granular borders Lesions may be confluent Peripheral lesions with or without macular lesions Very rapid progression Inconsistent direction of disease spread No vascular inflammation None or minimal intraocular inflammation	Perivenular lucency

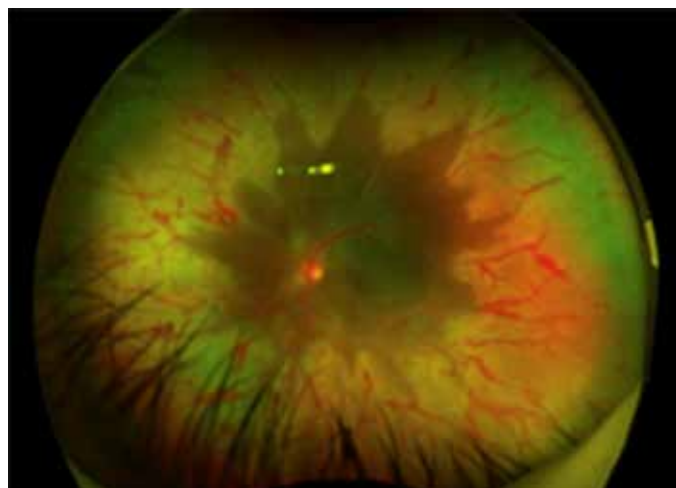


Figure 6 : Right eye colour fundus photograph of Acute Retinal Necrosis showing peripheral retinitis. Note the absence of hemorrhages..

Diagnostic criteria for the ARN

It is based on the criteria laid down by American Uveitis Society in 1994

Diagnostic criteria:

1. One or more foci of retinal necrosis in peripheral retina
2. Rapid progression in absence of treatment
3. Circumferential spread
4. Occlusive vasculopathy
5. Inflammatory reaction in vitreous and anterior chamber

Supportive features are: Optic neuropathy, scleritis and pain.

Pathology

Histopathologically multiple inflammatory infiltrates are seen in the ocular coats of eye with presence of intranuclear inclusion bodies in the retina and retinal pigment epithelium.²⁸

Treatment

Systemic treatment is advocated to prevent viral replication and stop the disease progression in the affected eye and to prevent the involvement of the fellow eye . Systemic therapy for ARN includes intravenous and oral acyclovir, oral valacyclovir, famciclovir, and valganciclovir, and intravenous foscarnet and ganciclovir. ARN was initially treated with intravenous acyclovir (1500 mg/m²/day) for 5–10 days and transitioned to oral acyclovir (800 mg 5 times/day) for 4–6 weeks

Valacyclovir is a nucleoside analogue antiviral agent and prodrug of acyclovir which inhibits viral DNA replication after getting converted to nucleotide analog namely acyclovir triphosphate with the aid of enzyme thymidine kinase. Acyclovir breaks the growing DNA chain and inactivates DNA polymerase²⁹

Oral Valaciclovir 2g TID is started and continued for minimum 2 months following resolution of retinitis. In immunocompromised patients its continued till CD4 counts becomes more 200 for consecutive three months.

Other antiviral agents are famciclovir which could be used for the treatment of ARN. There is supporting evidence in literature which mentions the usage of 500 mg TID of oral famciclovir.

Intravitreal Therapy

Multiple case reports in literature supports the adjunctive usage of foscarnet (2.4 mg/0.1 mL) and ganciclovir (2 mg/0.1 mL) in the treatment of ARN. Intravitreal ganciclovir 2 times weekly is opted as an adjuvant treatment when retinitis is more than 25% with associated vitritis, posterior pole involvement and serous detachment.³⁰

Oral steroids are contraindicated in immunocompromised patients but are used in exuberant inflammation in immunocompetent patients along with concurrent antiviral agents.³¹

Retinal detachment: Break generally occurs between the necrotic and non-necrotic retina. Proliferative vitreoretinopathy occurs in persistent vitritis and adds to the traction in retinal detachment of acute retinal necrosis.

Prophylactic Laser : The role of prophylactic barrage laser is debatable. Many case reports are available in literature wherein prophylactic barrage laser has been administered in patients of acute retinal necrosis but the conclusive role is conflicting. It is suggested to apply the barrage laser within six weeks of diagnosis to achieve chorioretinal adhesion prior to posterior vitreous detachment.³²

However the authors do not support the use of prophylactic barrage laser in prevention of retinal detachments in ARN

Progressive Outer Retinal Necrosis (PORN)

This retinitis belongs to the same herpetic family and is known to have a vehement course. It is a progressive necrotizing retinitis seen in immunocompromised patients initially affecting the outer retina which later coalesce³³

It is classically described as having a cracked mud like appearance because the retina adjacent to vessels appears retinitis free (Figure 7). One needs to be extremely vigilant in suspecting the PORN because failure to recognize leads to rapid progression and involvement of another eye. Visual prognosis is generally poor in PORN. Proposed clinical criteria for PORN³⁴ is enlisted in (Table 3).

OCT features: The earliest change in OCT in case of PORN is seen in Inner plexiform layer in form of hyperreflectivity and inner retinal thickening. Later as the retinitis progresses and involves all the layers of retina it is appreciated in OCT in form of hyperreflectivity involving entire retina and hyporeflexive spaces in inner retinal layers suggestive of retinal tissue loss secondary to necrosis.³⁵ In cases of healed PORN, thinning of retina is noted on OCT.³⁶

As the name suggest, outer retinal necrosis appears as outer retinal layer thickening on OCT.^{37,38}

Treatment

PORN is extremely difficult to manage with single antiviral agent. Initiation of anti viral along with treatment of immunodeficiency should be done promptly. Combination of systemic and intravitreal antivirals are more effective in compare to systemic or intravitreal treatment alone.³⁹ Also, in addition to HIV patients, PORN has been reported in patients receiving Rituximab as well which were treated with combination treatment.⁴⁰

Apart from the commonly reported and encountered viral retinitis like CMV, ARN and PORN, there are a few other viral retinitis entities

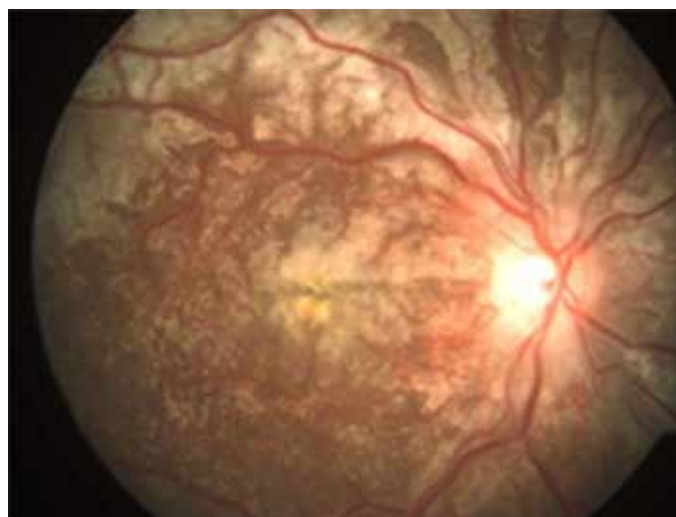


Figure 7 : Right eye colour fundus photograph of Progressive Outer Retinal Necrosis showing classical mud crack like appearance. Note that the retina adjacent to vessels appears retinitis free.

West Nile Virus retinitis

It is caused by West Nile virus and is transmitted to humans through infected mosquito bite. It manifests as multifocal chorioretinitis with or without changes in vitreous. Linear clusters of chorioretinal scars are characteristic of West Nile Virus retinitis. They are seen in patients with West Nile Virus encephalitis who exhibit neurological abnormalities and memory impairment.⁴¹

Dengue: It is a common vector borne disease and is known to have 4 serotypes. It is a member of the Flaviridae family and spreads through Flavivirus genus. Posterior uveitis manifests within first few weeks of systemic symptoms. Serous retinal detachments with panuveitis, macular hemorrhage, macular edema, vasculitis, arterial sheathing and venous occlusion and foveolitis have been described. Involvement of outer retina has been described with associations like acute posterior multifocal placoid pigment epitheliopathy, acute zonal occult outer retinopathy and retinochoroiditis. RT-PCR helps in the identification in cases of clinical suspicion. For anterior uveitis presentations, topical steroids are advocated, and oral steroids have been reported to be used in cases with retinal vasculitis.⁴²

Chikungunya

It is one of the commonest virus CHIKV which belongs to the family Togaviridae family and spreads through Alphavirus genus. Anterior, intermediate, posterior and panuveitis are all sorts of ocular manifestation which are associated with Chikungunya virus. Amongst the posterior segment manifestation, Focal and multifocal retinitis, choroiditis, retinal vasculitis which could either be hemorrhagic or obstructive, neuroretinitis are reported. Also, Acute macular Neuroretinopathy with wedge-shaped and paracentral macular lesions are reported. In order to suspect a Chikungunya virus one needs to look at the history of febrile illness and classical musculoskeletal symptoms which generally gives away the diagnosis. For treatment, topical steroids are advocated for anterior uveitis and oral steroids are used in cases of optic disc involvement.

Zikavirus

It's an emerging virus which has gathered a name for it being an international concern. It was first isolated from Uganda in 1940 and now its prevalent in western hemisphere. It's a member of family Flaviviridae which spreads through aedes genus. It has incubation period of upto 2 weeks and 80% are individuals have subclinical infection.⁴³

In infants with congenital Zika infection two specific forms is seen in retina: a) well circumscribed atrophy and b) pigment mottling at macula.⁴⁴

In adults, retro orbital pain and conjunctivitis occurs. In posterior segment bilateral optic disc edema, peripheral chorioretinal lesions. Unilateral acute idiopathic maculopathy has also been reported where disruption of outer retina was noted on OCT. There is no treatment for Zika currently and is treated for the symptomatic relief.

References

1. Badami K. CMV and transfusions, an old story that's not quite over yet. *International Journal of Clinical Transfusion Medicine*. 2014;2:7-19
2. Munro M, Yadavalli T, Fonteh C, Arfeen S, Lobo-Chan AM. Cytomegalovirus Retinitis in HIV and Non-HIV Individuals. *Microorganisms*. 2019;8(1):55.
3. Yoser SL, Forster DJ, Rao NA. Systemic viral infections and their retinal and choroidal manifestations. *Surv Ophthalmol*. 1993;37(5):313-52
4. Rafailidis PI, Mourtzoukou EG, Varbobitis IC, Falagas ME. Severe cytomegalovirus infection in apparently immunocompetent patients: a systematic review. *Virology*. 2008;5(1):47
5. Lee JH, Agarwal A, Mahendradas P, et al. Viral posterior uveitis. *Surv Ophthalmol*. 2017;62(4):404-445.
6. Janet L. Davis (1999) Differential diagnosis of CMV retinitis, *Ocular Immunology and Inflammation*, 7:3-4, 159-166
7. Pepose JS, Holland GN, Nestor MS, Cochran AJ, Foos RY. Acquired immune deficiency syndrome. Pathogenic mechanisms of ocular disease. *Ophthalmology* 1985;92(4):472-484.
8. Yanoff, m and Duker J, 2019. *Ophthalmology*. 5th edition. China: Elsevier, pp 704-705
9. Invernizzi A, Agarwal A, Ravera V, Oldani M, Staurenghi G, Viola F. OPTICAL COHERENCE TOMOGRAPHY FINDINGS IN CYTOMEGALOVIRUS RETINITIS: A Longitudinal Study. *Retina*. 2018;38(1):108-117.
10. Patil AJ, Sharma A, Kenney MC, Kuppermann BD. Valganciclovir in the treatment of cytomegalovirus retinitis in HIV-infected patients. *Clin Ophthalmol*. 2010;4:111-119.
11. Guidelines for prevention and treatment of opportunistic infections in HIV-infected adults and adolescents. *MMWR Morb Mortal Wkly Rep* 2009;58(RR-4):55.
12. Henderly DE, Freeman WR, Causey DM, et al. Cytomegalovirus retinitis and response to therapy with ganciclovir. *Ophthalmology* 1987;94(4):425-34.
13. Hodge WG, Lalonde RG, Sampalis J, Deschenes J. Once-weekly intraocular injections of ganciclovir for maintenance therapy of cytomegalovirus retinitis: clinical and ocular outcome. *J Infect Dis* 1996;174:393-6
14. Jacobson, M.A., and O'Donnell, J.J. Approaches to the treatment of cytomegalovirus retinitis: ganciclovir and fos- carnnet. *J. Acquir. Immune Defic. Syndr*. 4 Suppl 1:S11-S15, 1991.
15. Viral retinitis: diagnosis and management in the era of biologic immunosuppression: A review (Port AD, Orlin A, Kiss S, Patel S, D'Amico DJ, Gupta MP. *Cytomegalovirus Retinitis: A Review*. *J Ocul Pharmacol Ther*. 2017;33(4):224-234.)
16. Stewart MW. Optimal management of cytomegalovirus retinitis in patients with AIDS. *Clin Ophthalmol*. 2010;4:285-299. Published 2010 Apr 26. doi:10.2147/ophth.s6700
17. Roy R, Pal BP, Mathur G, Rao C, Das D, Biswas J. Acute retinal necrosis: clinical features, management and outcomes - a 10 year consecutive case series. *Ocul Immunol Inflamm*. 2014;22(3):170-174.
18. Meghpara B, Sulkowski G, Kesen MR, Tessler HH, Goldstein DA. Long- term follow-up of acute retinal necrosis. *Retina*. 2010;30(5):795-800
19. Butler NJ, Moradi A, Salek SS, et al. Acute retinal necrosis: presenting characteristics and clinical outcomes in a cohort of polymerase chain reaction-positive patients. *Am J Ophthalmol*. 2017;179:179-189
20. Young NJ, Bird AC. Bilateral acute retinal necrosis. *Br J Ophthalmol*. 1978;62(9):581-590.
21. Chawla R, Tripathy K, Sharma YR, Venkatesh P, Vohra R. Periarterial Plaques (Kyrieleis' Arteriolitis) in a Case of Bilateral Acute Retinal Necrosis. *Semin Ophthalmol*. 2017;32 :251-252.
22. Shantha JG, Weissman HM, Debiec MR, Albini TA, Yeh S. Advances in the management of acute retinal necrosis. *Int Ophthalmol Clin*. 2015 Summer;55(3):1-13
23. Cochrane TF, Silvestri G, McDowell C, Foot B, McAvoy CE. Acute retinal necrosis in the United Kingdom: results of a prospective surveillance study. *Eye (Lond)*. 2012;26(3):370-377.
24. Baltinas J, Lightman S, Tomkins-Netzer O. Comparing treatment of acute retinal necrosis with either oral valganciclovir or intravenous acyclovir. *Am J Ophthalmol*.)2018;188:173-180
25. Invernizzi A, Agarwal AK, Ravera V, et al Comparing optical coherence tomography findings in different aetiologies of infectious necrotising retinitis *British Journal of Ophthalmology* 2018;102:433-437
26. Lau CH, Missotten T, Salzmann J, Lightman SL. Acute retinal necrosis features, management, and outcomes. *Ophthalmology*. 2007;114(4):756-762.
27. Hillenkamp J, Nölle B, Bruns C, et al. Acute retinal necrosis: clinical features, early vitrectomy, and outcomes. *Ophthalmology* 2009;116(10):1971-5.e2.
28. Holland GN. Standard diagnostic criteria for the acute retinal necrosis syndrome. Executive Committee of the American Uveitis Society. *Am J Ophthalmol*. 1994;117(5):663-667.
29. National Center for Biotechnology Information. PubChem Database. Valacyclovir, CID=135398742, <https://pubchem.ncbi.nlm.nih.gov/compound/Valacyclovir> (accessed on Apr. 12, 2020)
30. Wong R, Pavesio CE, Laidlaw DAH, et al. Acute retinal necrosis: the effects of intravitreal foscarnet and virus type on outcome. *Ophthalmology* 2010;117(3):556-60.
31. Tibbetts MD, Shah CP, Young LH, Duker JS, Maguire JJ, Morley MG. Treatment of acute retinal necrosis. *Ophthalmology*. 2010;117(4):818-824.
32. Wu XN, Lightman S, Tomkins-Netzer O. Viral retinitis: diagnosis and management in the era of biologic immunosuppression: A review. *Clin Exp Ophthalmol*. 2019;47(3):381-395
33. Forster DJ, Dugel PU, Frangieh GT, Liggett PE, Rao NA. Rapidly progressive outer retinal necrosis in the acquired immunodeficiency syndrome. *Am J Ophthalmol*. 1990;110(4):341-348
34. Engstrom RE, Holland GN, Margolis TP, et al. The progressive outer retinal necrosis syndrome. *Ophthalmology*. 1994;101(9):1488-1502.
35. Jain A, Anantharaman G, Gopalakrishnan M, Narayanan S. Sequential optical coherence tomography images of early acute retinal necrosis. *Indian J Ophthalmol* 2020;68:520-2
36. Suzuki J, Goto H, Minoda H, Iwasaki T, Sakai J, Usui M. Analysis of retinal findings of acute retinal necrosis using optical coherence tomography. *Ocul Immunol Inflamm* 2006;14:165-70
37. Blair MP, Goldstein DA, Shapiro MJ. Optical coherence tomography of progressive outer retinal necrosis. *Retina* 2007;27:1313-4
38. Kostamaa HJ, Narayanan R, Kuppermann B. Optical coherence tomography in progressive outer retinal necrosis. *Invest Ophthalmol Vis Sci* 2005;46:2571
39. Spaide RF, Martin DF, Teich SA, Katz A, Toth I. Successful treatment of progressive outer retinal necrosis syndrome. *Retina*. 1996;16(6):479-487
40. Dogra M, Bajgai P, Kumar A, Sharma A. Progressive outer retinal necrosis after rituximab and cyclophosphamide therapy. *Indian J Ophthalmol* [serial online] 2018 [cited 2020 Jun 6];66:591-3. Available from: <http://www.ijo.in/text.asp?2018/66/4/591/228482>
41. Hasbun R, Garcia MN, Kellaway J, et al. West Nile Virus retinopathy and associations with long term neurological and neurocognitive sequelae. *PLoS One*. 2016;11(3):e0148898
42. G. F. Oliver, J. M. Carr, J. R. Smith. Emerging infectious uveitis: Chikungunya, dengue, Zika and Ebola: A review. *Clin Exp Ophthalmol* 47, 372-380 (2019)
43. Kazmi SS, Ali W, Bibi N, Nouroz F. A review on Zika virus outbreak, epidemiology, transmission and infection dynamics. *J Biol Res (Thessalon)*. 2020; 27:5. Published 2020 Mar 4. doi:10.1186/s40709-020-00115-4
44. Ventura CV, Maia M, Bravo-Filho V, Gois AL, Belfort R Jr. Zika virus in Brazil and macular atrophy in a child with microcephaly. *Lancet*. 2016; 387:228.

Cite This Article as: , Anamika Patel, Mudit Tyagi , Viral Retinitis: Review . Delhi J Ophthalmol 2021 ; 31 (4) : 19 - 25.

Acknowledgments: Nil

Conflict of interest: None declared

Source of Funding: None

Date of Submission: 5 Aug 2020

Date of Acceptance: 21 Sep, 2020

Address for correspondence

Mudit Tyagi, MS

Uveitis and Ocular Immunology Services,
Smt.Kanuri Santhamma Center for
Vitreoretinal Diseases L.V.Prasad Eye
Institute, Hyderabad, Telangana, INDIA
Email: drmudittyagi@gmail.com



Quick Response Code