

# Diplopia Following External Dacryocystorhinostomy with Intracystic Pawar Implant Implantation: The Tale of an Unheard Complication

Deepsekhar Das,<sup>1</sup> Mandeep Singh Bajaj,<sup>1</sup> Swechya Neupane,<sup>1</sup> Sahil Agrawal,<sup>1</sup> Saloni Gupta<sup>2</sup>

<sup>1</sup>Dr. Rajendra Prasad Centre for Ophthalmic Sciences, All India Institute of Medical Sciences, New Delhi, India.

<sup>2</sup>Northern Railway Central Hospital, New Delhi, India.

## Abstract

Dacryocystorhinostomy (DCR) with Pawar intracystic implant placement is a simple and faster surgical option for treating epiphora. Its advantages being small length of incision (5-6mm), minimal intraoperative and postoperative bleeding, and sparing of the medial palpebral ligament with no need of creating sac and nasal mucosal flaps anastomosis. The presence of holes at upper and lower end act as extra drainage channel. This makes it superior to conventional DCR with better success rate. Herein, we report a rare complication of diplopia following implantation of Pawar's implant. We believe in the following chain of events with anterior displacement of implant, local inflammation was evoked, resulting in subsequent scarring and medial rectus fibrosis.

Delhi J Ophthalmol 2021;32; 65-67; Doi <http://dx.doi.org/10.7869/djo.692>

**Keywords :** Pawar Implant, Diplopia, Dcr, Dcr-Complications

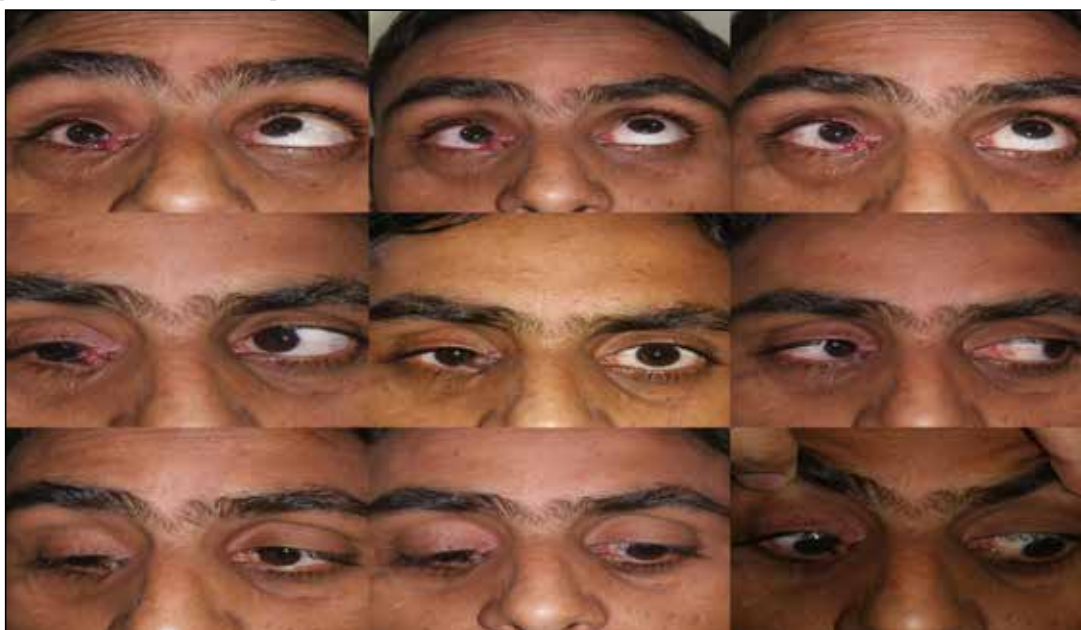## Introduction

Dacryocystorhinostomy with Pawar intracystic implant placement is a simple, fast, and effective surgical option for the management of epiphora. Its results are comparable to conventional dacryocystorhinostomy (DCR). The advantages of Pawar implant DCR over conventional DCR are small length of incision of around 5-6mm, minimal intraoperative and post-operative bleeding complication and sparing of the medial palpebral ligament. In this procedure, there is no need for creating a sac and nasal mucosal flaps anastomosis. The presence of additional four holes at the upper end near the collar and six holes at the lower end of the Pawar implant act as an extra drainage channel having 1 mm diameter. This makes it superior to conventional DCR with a better success rate.<sup>1</sup> Herein, we report a case of patient developing diplopia following implantation of Pawar's implant.

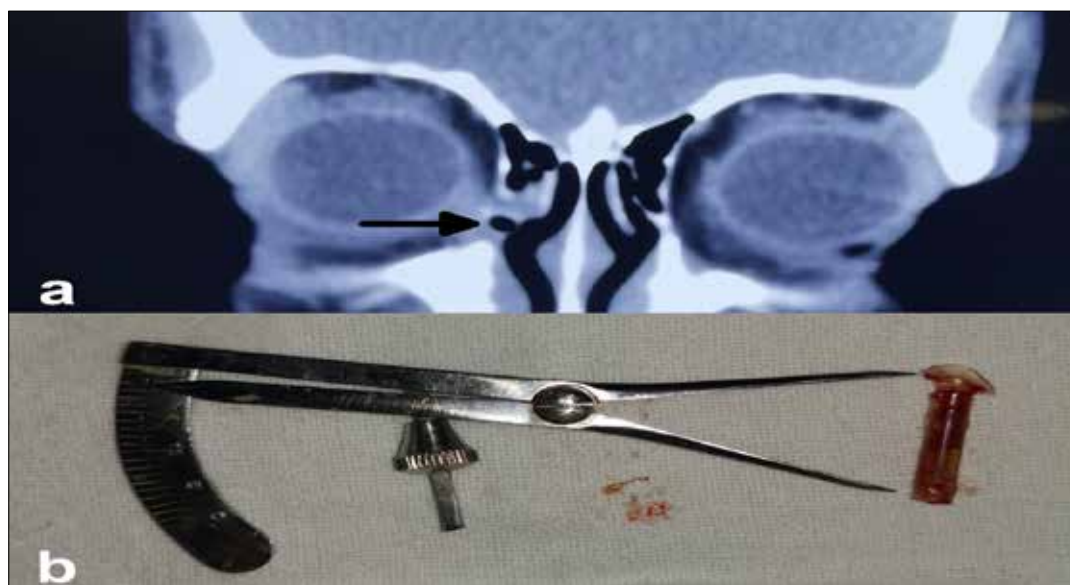
## Case History

A 38-year-old male presented with a history of diplopia and inward deviation of his right eye for the past six months. He gave a history of undergoing external dacryocystorhinostomy with Pawar implant placement 4 years back for right eye chronic dacryocystitis. Immediately after the surgery, his had reduction in epiphora, however; in the subsequent month, a swelling developed in the right medial canthal region which had subsided on the administration of topical and oral antibiotics.

On examination, his visual acuity was 6/6 in both eyes with normal intraocular pressures. On checking extraocular motility, there was marked restriction of ocular movements of the right eye in the attempted right lateral and up gaze (Figure 1).



**Figures 1:** Nine gaze image of the patient showing limitation abduction and elevation of right eye.



**Figures 2:** a) Coronal cut of a non-contrast CT Scan of the orbit showing implant in situ (marked by a black arrow).  
b) Image of the explanted Pawar implant

There was dystopia of the right medial canthus with medial conjunctival congestion along with exposure of the tube. There was a granuloma adjacent to the exposed implant with symblepharon bridging the medial bulbar conjunctiva and the lower eye. The left eye was within normal limits. A computed tomography (CT) scan of head and orbit was done which revealed the presence of a heterogeneous opacity in the right medial canthal region suggestive of a tube, along with a deficient bone in right medial canthal region which hinted a prior surgery (Figure 2a).

The patient was planned for surgery. After creating a localized conjunctival peritomy, the granuloma was excised, and the symblepharon was released. The anteriorly displaced intracystic implant was removed (Figure 2b).

A forced duction test was performed where the MR was found to be tight. On further exploration, the MR and its overlying tenon were found to be fibrosed, and the tenon was released. On repeating the force duction test medial rectus was mildly tight. A conjunctival autograft was obtained from the superior bulbar conjunctiva and placed over bare sclera around the medial canthus and sutured with an 8-0 vicryl suture. The patient was started on topical Moxifloxacin eye drops and carboxymethylcellulose drops.

### Discussion

Pawar implant is a funnel-shaped device which has a wider end designed to protrude into the nasal cavity. The first of its kind was made in 1985 from silicone pieces which were leftover from Denver's hydrocephalus shunts after a hydrocephalus surgery.<sup>2</sup> A collar was added to the implant in 1987. Furthermore, a haptic was added in 1995.<sup>3</sup>

The idea behind this invention was to allow a smooth unhindered passage of tears without being affected by lacrimal sac fibrosis or the phimosis of the bony ostium in the long run.

This implant has many advantages over conventional DCR with few complications. In a prospective study by Chandravanshi et al. published in 2019 where 30 patients underwent DCR with Pawar implant, post-operative complications like lid oedema, incisional oedema, haemorrhage from nasal mucosa, sac infection, wound gape and hypertrophic scar were more with conventional DCR. This was attributed to the minimally invasive nature of intracystic implant surgery.

However, complications like obstruction of passage and extrusion were more common with Pawar implant. In another study by Mishra et al., where he compared conventional external DCR with DCR with Pawar's implant placement, 33 patients underwent external DCR with Pawar's implant placement there was a success rate of 97% at 6months follow up.<sup>4</sup> The most common cause of failure of Pawar implant was mucus plug formation leading to obstruction of the tube, followed by sac infection, crust formation and extrusion of the implant through a skin wound.

Literature regarding the complications with the use of this device is limited. Mishra et al., in his study, documented intraoperative complications as nasal mucosal bleed, which occurred in 37%, angular vein bleed in 9% and nasal mucosal disruption in 15%. Long term complications documented in his study were granulation tissue formation in 3% and mucous plug formation in 6%. In a study by Gupta et al.<sup>5</sup> where she performed external DCR with Pawar's Implant in 40 patients, the complications she documented were bleeding per-operatively (5%), longer duration of surgery(7.5%), recurrence of symptoms(5%), pain at the incision site (2.5%) and mild ecchymosis(100%).<sup>6</sup> However, complications like medial rectus fibrosis and diplopia following implant placement have never been reported.

### Conclusion

The most likely reason for the situation would be continuous rubbing of the anteriorly displaced implant against the bulbar conjunctiva and the underlying medial rectus muscle. That would have evoked an inflammatory response leading to granulation tissue formation around the region leading to symblepharon and fibrosis of medial rectus muscle. Though the MR was tight, on follow up, diplopia was corrected in primary gaze.

### References

1. Chandravanshi SL, Shrivastava SK, Shakya DK, Tiwari US. Conventional Dacryocystorhinostomy Versus Pawar's Implant Dacryocystorhinostomy-A Prospective Study. International Journal of Innovative Research in Medical Science. 2019 Jan;4(01):5-10. <https://doi.org/10.23958/ijirms/vol04-i01/533>.
2. Pawar MD. Implant dacryocystorhinostomy using modified Pawar implant. Journal of medical science and clinical research. February 2015; 3(2): 4008-18.
3. Pawar MD, Sutaria SN. Intra-cystic tube implantation in dacryocystorhinostomy. In Proceed-ings of the Xth Congress of the Asia Pacific Academy of Ophthalmology. 1985 Jan; pp. 19091.
4. Mishra, D., Bhushan, P., Sinha, B. P., Bhaskar, G., & Rao, R. (2019). External dacryocystorhi-nostomy conventional surgery versus Pawar implant: A comparative study. Indian journal of ophthalmology; 67(7):1143–1147.[https://doi.org/10.4103/ijo.IJO\\_1889\\_18](https://doi.org/10.4103/ijo.IJO_1889_18)
5. Gupta S, Mengi RK. Outcome of Dacryocystorhinostomy With Silicone Intracystic Implant In Patients With Chronic Dacryocystitis, <http://www.jkscience.org>; Oct-December 2013; 15(4): 181-4.

**Cite This Article as:** Deepsekhar Das Mandeep Singh Bajaj, Swechya Neupane, Sahil Agrawal, Saloni Gupta. Diplopia following external dacryocystorhinostomy with intracystic Pawar implant . Delhi J Ophthalmol 2021; 32 (1), 65-67.

**Acknowledgments:** Nil

**Conflict of interest:** None declared

**Source of Funding:** None

**Date of Submission:** 19 Mar 2021

**Date of Acceptance:** 16 Apr 2021

### Address for correspondence

#### Sahil Agrawal

Oculoplasty and Orbital Tumor Services  
Dr Rajendra prasad centre for  
ophthalmic sciences, All India Institute  
of Medical Sciences New Delhi India  
Email: [agrawalsahilo3.acad@gmail.com](mailto:agrawalsahilo3.acad@gmail.com)



Quick Response Code