

Bilateral Non Arteritic Anterior Ischemic Optic Neuropathy Associated With Optic Nerve Head Drusen And Vascular Risk Factors

Eathi Tuli, Aakanksha Sharma, Gaurav Sharma, Shalu Gupta

Dr. Rajendra Prasad Government Medical College Kangra at Tanda, Himachal Pradesh, India.

Abstract

We report case history of 52 year old male who presented with sudden painless diminution of vision in right eye and with similar complaint of diminution of vision in left eye six months back. He was diagnosed as Nonarteritic Anterior Ischemic Optic Neuropathy (NAION) in left eye with Optic Nerve Head Drusen (ONHD) in both the eyes. He was otherwise well and his medical history revealed systemic hypertension. Fundus examination revealed hyperaemic disc in the right eye and temporal pallor of the disc in the left eye. On visual field examination, inferior altitudinal visual field defect in both the eyes. ONHD can mimic as disc oedema and it can very rarely cause NAION. In addition, multiple vascular risk factors can also cause NAION, hence detailed investigations and periodic follow up should be done to rule out ischemic disc complication.

Delhi J Ophthalmol 2021;32;71-73; Doi <http://dx.doi.org/10.7869/djo.694>

Keywords: Nonarteritic Anterior Ischemic Optic Neuropathy, Optic Nerve Head Drusen, Inferior Altitudinal Defect.

Introduction

Nonarteritic Anterior Ischemic Optic Neuropathy (NAION) is the most common acquired primary optic neuropathy caused by infarction of the short posterior ciliary arteries that supply the anterior portion of the optic nerve head. NAION typically presents with acute unilateral painless loss of vision. Primary risk factor for NAION is small crowded optic disc. Additional risk factors associated with NAION are diabetes mellitus, hypertension, hyperlipidaemia, atherosclerosis, obesity.¹ ONHD can also cause NAION due to crowding and compression of axons. Here in, we report a male patient who had ONHD and associated vascular risk factors who developed NAION.

Case Report

52 year old male presented to eye outpatient department with sudden diminution of vision (DOV) in the right eye since 2 days, which was painless and progressive in nature, he noticed sudden DOV while waking up in the morning. There was no history of ocular pain, redness, photophobia, fever or trauma.

He had similar episode of sudden DOV in the left eye 6 months back and was diagnosed as NAION in the left eye associated with ONHD in both the eyes at our institute. He was started on oral corticosteroids after which patient noticed mild improvement in his vision. His family history was unremarkable and medical history revealed systemic hypertension since 6 months. Patient was on antihypertensive drugs, amlodipine, telmisartan and was non-compliant with the treatment. He did not have any habits such as smoking or drinking alcohol and had no history of recent infections or toxic exposure. On examination, he was conscious and oriented. His blood pressure was 132/88 mm Hg, with a regular pulse of 72 beats/min.

On ophthalmological examination, ocular adnexa, gaze motility were normal. Pupils were sluggish, with left relative afferent pupillary defect. Visual acuity was 6/60 and 6/36 in right and left eye respectively. Slit lamp examination

was unremarkable in both the eyes. Intraocular pressure by applanation tonometer was 18 mmHg and 16 mm Hg in right and left eye. Dilated fundus examination showed disc oedema with blurring of the disc margin and tortuous blood vessels in the right eye and temporal pallor of the optic disc in the left eye (Figure 1).

Visual field analysis by computerized automatic perimetry showed an inferior altitudinal defect in both the eyes (Figure 2). Optical coherence tomography showed lumpy bumpy internal contour appearance at the optic disc suggestive of ONHD (Figure 3). B scan showed ovoid echogenic lesion at the junction of retina and optic nerve head suggestive of ONHD (Figure 4). MRI Brain was within normal limits.

Laboratory parameters including complete haemogram, lipid profile, ESR, CRP, ACE levels, peripheral eosinophil count, coagulation parameters all within normal ranges.

Patient was started on oral steroids, tablet prednisolone 70 mg on tapering dose and was advised to continue antihypertensive with regular monitoring of BP and blood sugar levels and was counselled to maintain healthy diet.

Discussion

NAION presents with acute unilateral painless loss of vision accompanied by sector or diffuse optic nerve head oedema.² Generally affects people over 50 years of age, exact pathogenesis of NAION is unproven, it is a multifactorial disease and presumed due to transient disruption in the circulation of the optic nerve head leading to hypo perfusion and ischemia.³

Optic disc drusen are calcified deposits located in the optic nerve head anterior to the lamina cribrosa. Incidence in the general population varies from 0.4–2.4%.⁴ Involvement is bilateral in 75–86% of cases and is asymmetric.⁵ Most cases are asymptomatic and diagnosis is established during routine eye examination as an incidental fundus finding. Visual

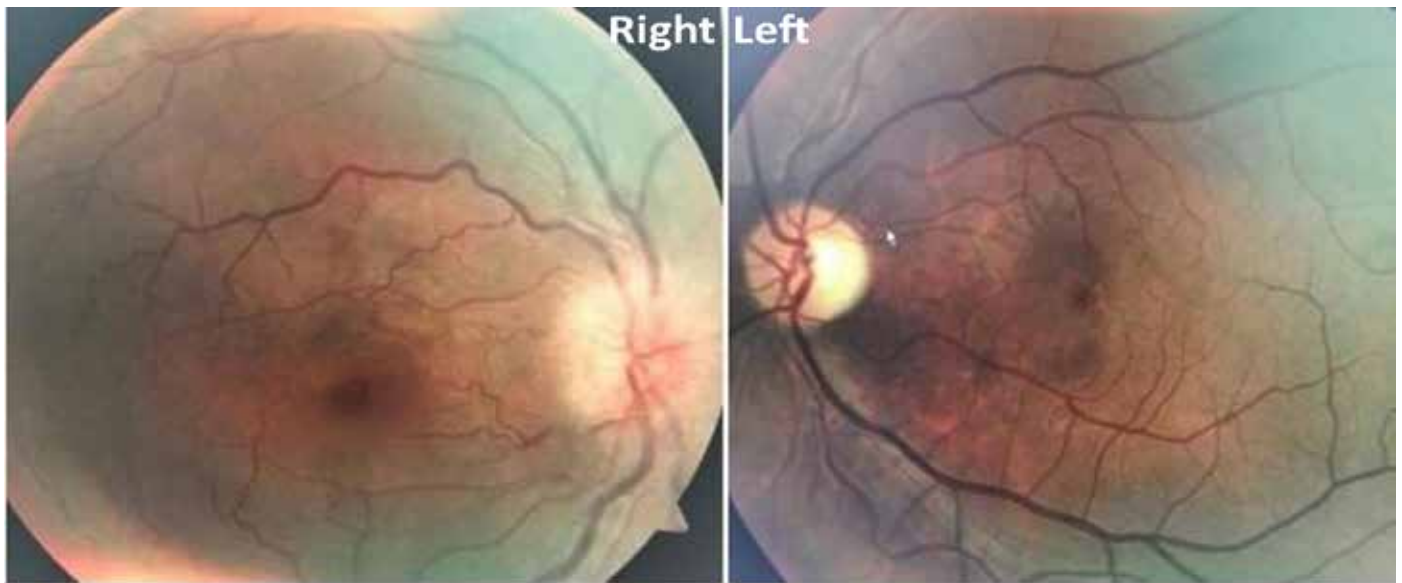


Figure 1 : Dilated fundus examination showed disc oedema with blurring of the disc margin and tortuous blood vessels in the right eye and temporal pallor of the optic disc in the left eye




Figure 2 : Visual field analysis by computerized automatic perimetry showed an inferior altitudinal defect in both the eyes

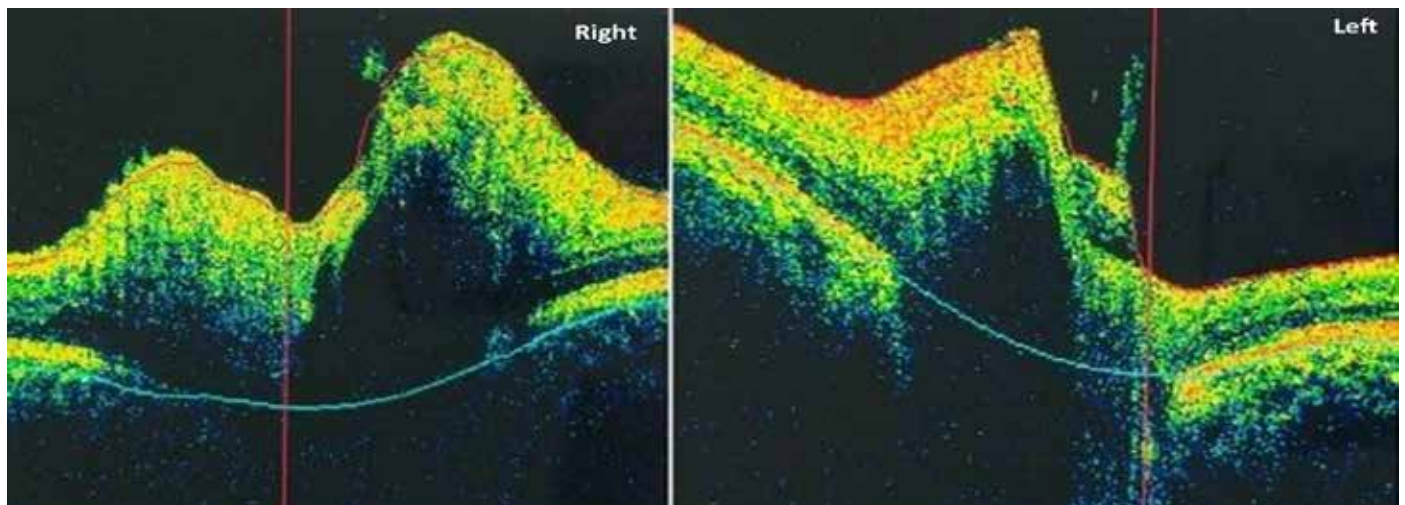


Figure 3 : Optical coherence tomography showed lumpy bumpy internal contour appearance at the optic disc suggestive of ONHD

obscuration in patients with ONHD is due to increased optic disc tissue pressure causing impairment of disc circulation.⁶

Mullie⁷ reported small scleral canal with vascular anomalies in optic disc of patients with ONHD indicating a mesodermal dysgenesis of the optic nerve head. Gittinger et al⁸ reported mechanical distortion of blood vessels located in the lamellar and prelaminar region in cases of ONHD predispose them to develop NAION. Tan et al reported presence of ONHD as an independent risk factor for NAION.

NAION is associated with many conditions that predispose to decreased optic nerve head perfusion via micro vascular occlusion such as systemic hypertension, diabetes mellitus and hyperlipidaemia. Nocturnal systemic hypotension has a significant role in the development of NAION, particularly in patients with an exaggerated nocturnal dip.⁹

Hayreh reported nocturnal hypotension as one of the aetiology for NAION. Purvin¹⁰ found 50% NAION patients to have systemic vascular risk factors, but each patient had only one at the time of presentation. Ischemic optic neuropathy decompression trial (IONDT) found 60% to have vascular risk factors associated with NAION.¹¹

In our case report ONHD was documented by using recent techniques such as OCT and B scan. Our patient was known hypertensive and was non compliant to the treatment, presented with sudden painless diminution of vision upon awakening suggesting nocturnal hypotension could have caused NAION. Our medical treatment consisted of systemic steroids. Firm evidence is lacking about the corticosteroid efficacy on visual function. Mild improvement noted in our patient could be due to the natural course of the disease other than the treatment effect.

Conclusion

ONHD rarely can cause NAION, clinicians should be aware of this association. Patients with NAION and concomitant ONHD can have multiple systemic vascular risk factors and hence detailed investigation should be performed. Patients with ONHD should be followed up periodically for possibility of ischemic disc complications.

References

- Hayreh SS, Zimmerman MB. Nonarteritic anterior ischemic optic neuropathy: natural history of visual outcome. *Ophthalmology*. 2008; 115(2):298–305
- Berry S, Lin WV, Sadaka A, Lee A. Nonarteritic anterior ischemic optic neuropathy: cause, effect, and management. *Eye Brain*. 2017; 9: 23–28.
- Miller NR, Arnold AC. Current concepts in the diagnosis, pathogenesis and management of nonarteritic anterior ischaemic optic neuropathy. *Eye (Lond)* 2015; 29(1):65–79.
- Perez-Alvarez F, Luque A, Penas A. Bilateral disc drusen as an important differential diagnosis of pseudotumor cerebri. *Brain Dev*. 2007; 29(6):387–388.
- Hu K, Davis A, O'Sullivan E. Distinguishing optic disc drusen from papilloedema. *Br. Med. J*. 2008; 337:a2360.
- Tan DK, Tow SL. Acute visual loss in a patient with optic disc drusen. *Clin Ophthalmol*. 2013; 7:795-99.

- Mullie MA and Sanders M.D. Scleral canal size and optic Nerve head drusen. *Am J Ophthalmol*. 1985; 99(3):356–59
- Gittinger JW, Lessell S, Bondar RL. Ischemic optic neuropathy associated with optic disc drusen. *J Clin Neuroophthalmol*, 1984; 4(2):79-84.
- Hayreh SS, Podhajsky P, Zimmerman MB. Role of nocturnal arterial hypotension in optic nerve head ischemic disorders. *Ophthalmologica*. 1999; 213:76–96.
- Purvin V, King R, Kawasaki A, Yee R. Anterior ischemic optic Neuropathy in eyes with optic disc drusen. *Arch Ophthalmol*. 2004; 122:48–53
- Newman NJ, Scherer R, Langenberg P. The fellow eye in NAION: report from the ischemic optic neuropathy decompression trial follow-up study. *Am J Ophthalmol*. 2002; 134(3):317–328

Cite This Article as: Eathi Tuli, Aakanksha Sharma, Gaurav Sharma, Shalu Gupta Bilateral Non Arteritic Anterior Ischemic Optic Neuropathy Associated With Optic Nerve Head Drusen And Vascular Risk Factors Delhi J Ophthalmology 2021; 32 (1) 71-73.

Acknowledgments: Nil

Conflict of interest: None declared

Source of Funding: None

Date of Submission: 21 Dec 2018

Date of Acceptance: 5 April 2020

Address for correspondence

Eathi Tuli DOMS,DNB,
Senior Resident Ophthalmology
Department of ophthalmology,
DR RPGMC TANDA, KANGRA
HIMACHAL PRADESH, India
Email id:ethi.shree@gmail.com



Quick Response Code